

VI. *On the Structure, Development and Morphological Interpretation of the Pineal Organs and Adjacent Parts of the Brain in the Tuatara (Sphenodon punctatus).*

By ARTHUR DENDY, *D.Sc., F.R.S., Sec. L.S., Professor of Zoology in King's College (University of London).*

(Received June 22,—Read June 30, 1910.)

[PLATES 19–31.]

CONTENTS.

| | PAGE |
|---|------|
| I.—Introductory Remarks | 228 |
| II.—Material and Methods | 230 |
| III.—Relation of the Brain and its Membranes to the Cranial Cavity | 236 |
| IV.—General Morphology of the Thalamencephalon and adjacent parts of the Brain | 237 |
| A. Condition at Stage O | 237 |
| B. Condition at later Embryonic Stages | 238 |
| C. The Lateral Choroid Plexuses (<i>Plexus Hemisphaerium</i>) and their relations to the Paraphysis, etc. | 239 |
| D. The alleged <i>Commissura mollis</i> | 243 |
| E. Lateral Diverticula of the Third Ventricle and Iter | 245 |
| F. Neuromery of the Fore- and Mid-Brain | 248 |
| V.—The Pineal Complex | 249 |
| A. The Dorsal Sac | 251 |
| B. The Paraphysis | 253 |
| C. The Pineal Sac | 256 |
| D. The Pineal Eye | 264 |
| <i>a.</i> Personal Observations | 264 |
| (1) Position and Relations | 264 |
| (2) Shape and Size | 265 |
| (3) General Structure and Development | 265 |
| (4) The Retina | 266 |
| (α) General Structure and Development | 266 |
| (β) The Radial Fibres | 267 |
| (γ) The Sense-Cells | 267 |
| (δ) The Ganglion-Cells and Nerve-Fibres | 269 |
| (ϵ) The Pigment and its Origin | 270 |
| (ζ) Accessory Cavities in the Retina | 274 |
| (5) The Lens | 275 |
| (6) The Vitreous Body | 279 |
| <i>b.</i> Comparison with the Descriptions of the Pineal Eye of <i>Sphenodon</i> given by other Observers | 281 |
| <i>c.</i> Comparison with the Pineal Eye of other Reptiles | 283 |
| <i>d.</i> Comparison with the Pineal Eye of the Lamprey | 285 |
| <i>e.</i> The Functional Capacity of the Pineal Eye | 286 |

(B. 279.)

2 G 2

23.12.10.

| | PAGE |
|---|------|
| E. The Pineal Nerves | 288 |
| (1) The Left Pineal Nerve (Nerve of the Pineal Eye) in the Adult | 289 |
| (2) The Right Pineal Nerve (<i>Tractus pinealis</i>) in the Adult | 294 |
| (3) The Development of the Pineal Nerves | 296 |
| <i>a.</i> Development of the Left Pineal Nerve | 297 |
| <i>b.</i> Development of the Right Pineal Nerve | 299 |
| F. The Central Connections of the Pineal Nerves | 300 |
| VI.—The Blood Vessels of the Pineal Complex | 301 |
| Arterial System | 302 |
| Venous System | 305 |
| VII.—The Parietal Plug and Overlying Integument | 306 |
| VIII.—The Morphological Interpretation of the Pineal Organs | 308 |
| A. The Bilateral Theory of the Pineal Organs | 308 |
| <i>a.</i> Evidence derived from the Study of <i>Sphenodon</i> | 309 |
| <i>b.</i> Evidence derived from the Study of other Types | 310 |
| <i>α.</i> Cyclostomes | 310 |
| <i>β.</i> Other Vertebrates | 311 |
| B. The Theory of the Serial Homology of the Pineal Organs with the Lateral Eyes | 312 |
| C. The Comparison of the Pineal Eye with the Median Eyes of Arthropods | 314 |
| IX.—The Sub-Commissural Organ and Reissner's Fibre | 314 |
| X.—Reference List of Literature | 317 |
| XI.—Description of Plates | 320 |
| XII.—Explanation of Lettering on Plates and Text-figures | 327 |
| XIII.—Postscript | 329 |

I.—INTRODUCTORY REMARKS.

BEFORE leaving New Zealand in 1901, in order to return to England after an absence of fourteen years in Australasia, I took special care to preserve material for the investigation, by modern methods, of the minute histological structure of the pineal eye of the native Lamprey (*Geotria australis*) and of the Tuatara (*Sphenodon punctatus*). Three years ago I published the results of my investigations on *Geotria* (DENDY, 1907, *a*), for which the material I had obtained proved amply sufficient. In the case of *Sphenodon*, however, I had been able to preserve the brain and pineal eye of only a single adult specimen. The pineal eye was detached from the brain and preserved separately, together with the surrounding portion of the cranial roof. This I kept in my own possession, but the brain was given to Prof. HOWES for transmission to Prof. ELLIOT SMITH.

My investigations have been greatly delayed by various unavoidable circumstances, and especially by the pressure of other engagements. My professional duties called me to South Africa in 1903, and it was not until I had fairly settled down in the newly created chair of Zoology at Cape Town, and had imported from England the necessary apparatus, that I found an opportunity of preparing sections of my *Sphenodon* material. These sections were not fully examined until after my return to England once more in 1905.

Four years ago, at the York meeting of the British Association (DENDY, 1906), I pointed out certain remarkable features exhibited by these sections, especially the presence of a large "central cell" in the lens, of unknown significance, and a few further particulars were given in a short paper on the "Pineal Gland" published in 'Science Progress' (DENDY, 1907, *b*).

The results so far obtained appeared to me of sufficient importance to justify further investigation, but progress was for a long time stopped by the want of material. In May, 1906, the Government Grant Committee of the Royal Society had placed at my disposal the sum of £25, but it was many months before I was able to obtain the specimens which I required. Thanks, however, to the kind and cordial co-operation of my friends, the Hon. W. PEMBER REEVES, then High Commissioner for New Zealand in London, and Prof. H. B. KIRK, of Wellington, New Zealand, I was ultimately successful, and on December 9, 1907, I had the satisfaction of receiving from the butcher on board the ss. "Ruapehu," at the London Docks, six large male tuataras in fine condition. After their arrival in London the animals were kept alive without any difficulty. These specimens were obtained from Stephens Island in Cook Straits, and presented to me by the New Zealand Government, so that I had only to pay the cost of their transport from Wellington to London. I desire to express my sincere gratitude to the New Zealand Government for their generosity, which, however, would have been of little avail but for the immense amount of trouble which Prof. KIRK took to bring all the necessary arrangements in New Zealand to a satisfactory conclusion.

The tuataras are very sluggish creatures, but exhibit a good deal more activity at night than in the daytime. There was no difficulty in inducing them to feed on earthworms, and on one occasion one of them caught a mouse which was put into the cage. In New Zealand I have seen one catch a young bird by a lightning-like snap of the powerful jaws. In order to keep them in a state of health they should be supplied with a tank of clean water sufficiently large for them to lie in, which they are very fond of doing, and with a few large pieces of rock to scramble amongst and protection from cold weather they appear to be perfectly happy.

The next delay was caused by illness, and it was not until March 5, 1908, that the first specimen was killed. The remainder, with the exception of one, which died a natural death, were killed at intervals as required, the last being sacrificed on December 18, 1908.

As the work progressed it became obvious that it was necessary to extend the original limits of the investigation. It was desirable to be able to describe the blood supply of the pineal organs, and in order to do this it was necessary to make a detailed investigation of the intra-cranial vascular system, of which practically nothing was known. The results of this investigation have already been published in a separate memoir by the Royal Society (DENDY, 1909, *a*). This side issue necessarily took up a large amount of time, and still further delayed the completion of the work.

In the meantime a memoir has been published by GISI (1907) on the brain of *Sphenodon*, but this paper, though anticipating my results in some particulars, does not add very much to our knowledge of the pineal organs, and contains a number of inaccuracies which it is very desirable to correct.

The present memoir may be regarded to some extent as a continuation of the work on the development of *Sphenodon* which I commenced in New Zealand, especially in relation to the development of the pineal organs (DENDY, 1899, *a, b*). This work was undertaken under somewhat unfavourable circumstances, and the results obtained were far from being complete. I am therefore very glad of the opportunity of extending it on this occasion. I am enabled to do this owing to the fortunate circumstance that a large part of the material which I sent over to my friend the late Prof. G. B. HOWES, F.R.S., chiefly for the investigation of the development of the skeleton and for distribution to other workers, has once more come into my possession. I owe to the kindness of Mrs. HOWES the complete series of sections which were prepared for the work on the development of the skeleton (HOWES and SWINNERTON, 1901), and which have been of great use to me in the present investigation. I have also made use of a number of previously uncut embryos, most of which I had obtained and preserved after my own work on the development of the pineal organs was completed. From these, with the aid of my skilful assistant, Mr. CHARLES BIDDOLPH, I have prepared fresh series of sections, and in this way have been able to fill up important gaps in our knowledge. These embryos seem to be little the worse for the ten years during which they have lain in alcohol, and, with more modern methods of staining, have yielded better results than those which I previously investigated. It is fortunate that I still have my original sections for purposes of comparison, for they were, with most of my Australasian collections, shipwrecked in transmission from New Zealand to South Africa. The boxes containing the sections were, however, salvaged, and reached me after being soaked for weeks in salt water.

Although much has been written in late years on the subject, no complete and comprehensive account has yet been given of the pineal organs, their relations to other parts of the brain, their histology, innervation and blood supply, in any type, and it seems worth while to endeavour to make good this deficiency in our knowledge, especially in the case of such an interesting type as *Sphenodon*. Owing to the rapid rate at which this animal is being exterminated, first by pigs and now, as I understand from Prof. KIRK, by cats, such an investigation may be almost impossible in the near future.

II.—MATERIAL AND METHODS.

The chief difficulty in this investigation arises from the extreme hardness and density of the frontal and parietal bones. The pineal eye is lodged in the parietal foramen and connected with the brain only by a very slender nerve. It is hardly

possible to remove it from the foramen without detaching it also from the brain, and in order to obtain sections showing all the organs *in situ* it is necessary to adopt some method of decalcification.

As regards the histological structure of the pineal eye itself, however, that can best be investigated by cutting it separately, but I did not discover until most of my material had been prepared that it was possible to remove the eye, with the parietal plug, from the parietal foramen without injury, and thus to avoid the necessity for decalcification altogether. Similarly, I did not discover until towards the end of my work the method of hardening the brain and its appendages *in situ* by the injection of acetic bichromate of potash into the sub-dural cavity, which proved so valuable both for the investigation of the blood-vessels (DENDY, 1909), and of the brain and pineal organs. I regard this, or some similar method, as absolutely essential for successful work, for the pineal complex is likely to be injured by any process of decalcification, while if the brain is removed from the cranial cavity without being very carefully hardened previously, the greater part of the pineal complex, comprising the dorsal sac, the right pineal organ and the paraphysis, will probably collapse into a shapeless mass in which it is impossible to make out the true relations of the constituent parts. Decalcification must, however, be resorted to if it is desired to avoid separating the pineal eye from the brain before section cutting.

In spite of great care and consideration, I have not been able to find any really satisfactory method of decalcification, the parietal and frontal bones acquiring a hard and horny consistency, instead of being properly softened.* In this way some of my material has been much injured owing to the impossibility of cutting the sections thin enough, and at the same time preventing them from breaking up. Where I have been able to avoid decalcification, however, some very good series of sections have been obtained, and on the whole I think the results arrived at may be regarded as satisfactory.

The following is a list of the adult material which I had at my disposal, showing the methods by which it was treated, and the nature of the results from the point of view of technique.

Sphenodon A.—A part of the cranial roof, with the pineal eye included, was removed and fixed in Flemming's solution. This was done in New Zealand. The specimen was decalcified, and cut after staining in bulk in Ehrlich's hæmatoxylin. The sections are longitudinal and vertical, and the histological results are very good (*vide* fig. 12). The sections, are, however, rather thick. It is so long since I cut them that I am no longer certain why they were not cut thinner, but I have very little doubt that it was because the decalcified bone was too hard.

Numbers I-VI are the animals which were sent from New Zealand by the ss. "Ruapehu."

Sphenodon I.—Killed (with chloroform) March 5, 1908. The skin from the top of the head, showing the translucent patch over the pineal eye, was removed and preserved in absolute alcohol.

* It is interesting to note that LEYDIG (1891) experienced precisely the same difficulty in decalcifying the cranial roof of *Sphenodon*, and found it necessary to remove the pineal eye from the parietal foramen before cutting it into sections.

The roof of the cranium, with the pineal eye, was removed and placed in Zenker's fluid (Bolles Lee's formula) for about four hours, washed in running water for an hour, and graded up through 30 per cent., 50 per cent., to 70 per cent. alcohol,* to which a little iodine had been added to remove the corrosive sublimate, the iodine being afterwards washed out in 70 per cent. alcohol. Decalcification was attempted with nitric acid in alcohol. For 10 days the specimen was left in a mixture of 95 parts of 90 per cent. alcohol and 5 parts of pure nitric acid, most of the cranial roof being cut away to reduce the amount of bone as much as possible. A stronger mixture, containing 10 parts of nitric acid to 90 parts of 90 per cent. alcohol, was then employed for four days. It was then rinsed in pure 90 per cent. alcohol and washed for about a day in 70 per cent. alcohol, containing precipitated chalk, to remove the acid. It was then passed through 50 per cent. and 30 per cent. alcohol to Ehrlich's hæmatoxylin, in which it was left for 18 hours; then rinsed in 30 per cent. alcohol, washed in running tap-water for a quarter of an hour, and graded up through 30 per cent., 50 per cent., 70 per cent., and 90 per cent. to absolute alcohol. After all this trouble it proved still too hard for cutting thin sections. In the watery fluids it had swelled up and become fairly soft, but in absolute alcohol the bone became hard and horny. It was therefore transferred back to 70 per cent. alcohol to soften it a little, and the piece containing the eye was cut out with a razor in such a way that it would be possible to prepare longitudinal vertical sections of the parietal plug and eye without cutting through bone at all. It was then dehydrated, cleared in cedar-wood oil, and imbedded in paraffin wax of 48° M.P. after two hours in the imbedding bath at a temperature of 52°. There was no further trouble. Serial sections were cut, 7 μ thick. Some were mounted without further staining; some graded down to 30 per cent. alcohol and counterstained with a 0.5 per-cent. solution of acid fuchsin in distilled water; some taken down to 70 per cent. alcohol and counterstained with picro-indigo-carmin; some counterstained with a saturated solution of eosin in absolute alcohol. Excellent histological results were obtained (see figs. 2, 4, 11, 13-21), and I can especially recommend the eosin and picro-indigo-carmin methods.

The brain of this specimen, after being completely exposed from above, was, with the remainder of the brain-case still surrounding it, fixed and hardened in Zenker's fluid, followed by graduated alcohols in exactly the same way as the pineal eye. It was then removed from the brain-case, stained with Ehrlich's hæmatoxylin in bulk, imbedded and cut into a series of transverse sections. Some good histological results were obtained and Reissner's fibre was very well shown, but the pineal complex was in a hopeless condition, having settled down into a shapeless mass on the top of the thalamencephalon when the roof of the cranium was removed.

Sphenodon II.—Killed (with chloroform) May 4, 1908. Head severed from body, and brain-case, with brain enclosed, dissected out as far as possible. Placed in strong Flemming's solution and air removed *in vacuo*. After about a day the specimen was washed, and reduced in size, as far as possible, by further dissection. Holes were cut in the membranous walls of the cranium at the sides of the cerebral hemispheres to admit free circulation of liquids, and it was replaced in strong Flemming's solution. After another day it was washed in running water over night and transferred to the decalcifying fluid. This time I used hydrochloric acid in a solution of phloroglucin, with a little sodium chloride. In accordance with the formula given in BOLLES LEE'S book ("The Microtometist's Vade Mecum"), I made the acid very strong (300 parts saturated solution of phloroglucin in water, 90 parts pure hydrochloric acid, and 1.5 parts sodium chloride). In this mixture the specimen was left for four days, changing frequently. After prolonged washing in running water the right side of the brain was exposed by dissecting off the wall of the cranium and part of the *dura mater*, and the specimen was stained in bulk with Ehrlich's hæmatoxylin, graduated up to absolute alcohol, cleared in cedar oil and imbedded. It was cut into longitudinal vertical sections 20 μ thick. It did not cut well owing to the hardness of the roof of the cranium, and the staining was too intense, but, nevertheless, it yielded some very valuable results,

* Pure ethyl alcohol was used throughout the work whenever histological investigation was required.

showing the pineal eye and other constituents of the pineal complex *in situ* (*vide* figs. 8–10). I cannot, however, recommend the method for histological purposes.

Sphenodon III.—An attempt was made, in the case of this specimen, to determine whether the action of light had any effect upon the arrangement of the pigment-granules in the retina of the pineal eye. The animal was therefore kept in the dark for about 23 hours before being chloroformed. It was then chloroformed (July 9, 1908) while still in the dark, and not removed from the dark box until 40 minutes after the application of the chloroform. Black wax was then placed over the pineal region and the head also wrapped in a cloth at first; but it was found that the wax fell off, and that it was impossible to keep the pineal region covered during the lengthy process of dissection (about 1½ hours), which was, however, carried on in rather dull light. The results obtained, from this point of view, were negative.

The cranium was dissected out from the head after ligaturing the vessels of the neck and severing the head from the body. Holes were cut in the membranous portions of the cranial wall, and the cranium and its contents were then placed in strong Flemming's solution and air removed *in vacuo*. It was kept in this solution (once changed) in the dark for about two days: then washed in running water for about an hour, and further reduced in size by removal of a large portion of the cranial wall; then placed in aceto-bichromate of potash solution (Lee's formula) for nearly two days, washed in running water for 2½ hours and graded up to 70 per cent. alcohol. After about 1½ days in 70 per cent. alcohol, it was transferred to decalcifying fluid (90 per cent. alcohol with 10 per cent. of nitric acid added), in which it was left for two days; then washed in alcohol with precipitated chalk to remove acid, and graded down to 30 per cent. alcohol. In order to facilitate section-cutting an attempt was made to dissect away as much of the cranium as possible, while leaving the brain and pineal organs intact. The pineal eye was, however, accidentally separated from the brain in the process, and it being then impossible to carry out the original programme it was decided to cut the pineal eye, on the one hand, and the brain and remainder of the pineal organs on the other, separately. The brain, with its membranes and blood-vessels, was therefore removed from the cranium, stained in bulk with Ehrlich's hæmatoxylin and cut into transverse sections by the usual paraffin method. The staining in bulk proved very unsatisfactory in this case. The hæmatoxylin did not penetrate to the middle, while the superficial portions were much too dark. The sections were counterstained on the slide with alcoholic eosin. They yielded some valuable results with regard to the topographical relations of the blood-vessels, the left pineal nerve, the right pineal organ, the dorsal sac and paraphysis, which had been hardened *in situ* (*vide* Dendy, 1909, text-figs. 1 to 3). Though not satisfactory in itself, the method adopted in this case may probably be regarded as having led up to the very much more satisfactory treatment adopted in the case of *Sphenodon V*; for it clearly demonstrated the possibility of hardening the contents of the cranial cavity in such a manner that they could be removed *in toto* for section-cutting without losing their proper topographical relations, so that it would be possible to avoid the troublesome and injurious process of decalcification.

The portion of the cranial roof containing the pineal eye was also stained in Ehrlich's hæmatoxylin and cut by the paraffin method. Although most of the bone had been stripped off, the sections were much damaged in cutting by the hardness of the cranial roof.

Sphenodon IV.—Died in captivity, and was not used for the purposes of this investigation.

Sphenodon V.—Killed with chloroform September 23, 1908. The skin was removed from the top of the head, the eyeballs removed from the orbits, and incisions made in the unossified portions of the cranial wall at the posterior angles of the orbits. Through these incisions acetic bichromate of potash* was injected into the subdural space by means of a small glass pipette, as already described in my memoir on the Intracranial Vascular System (DENDY, 1909). The entire animal, with the exception of the tail, which had been removed for the special investigation of Reissner's fibre, was then, after opening the abdominal and thoracic cavities, suspended in a large volume of the acetic bichromate mixture without further dissection.

* BOLLES LEE, 'Microtomist's Vade Mecum,' p. 50.

In this mixture it was left for five days, then washed for 2½ hours in running water, and graded up to 70 per cent. alcohol (through 15, 30, and 50 per cent.). The head was dissected in 70 per cent. alcohol, so as to expose the right side of the brain, with its membranes and blood-vessels, which were found to be in a wonderfully perfect condition (*vide* fig. 1). After these had been sketched *in situ*, the brain, with its membranes and blood-vessels, was removed from the cranial cavity, leaving the pineal eye in the parietal foramen.

The brain, etc., were kept in 70 per cent. alcohol until November 12, during which time the blood-vessels were carefully studied and drawn. It was then stained with borax carmine in bulk and differentiated as usual with acid alcohol, dehydrated, very carefully cleared in cedar oil, and embedded in paraffin wax (M.P. 48°). Serial sections were cut parallel to the sagittal plane, again differentiated on the slide with acid alcohol, and counterstained with picro-indigo-carmine.* The sections were, for the most part, 15 μ thick. Very satisfactory results were obtained, both topographical and histological (*vide* figs. 58-74, 77, 78), and I strongly recommend this method for the study of brain-tissues in general. Epithelial structures, fibre-tracts and nerve-cells are beautifully differentiated, and it is especially good for the axis cylinders of medullated nerve-fibres and for the Nissl granules in the nerve-cells. The sections must be very carefully watched while staining with the picro-indigo-carmine, for the tints yielded by this stain vary very greatly according to time of action, washing out, etc. Another point which requires careful attention is the complete removal of the acetic bichromate mixture, used in fixing and hardening, before staining; but considering the high degree of differentiation obtained, it is a remarkably simple method, and one which can be very easily carried out. We now use it largely for ordinary laboratory purposes at King's College.

In this case, in order to avoid the grave risks attendant upon the process of decalcification, I tried the experiment of altogether removing the pineal eye, enclosed in the parietal plug, from the parietal foramen, after it had been fixed and hardened in the manner described above. I found it was quite easy with a sharp scalpel to dissect the parietal plug clean out of the foramen, without injuring the eye in the least (fig. 6). It was then dehydrated, cleared in cedar oil, and embedded in paraffin wax (M.P. 48°) as usual. Sections were cut 7 μ thick and parallel to the sagittal plane. These yielded very beautiful results (*vide* figs. 3, 5). They were all stained on the slide, some with Ehrlich's acid hæmatoxylin alone, some with Ehrlich's acid hæmatoxylin followed by eosin, some with borax carmine followed by picro-indigo-carmine, and some with iron hæmatoxylin followed by picro-indigo-carmine. The histological preservation is very good, but I do not think quite as good as that obtained by the use of Flemming's solution in the case of *Sphenodon* A.

Sphenodon VI.—Killed with chloroform December 18, 1908. Treatment as in the case of *Sphenodon* V up to 70 per cent. alcohol. The specimen was then given to my pupil, Miss A. W. HILL, B.Sc., for the purpose of studying the extra-cranial blood-vessels of the head, before I attempted to deal with it myself. In the following July I began my own investigations. This being my last specimen, I decided that the most important use to which I could put it would be the tracing of the course of the left pineal nerve from the pineal eye to the brain, about which I had hitherto experienced great difficulty. I therefore decided to attempt once more to prepare a series of sections of the cranium and its contents *in situ*, so that the pineal eye should remain in connection with the brain. The cranium and its contents were therefore removed from the head entire, and in order to minimise the difficulty of decalcification the frontal and parietal bones were stripped off from the underlying membranous and cartilaginous cranium, leaving the parietal plug standing up in the middle of the cranial roof. This plan was suggested to me by Miss HILL,

* This most valuable stain is made up as follows:—

- A. Saturated solution of picric acid in 90 per cent. alcohol.
- B. Saturated solution of indigo-carmine in 70 per cent. alcohol.

Take one volume of A and two of B and dilute with six volumes of 70 per cent. alcohol.

who had already, in the course of her dissection, found it possible to remove most of the superficial bones of the skull in this manner. The remaining portion of the cranium was decalcified in 90 per cent. alcohol containing 5 per cent. of nitric acid, in which it was left for a week. After washing as usual the specimen was stained in bulk with borax carmine, dehydrated, cleared in cedar oil, imbedded in paraffin wax, and cut into transverse sections. A very good series was obtained from the anterior end till well past the pineal region, but it was not possible to cut any further, owing to the hardness of the cranial wall. The sections had to be re-stained on the slide with borax carmine as well as with picro-indigo-carmine. They were very satisfactory as regards the pineal organs, and yielded very valuable results as to the course of the pineal nerves, blood-vessels, etc. (*vide* figs. 7, 47-57, and text-figs. 13-18).

The embryonic material used in this investigation was all originally obtained by myself in a living condition in New Zealand, having been collected for me by Mr. P. HENAGHAN, the lighthouse keeper on Stephens Island (*vide* DENDY, 1899, *a*). It may be divided into three categories :—

(1) The series of sections upon which my earlier work on the development of *Sphenodon* (DENDY, 1899, *a*, *b*) was based. These were all stained in bulk with borax carmine, and no other stain was employed.

(2) The series of sections prepared by Prof. HOWES and Dr. SWINNERTON for their work on the development of the skeleton. These were stained with Ehrlich's hæmatoxylin, followed by orange G, which had the effect of differentiating the developing pineal nerve with great clearness. The most useful of these series for my purposes were those cut from embryos 39*a* (Stage P, transverse), 52*a* (Stage Q, longitudinal vertical), 142 (Stage R, longitudinal vertical), 159 (Stage R, transverse), 162 (Stage R, transverse), II* (Stage S, longitudinal vertical).

(3) A number of entire embryos in alcohol. From these the following new series have been prepared (the numbers of the embryos are those under which they were originally entered in my manuscript catalogue. The letter "a" following the number indicates that the embryo forms part of the collection obtained in the season 1898-9, after the list published in my "Outlines of the Development of the Tuatara" (DENDY, 1899, *a*, p. 10) had been drawn up. The stages are, as in the preceding paragraph, those which I proposed in the paper referred to) :—

Embryo 24a, about Stage O.—Fixed in Kleinenberg's picric acid, December 30, 1898. Preserved in alcohol. Stained in bulk with Ehrlich's hæmatoxylin and counter-stained on the slide with picro-indigo-carmine. Sections longitudinal vertical (as to head).

Embryo 32a, Stage O.—Fixed in Kleinenberg's picric acid, January 9, 1899. Preserved in alcohol. Stained in bulk with Ehrlich's hæmatoxylin, and on the slide with picro-indigo-carmine. Sections longitudinal vertical (as to head).

Embryo 37a, Stage O-P.—Fixed in Kleinenberg's picric acid, January 9, 1899. Preserved in alcohol. Stained in bulk with Ehrlich's hæmatoxylin and on the slide with orange G. Sections longitudinal vertical (as to head).

Embryo 50a, Stage P-Q.—Fixed in Kleinenberg's picric acid, January 30, 1899. Preserved in alcohol. Stained in bulk with Ehrlich's hæmatoxylin. Sections transverse (as to head).

Embryo 51a, Stage P-Q.—Fixed in Kleinenberg's picric acid, January 30, 1899. Preserved in alcohol. Stained in bulk with Ehrlich's hæmatoxylin and on the slide with picro-indigo-carmine. Sections transverse (as to head).

Embryo 141, Stage R.—Fixed in Kleinenberg's picric acid (?), March 8, 1898. Preserved in alcohol.

* This is one of the specimens which were hatched out in Prof. HOWES' laboratory at the Royal College of Science, from eggs which were taken to England by my wife (*vide* HOWES and SWINNERTON, 1901).

Stained in bulk with borax carmine and on the slide with picro-indigo-carmin. Sections transverse (as to head).*

I have been thus particular in specifying the material which I have had at my disposal for two reasons. In the first place, it will greatly facilitate reference, and enable me to avoid repetition in the text; and in the second place, as the material is very difficult to obtain and will probably be much more so in the future, it is very important that the permanent preparations should be properly catalogued so as to be available for future workers who may wish to criticise my results or to extend my investigations. I have also gone into considerable detail with regard to technique in the hope that those who come after me may profit, not only by such success as I have obtained, but also by my failures.

III.—RELATIONS OF THE BRAIN AND ITS MEMBRANES TO THE CRANIAL CAVITY.

The *dura mater*, or, more correctly speaking, the inner portion of the *dura mater*, is a thin but very well defined membrane which separates readily from the adjacent cranial wall. It encloses a very large sub-dural space which almost completely surrounds the brain, though more extensive above than below it. Hence it comes about that the brain occupies not nearly the whole of the cranial cavity, being suspended in it by innumerable thin strands of connective tissue which extend radially across the sub-dural space and connect the *dura mater* with the *pia*, which latter closely invests the brain. Across the sub-dural space also stretch numerous blood-vessels and the roots of the cranial nerves, which doubtless also play their part in keeping the brain in position. These relations are very clearly shown in fig. 1. In the course of preparation for section-cutting, the inner layer of the *dura mater* shrinks away from the cranial wall, so that a large space makes its appearance between the two, as shown in figs. 47–52. From the appearances presented in a series of transverse sections, such as is shown in the figures referred to, it seems probable that a layer of the *dura mater* is continued into the parietal foramen as the “capsule” of the pineal eye, but owing to the distortion produced by shrinkage it is difficult to determine the true relationships of the membranes concerned in this region. It is quite clear, however, that between the outer capsule of the pineal eye and the anterior extremity of the pineal sac (right pineal organ) the nerve of the pineal eye and the accompanying artery both lie outside the inner portion of the *dura mater*.

The inner layer of the *dura mater*, at the sides of and behind the pineal complex, also takes part in the formation of the floor of the great longitudinal venous sinus. It is reflected over the pineal complex as its pial investment, and thus the entire complex is bound together and attached to the cranial roof (fig. 52, text-figs. 13–16, *d. m. i.*).

The pineal complex is further held in position by a very thin membrane developed

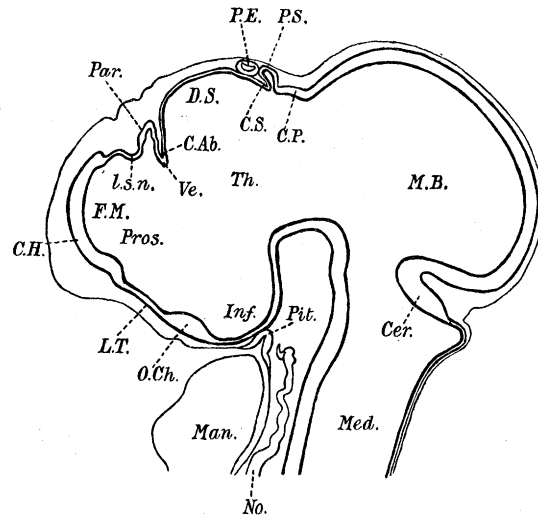
* I am indebted to Mr. R. W. H. Row, B.Sc., for the preparation of this series of sections.

on either side of the dorsal sac and stretching transversely across the sub-dural space. These membranes are evidently formed by a concentration of the delicate strands of connective tissue which traverse the sub-dural space all round the brain, and which frequently form a kind of arachnoid network. A similar membrane may be incompletely developed in the sagittal plane, extending backwards from the hinder margin of the pineal sac, as faintly indicated in fig. 1.

We are not concerned here with the topographical relations of the brain and its membranes in other regions, but I may be allowed to lay stress on the extraordinary disparity between the size of the brain and that of the cranial cavity. It follows that the shape of the latter can afford no reliable indication of that of the former. The same is probably true of many fossil reptiles, so that the greatest caution should be exercised in drawing conclusions from the study of casts of the cranial cavity. The very large sub-dural space arises late in development, and the relatively small size of the brain, due apparently to arrested growth, seems therefore to be a cænogenetic rather than a palingenetic character.

IV.—GENERAL MORPHOLOGY OF THE THALAMENCEPHALON AND ADJACENT PARTS OF THE BRAIN.

A. *Condition at Stage O.*—The fundamental relations of the different parts of the fore-brain and its derivatives may be advantageously studied in the first instance in sagittal sections of embryos of about Stage O, such as is represented in text-fig. 1,



TEXT-FIG. 1.—Sagittal Section of the Head of Embryo 24a (Stage N-O).
(For explanation of lettering see pp. 327-329.)

which, though taken from another specimen, is very similar to one which I figured on a previous occasion (DENDY, 1899, *b*). The cerebral hemispheres (*C. H.*) are just beginning to bud out from the prosencephalon (*Pros.*) above the *lamina terminalis* (*L. T.*), their limits being clearly defined by a conspicuous thickening of the brain-

wall. (The section is represented as passing a little to one side of the middle line in this region, and therefore not exactly between the two hemispheres.) The boundary between the prosencephalon and the thalamencephalon is marked by the *velum transversum* (*Ve.*); that between the thalamencephalon and the mid-brain by the anterior end of the posterior commissure (*C. P.*), which is generally regarded as itself belonging to the roof of the mid-brain. A short way in front of the posterior commissure, the superior or habenular commissure (*C. S.*) is just beginning to develop, and between the superior commissure and the *velum transversum* the thin roof of the third ventricle forms the already strongly arched dorsal sac (*D. S.*). The brain roof between the superior and posterior commissures is evaginated to form the pineal sac (*P. S.*) (actually the posterior, morphologically the right of the two pineal organs), immediately in front of which, still touching it and resting upon the dorsal sac, lies the vesicle of the pineal eye (*P. E.*) (actually the anterior, morphologically the left of the two pineal organs).

The *velum transversum* is formed by an infolding of the thin roof of the brain; at the bottom of the fold, at the spot marked *C. Ab.*, the *commissura aberrans** will appear later on. Immediately in front of the velum, a median evagination of the thin roof of the prosencephalon (*lamina supraneuroporica*) has given rise to the commencement of the paraphysis (*Par.*). In front of the paraphysis, again, immediately above the foramina of Monro (*F. M.*), is seen the remainder of the *lamina supraneuroporica* (*l. s. n.*).

The infundibulum (*Inf.*) is represented by a wide ventral diverticulum immediately behind the optic chiasma, and the pituitary body (*Pit.*) has already come into intimate relation with its floor.

B. *Condition at later Embryonic Stages.*—I have already (DENDY, 1899, *b*) described the general condition met with in embryos of Stage R, † which is also represented in text-figs. 4–11. I shall have to refer to these figures in illustration of special points later on, but in the meantime we may pass on at once to Stage S. It will be seen from examination of fig. 45 that the thin-walled dorsal sac (*D. S.*) has become more strongly arched, and that the upper part of its wall has become infolded to form a complex choroid plexus (*c. p. B.*). The opening of the dorsal sac into the lower division of the third ventricle (*V. 3*) has apparently become constricted by the mutual approximation of the posterior commissure (*C. P.*) and the *commissura aberrans* (*C. Ab.*), the latter having now become conspicuous in the fold of the velum, while the former has itself become enlarged and folded so as to project into the brain cavity. On the ventral face of the posterior commissure, the deep longitudinal groove of the sub-commissural organ (*s. c. o.*), with its characteristic columnar epithelium, has made its appearance.

* I accept the name proposed by ELLIOT SMITH (1903) for this commissure, which is also known as the *commissura fornicis* (DENDY, 1899, *b*) and as the *commissura pallii posterior* (VON KUPFFER, 1906).

† Compare especially the sagittal section represented in Plate 12, fig. 15, *op. cit.*

The constriction of the mouth of the dorsal sac is perhaps partly due, as I have previously suggested, to the straightening out of the cerebral flexure (consequent upon the development of the cerebral hemispheres). With this constriction, in turn, must be associated the characteristic bending of the now greatly elongated pineal sac (*P. S.*), which occurs at about this period. This organ at Stage R was still a simple finger-shaped tube, which had grown upwards and forwards in close proximity to the posterior wall of the dorsal sac (compare DENDY, 1899, *b*, Plate 12, fig. 15, *Pa. S.*). Its opening, between the posterior and superior commissures, had already become obliterated, probably by the same process of compression of the long axis of the brain-roof which causes the constriction of the mouth of the dorsal sac, and especially by the great increase in size of the posterior commissure. In this process the lower extremity of the pineal sac is pulled forwards, until at Stage S the whole organ has become bent sharply in the middle, in the form of a V, as shown in fig. 45. At the same time its wall has begun to fold, especially at the bend, so that in the section figured it appears as if completely divided into two parts, an appearance which, as SCHAUINSLAND has already pointed out, is, of course, quite deceptive. The bending and folding of the pineal sac are probably assisted by the development above it of the supra-occipital cartilage (figs. 43, 45, *S. O. C.*), which must prevent it from expanding in an upward direction.

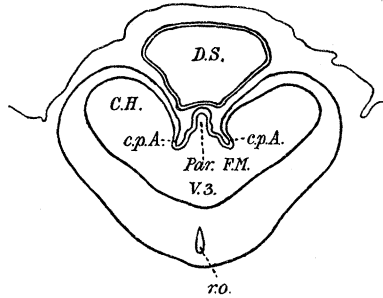
The pineal eye at Stage S (fig. 45, *P. E.*) has become somewhat widely removed from the end of the pineal sac and from the brain-roof by the development, firstly, of intervening mesenchyme, and, secondly, of the paraphysis (*Par.*). It has also become separated from the superficial epiblast by the development of the parietal plug (*P. P.*).

The paraphysis has now grown upwards and backwards in close proximity to the antero-dorsal wall of the dorsal sac, and it even extends in between the extremity of the pineal sac and the choroid plexus of the dorsal sac, as shown in fig. 45. From its first appearance its walls were more or less folded; this folding has now greatly increased, and the whole organ has become enveloped in highly vascular connective tissue, by which it is firmly attached to the roof of the dorsal sac. The cavity of the paraphysis still opens freely into the third ventricle immediately in front of the *commissura aberrans*. Its opening is marked *O. P.*

C. The Lateral Choroid Plexuses (Plexus Hemisphærium) and their Relations to the Paraphysis, etc.—Transverse sections of embryos at about Stage P-Q show the origin of the choroid plexuses of the third and lateral ventricles, which arise in direct continuity with the wall of the paraphysis. They are really paired structures, arising right and left of the paraphysial opening, as shown in text-fig. 2, but, from the first, their attachments extend a little in front of the paraphysial opening, where they may appear in a longitudinal vertical section which is not strictly median.

It is perfectly clear that the paraphysis and the lateral choroid plexuses are parts of one and the same system of folds, the former being formed by evagination and the

latter by invagination of the thin roof of the prosencephalon (*lamina supra-neuroporica*), between and above the foramina of Monro, and just in front of the *commissura aberrans* (text-figs. 1 and 2). The fact that, as I shall show later on, the



TEXT-FIG. 2.—Transverse Section of the Brain of Embryo 51a (Stage P-Q) through the Foramina of Monro. (For explanation of lettering see pp. 327-329.)

paraphysis is supplied mainly by branches of the anterior choroidal arteries, affords a further justification for regarding it morphologically as part of the system of choroid plexuses.

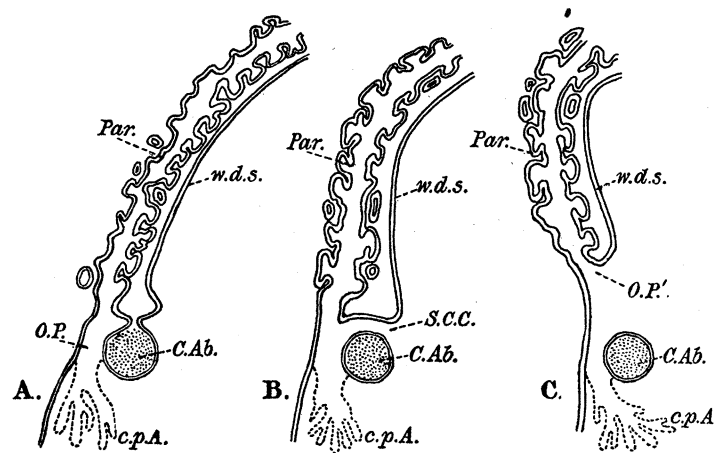
I have already (DENDY, 1899, *b*)* figured these structures in a series of transverse sections of Stage R, but their relations are better shown in a similar series of sections of Embryo 162 (also Stage R), prepared by Prof. HOWES and Dr. SWINNERTON, some of which are represented in text-figs. 4-11. Text-fig. 5 shows these relations very distinctly. By the time this stage is reached, the lateral choroid plexuses have grown through the foramina of Monro into the lateral ventricles, as shown in the figure.

The choroid plexus of the third ventricle (fig. 45, *c. p. A.*) consists simply of folds of the right and left lateral choroid plexuses (*plexus hemisphaerium*), which do not enter the foramina of Monro. There is no independent choroid plexus of the third ventricle.

The only further change of importance which takes place in the relations of the paraphysis, choroid plexuses and dorsal sac with the attainment of the adult condition consists in the curious shifting of the opening of the paraphysis, which I believe has never hitherto been observed. As the large anterior choroidal veins and arteries develop, the roots of the lateral choroid plexuses become so much swollen that the original opening of the paraphysis, lying between them, is practically obliterated. In the meanwhile, however, a narrow longitudinal canal, which I propose to call the supra-commissural canal (text-fig. 3, B, and fig. 45, *S. C. C.*) is formed above the *commissura aberrans* by ingrowth of the ependymal epithelium from in front and behind. Thus a direct communication is established between the

* In the work referred to I have spoken of the lateral choroid plexuses as springing from a common origin, but I think that the context and the accompanying figure make it clear that this common origin includes the origin of the paraphysis.

cavity of the paraphysis and that of the dorsal sac. In the adult, however (text-figs. 3, C, and 12), this secondary opening of the paraphysis into the dorsal sac (*O. P'*) no longer lies immediately over the *commissura aberrans*, but at some considerable distance above it, in what is apparently the anterior wall of the dorsal sac. This change of position has doubtless been effected by growth of the anterior wall of the paraphysis itself, so that the (apparent) portion of the wall of the dorsal sac which lies between the secondary opening of the paraphysis and the roots of the lateral choroid plexuses in the adult is really paraphysial in origin, and does not belong to the dorsal sac at all. The manner in which these changes have taken place is clearly indicated in text-fig. 3, which should render further explanation unnecessary.



TEXT-FIG. 3.—Three Diagrammatic Sagittal Sections through the *Commissura aberrans* and the Lower Part of the Paraphysis at different stages of development, to show the formation of the supra-commissural canal and shifting of the paraphysial opening.

(For explanation of lettering see pp. 327-329.)

Not being aware of the formation of the supra-commissural canal at later stages of the development than those which he examined, ELLIOT SMITH (1903) has naturally criticised my earlier figure of a sagittal section of Stage R (1899, *b*, fig. 15), showing the relations of the *commissura aberrans* (= *commissura fornicis*), on the ground that I have represented the latter as having a complete epithelial sheath. I must admit that the figure in question is somewhat crude, but as a matter of fact the epithelial sheath of the *commissura aberrans*, in the sagittal plane, is already nearly if not quite complete at this stage.

It has been the more necessary to dwell at some length upon the relations of the dorsal sac, paraphysis, *velum transversum* and lateral choroid plexuses, as they are not as yet by any means generally understood. Thus, SCHAUINSLAND, who figures an incomplete sagittal section of about my Stage S, labels the choroid plexus of the dorsal sac as paraphysis (1903, Taf. IX, fig. 74), and the drawings given by GISI (1907) are very incorrect. Examination of text-figs. G, O, P, and Q of the latter author

shows that she had failed to understand the relations of the *velum transversum* and choroid plexuses of the third and lateral ventricles, while the shifting of the opening of the paraphysis seems to have entirely escaped her notice, although she describes the separation of the *commissura aberrans* from the brain-wall in the sagittal plane.

I must confess I find it very difficult to understand GISI's account of the roof of the third ventricle, although she devotes much space to its description. According to her (*loc. cit.*, p. 61) the *velum transversum* consists, in embryos of stages O and P, of only a small transverse epithelial fold between the *commissura aberrans* and the paraphysis, which fold subsequently develops into a transverse plexus-plate with the *plexus hemisphærium et inferiores* and a *plexus medianus*, the latter extending backwards and upwards, beneath and behind the *commissura aberrans*, into the cavity of the dorsal sac. The *plexus hemisphærium* are, of course, what I have described above as the plexuses of the lateral ventricles, and the *plexus inferiores* are the portions thereof which lie in the third ventricle, but what the *plexus medianus* is I do not know, for I have not found it in my specimens, and GISI herself states that she has been unable to find it in other Saurians, though she finds it developed to some extent in certain Chelonians.

Her statements with regard to the existence of a *plexus medianus* in Sphenodon, however, are so precise that I have made a special search for it at all stages of development examined and in the adult, with the result that I have entirely satisfied myself that no such thing exists. The most that can be said is that the attachment of the lateral plexuses may in the adult extend backwards onto the under surface of the *commissura aberrans* (*cf.* text-fig. 13, *c. p. A.*), but transverse sections show clearly that there is no median plexus.

Neither can I agree with GISI in regarding the *velum transversum* as being represented in the adult by the choroid plexuses of the third and lateral ventricles. The latter are paired structures which grow into the ventricles from the sides of the original paraphysial opening, as I have shown above, while the velum is the median, unpaired, transverse fold which separates the paraphysis from the dorsal sac and in which the *commissura aberrans* is developed. If anything can be said to represent the *velum transversum* in the adult it is the *commissura aberrans* and its investing epithelium.

ELLIOT SMITH (1903), in his valuable paper on the Morphology of the Cerebral Commissures, has given some excellent figures of sections through the thalamencephalon and adjacent structures in Sphenodon embryos, based, like many of those in the present memoir, upon the material prepared by HOWES and SWINNERTON for their work on the skeleton. His results, so far as Sphenodon is concerned, agree in most respects with those which I published in 1899. I cannot altogether agree, however, with his account of the development of the lateral choroid plexuses. He speaks of an irregular fold which is invaginated into the ventricle between the

lamina terminalis and the paraphysis, and which he calls the *lamina choroidea*. This fold, which lies immediately in front of the paraphysial opening, is said to be prolonged laterally on each side, through the foramina of Monro, as the choroid plexus of the lateral ventricle. He figures it in a sagittal section of Stage S (*loc. cit.*, fig. 1). As I have already pointed out, transverse sections of earlier stages show clearly that the lateral choroid plexuses arise independently on either side of the paraphysis (text-fig. 2). Their attachments may extend forwards and come close together anteriorly, but there is no transverse *lamina choroidea* such as ELLIOT SMITH describes. What he figures as such is merely the root of one of the lateral choroid plexuses, visible because the section is not strictly median. His figure is evidently very diagrammatic; I have given an accurate representation of the most median section of what I believe to be actually the same series (Embryo II, Stage S) in fig. 45, from which it will be seen that immediately in front of the paraphysial opening (*O. P.*) there is only a slight projection to mark the anterior limit of the lateral attachments of the choroid plexuses—a very different thing from the conspicuous fold described and figured by ELLIOT SMITH.

It thus appears that while one author (GISI) has described the lateral choroid plexuses as arising from a transverse fold *behind* the paraphysial opening, another (ELLIOT SMITH) has described them as arising from a transverse fold *in front* of the paraphysial opening. The explanation of this discrepancy is that while they really arise one on either side of the paraphysial opening their roots of attachment may extend both a little in front of and behind the latter.

D. *The alleged Commissura Mollis*.—According to GISI (1907) there is, both in the adult and in advanced embryos, a *commissura mollis*, formed of fibres which cross the third ventricle, passing from the *nucleus rotundus* and *nucleus diffusus* of either side to those of the opposite side. I have examined five series of sections, transverse and longitudinal, of the adult brain without being able to find any such commissure; nor have I found it in embryos. In advanced embryos, however (*e.g.*, Stage R, text-figs. 7, 8), we do find that beneath the opening of the dorsal sac, below the interval between the *commissura aberrans* and the *commissura superior*, and a short way in front of the posterior commissure, the lateral walls of the third ventricle may come in contact with one another over a considerable area. This is doubtless due to the great increase in size of the developing optic thalami. Apparently, however, no actual fusion takes place between the walls, for at Stage S sagittal sections show nothing at all in the median plane in this region (*cf.* fig. 45), and the same may be true of the adult (text-fig. 12), the opposite walls of the third ventricle not even being in contact. They may possibly, however, have shrunk away from one another in the course of preparation, for the ependymal epithelium becomes thinned out over the area in question on either side, and may even disappear to a large extent, which seems to indicate that the lateral walls of the third ventricle are normally in contact with one another in this region.

VON KUPFFER (1906, p. 241) describes an identical condition in the advanced embryo of *Anguis* as follows :—“ An Querschnitten durch das Diencephalon sieht man eine scharfe Scheidung in eine schmale Dorsalregion und einen viel breiteren und höheren ventralen Teil. Dazu kommt die Bildung der *Massa intermedia* (*Commissura mollis*), die durch mediane Vereinigung der Seitenwände in beschränkter Ausdehnung zustande kommt (fig. 261).

“ Die Bildung der *Massa intermedia* ist ein Vorgang, der an der Vereinigung der *Lobi vagi* am Myelencephalon der Fische sein Analogon findet (vgl. fig. 125). An diesem Embryo von *Anguis* ist ebenfalls an der Kontaktfläche das Ependym noch nicht ganz geschwunden, und es ist nicht bekannt, ob überhaupt später eine vollständige Vereinigung erfolgt, wie sie bei Schlangen, Krokodilen und Schildkröten statthat.”

GISI (1907, p. 110) observes that in the presence of a feebly developed *commissura mollis*, *Sphenodon* (*Hatteria*) makes an approach to the *Chelonia*. We must now recognise the fact that a true fibrous *commissura mollis* has no more existence in *Sphenodon* than has the *plexus medianus*, which also is said to occur in *Chelonians*. GISI quite rightly concludes, on the whole, that the brain of *Sphenodon* is essentially Lacertilian in structure. The elimination of the supposed *commissura mollis* and *plexus medianus* perhaps helps to strengthen this conclusion. We require further information, however, with regard to the distribution of the *commissura mollis* in the reptilian series before arriving at any definite conclusions as to its taxonomic value. The most complete account of this structure, as it occurs in reptiles, is, so far as I know, that given by EDINGER (1899), in his well-known researches on the comparative anatomy of the brain, and even this is not altogether clear. His description is so short that it may be quoted in full in this connection :—

“ Bei den Schildkröten und bei den Sauriern, auch bei einigen Schlangen, treten die Massen des *Nucleus diffusus* dicht hinter dem *Nucleus rotundus* von beiden Seiten her über die Mittellinie hinweg miteinander in Verbindung. So entsteht eine Querverbindung, welche den dritten Ventrikel in einen ventralen und einen dorsalen Abschnitt teilt, eine echte *Commissura mollis*. Sie fehlt den Eidechsen. Beim Alligator und Krokodil liegt nun mitten in den relativ spärlichen Nervenzellen, welche sich hier in der Brücke befinden, ein mächtiger, wohl abgeschlossener Kern, der *Nucleus reuniens*. Er hat grosse multipolare Ganglienzellen und entsendet nach jeder Seite markhaltige Nervenfasern, die weithin, bis nahe an die Peripherie des Zwischenhirnes treten, dann aber der Verfolgung verloren gehen. Taf. 1, Fig. 1—5.

“ Es handelt sich hier nicht um ein echtes Homologen der *Commissura mollis*. Denn diese ist bei den Säugern nicht kernhaltig, wird auch ausschliesslich vom zentralen Höhlengrau gebildet. Natürlich nimmt dies letztere auch—überziehend—an der Bildung der Querplatte teil, weil es ja überall den Ventrikel auskleidet” (p. 175).

Fig. 5 on EDINGER'S Plate I represents a transverse section showing complete fusion between the right and left optic thalami in *Chelone*, with no trace of the line

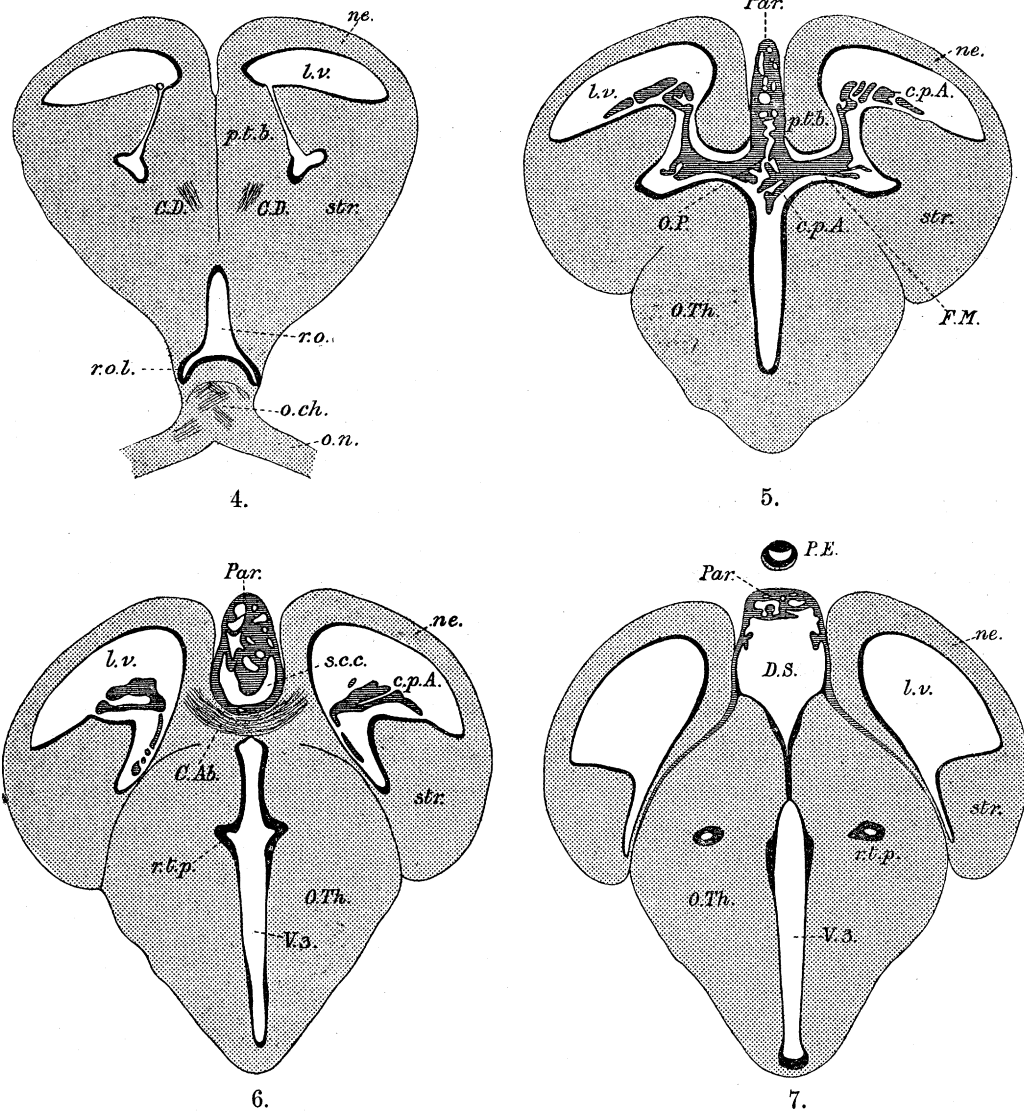
of fusion remaining—a far more highly modified condition than that seen in Sphenodon, as will be evident from comparison with my own figures. EDINGER'S fig. 6 on Plate II shows the still more advanced condition, with a well-developed *nucleus reuniens*, met with in Alligator, and his figs. 1 to 3 on Plate I show the same condition (with well-developed *nucleus reuniens*), in Varanus, a lacertilian, although a true *commissura mollis* is said to be wanting in lizards. The difference between Sphenodon and Varanus, in this respect, appears actually to be greater than that between Sphenodon and Chelone.

E. *Lateral Diverticula of the Third Ventricle and Iter.*—A conspicuous feature of the brain of Sphenodon, when examined by means of serial sections, is the presence (in addition to the ventricles of the cerebral hemispheres and optic lobes and the pineal outgrowths) of three pairs of lateral diverticula of the central canal, and as these may have an important bearing on the neuromeric analysis of the brain and the probability of a serial homology between the lateral eyes and the pineal organs, I propose to give a short account of them in this place.

The most anterior of the three pairs may be termed the *recessus optici laterales*; they appear to be remnants of the cavities of the stalks of the optic vesicles. At Stage R they are conspicuous in transverse sections through the region of the optic chiasma as a pair of lateral, downward-pointing outgrowths of the *recessus opticus* of the third ventricle, above the optic chiasma (text-fig. 4, *r. o. l.*). Their blind latero-ventral extremities at Stage S form slight projections on the surface of the brain just in front of the optic chiasma (fig. 44, *r. o. l.*). In the adult they are quite as conspicuous, opening by narrow mouths into the median *recessus opticus* (= *recessus præopticus* of some writers) above the optic chiasma, and running outwards, downwards and forwards to end each in a vesicular dilatation just where the optic chiasma parts company with the brain as the median stalk of the optic nerves. Each of these dilatations gives rise, as at Stage S, to a small protuberance on the lateral surface of the brain in the angle between the optic chiasma and the cerebral hemisphere. The *recessus opticus lateralis* is shown quite clearly in GIST'S fig. G, p. 45 (1907), where it is labelled "Ausstülpung d. Ventrikels."

The second pair I propose to term the *recessus thalami prænucleares*, because they lie in the substance of the optic thalami in front of the *nuclei rotundi*. Transverse sections of Stage R show the openings of these recesses into the third ventricle beneath the *commissura aberrans* (text-fig. 6, *r. t. p.*). From this point they run outwards into the substance of the optic thalamus, and their blind ends are directed backwards (text-fig. 7, *r. t. p.*). Longitudinal vertical sections of Stage S show the prenuclear recess (fig. 44, *r. t. p.*) lying immediately in front of the *nucleus rotundus*, rather below its centre and slightly behind the *recessus opticus lateralis* and the foramen of Monro. In the adult it has much the same relations, lying in the optic thalamus between (and below) the *commissura aberrans* and the habenular ganglion on each side. It runs outwards at first, approximately at right angles to

the ependymal surface of the third ventricle, but its terminal, somewhat dilated, blind extremity turns backwards. The epithelial lining of the recess has become thrown into folds, so that the lumen of the backwardly directed extremity exhibits a radiate appearance in transverse sections.



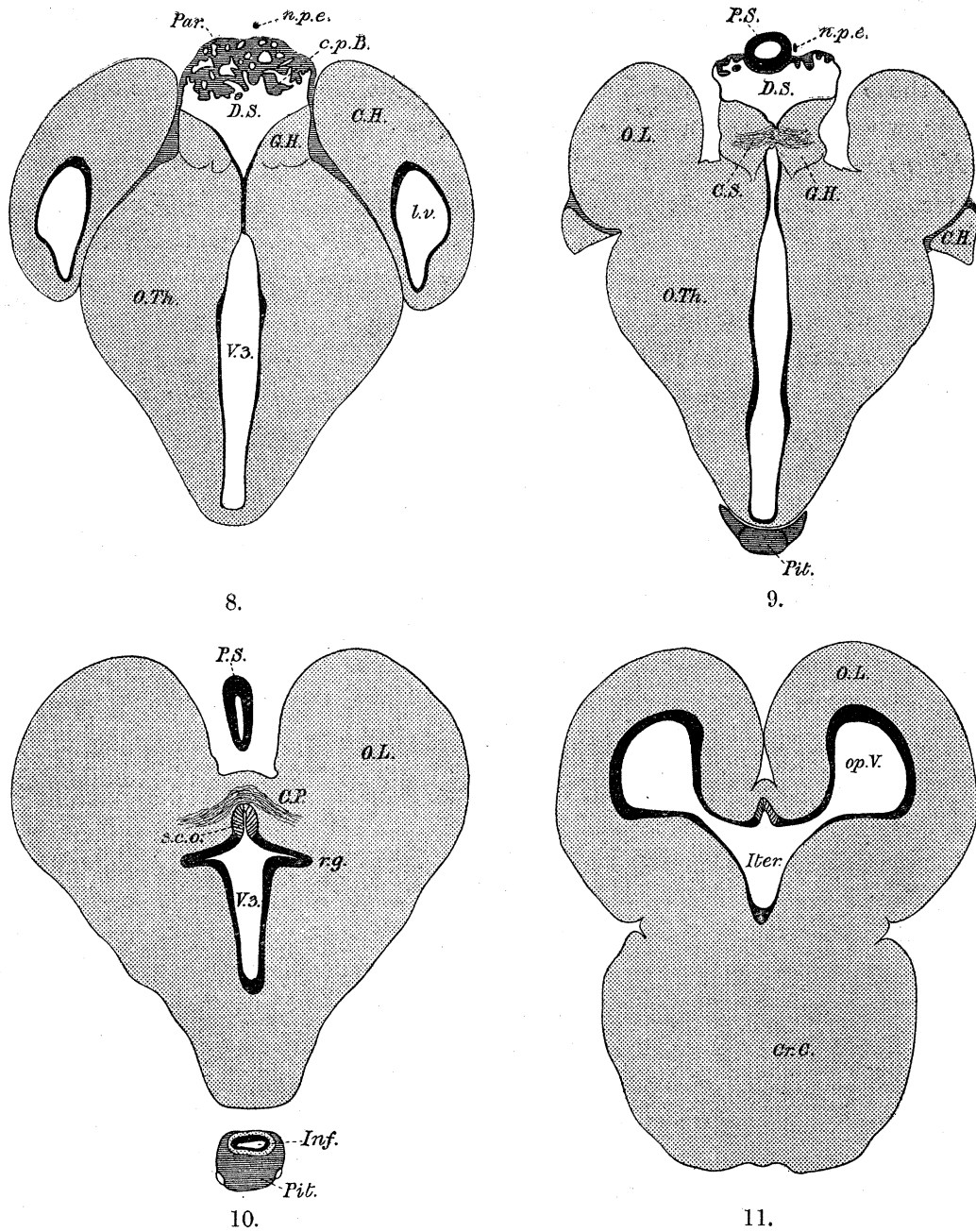
TEXT-FIGS. 4-7.—Transverse Sections of the Brain of Embryo 162 (Stage R).*
 (For explanation of lettering see pp. 327-329.)

GISI (1907, p. 47) describes a small oval recess lying in a groove between the anterior thalamus nuclei and the *nucleus rotundus*, which is probably identical with my *recessus thalami prænuclearis*.

The third pair of lateral diverticula in question belong to the *iter* rather than to the third ventricle. One of them (labelled *recessus geniculi*) is clearly shown in

* Right and left sides are reversed in these figures.

GISI's fig. G, representing the interior of the third ventricle. They lie on either side of the entrance to the *iter*, beneath the posterior commissure and



TEXT-FIGS. 8-11.—Transverse Sections of the Brain of Embryo 162 (Stage R).*
 (For explanation of lettering see pp. 327-329.)

sub-commissural organ and behind the *nucleus rotundus*. They are already conspicuous in transverse sections of Stage R, as shown in text-fig. 10 (*r. g.*). In longitudinal vertical sections of Stage S the lumen of each *recessus geniculi*, itself

* Right and left sides are reversed in these figures.

seen in transverse section, exhibits a characteristic tri-radiate appearance (fig. 44, *r. g.*). In the adult they have the same relations; they run out nearly at right angles to the ependymal epithelium, but slightly downwards and forwards, and their walls are slightly folded.

In all these pairs of recesses the ependymal epithelium tends to take on a columnar character, whereby it becomes more or less conspicuously thickened.

F. *Neuromery of the Fore- and Mid-brain.*—The question of the number of neuromeres which take part in the formation of the brain, and of the relation which these bear to the different parts thereof, is one about which there is still much diversity of opinion. The generally accepted view appears to be that there are three neuromeres in the fore-brain, two in the mid-brain, and at least six in the hind-brain (*cf.* VON KUPFFER, 1906), and this is the view which I have hitherto myself accepted (DENDY, 1907, *b*), though I have followed HILL (1900) rather than VON KUPFFER in endeavouring to determine the boundaries between the neuromeres.

According to VON KUPFFER, the first neuromere gives rise to the telencephalon (= prosencephalon of English nomenclature); the second he terms the parencephalic, and the third the synencephalic neuromere, and these two together give rise to the diencephalon (= thalamencephalon), the boundary between which and the mesencephalon is marked dorsally by the posterior commissure.

From the telencephalon arise, according to VON KUPFFER, the cerebral hemispheres and the paraphysis, from the parencephalon arise both the lateral eyes and the pineal organs (*vide* VON KUPFFER'S fig. 102B, *op. cit.*), while the synencephalon forms a narrow segment intercalated between the epiphysial outgrowths and the first neuromere of the mid-brain.

It is beyond the scope of the present work to enter into a detailed discussion of this very difficult problem, but I may point out that, in accordance with the interpretation of the neuromery of the fore-brain given by HILL,* the pineal organs belong to the third, and not to the second neuromere, the boundary between the second and third neuromeres being placed much more anteriorly than in VON KUPFFER'S scheme. This seems to fit in much better with the fact that, in *Sphenodon*, at any rate, the epiphysial outgrowths arise immediately in front of the posterior commissure, which admittedly marks the commencement of the mid-brain. I cannot help suspecting that the segment which VON KUPFFER marks "Synencephalon" in *Anguis* (*op. cit.*, figs. 240, 244) is really the first neuromere of the mid-brain.†

It is possible, as already suggested, that some light may be thrown upon this question by the arrangement of the various paired outgrowths of the fore- and mid-brain in *Sphenodon*. Of these diverticula, there arise altogether six pairs: (1) the cerebral hemispheres; (2) the optic vesicles of the lateral eyes; (3) the *recessus thalami prænucleares*; (4) the pineal outgrowths (the evidence in favour of the

* In the case of SALMO, *op. cit.*, pp. 407, 411.

† Compare, however, VON KUPFFER'S remarks on *Acanthias* (*op. cit.*, p. 75).

paired origin of these will be discussed later on); (5) the *recessus geniculorum*; and (6) the optic lobes. It is tempting to suppose that all these pairs of outgrowths of the primitive neural tube are serially homologous with one another, and that each pair indicates an originally separate neuromere. Such a supposition, of course, involves belief in the existence of four neuromeres in the fore-brain, instead of the three usually admitted, a belief which, in view of the extreme difficulty of following the development of the neuromeres and determining their boundaries, does not seem unreasonable. In accordance with this view, the cerebral hemispheres would belong to the first neuromere of the fore-brain (telencephalon or prosencephalon), the optic vesicles of the lateral eyes to the second neuromere of the fore-brain, the *recessus thalami prænucleares* to the third neuromere of the fore-brain, the pineal outgrowths to the fourth neuromere of the fore-brain, the *recessus geniculorum* to the first neuromere of the mid-brain,* and the optic lobes to the second neuromere of the mid-brain.

JOHNSTON (1906), led away apparently by the idea that the antero-posterior relations of the pineal outgrowths are primary, and not, as I believe, secondary, places one epiphysial outgrowth in the third, and the other in the fourth neuromere. Considering that the fourth neuromere, in accordance with the enumeration which he adopts, belongs to the mesencephalon, while both epiphysial outgrowths lie in front of the posterior commissure, this proceeding is manifestly inadmissible.

In the absence of further evidence, I do not wish to press my own suggestion as to the neuromery of the fore- and mid-brain, but merely to bring forward facts which must be taken into account before any final solution of the problem can be attained. Whether three or more neuromeres have taken part in the formation of the fore-brain makes little difference to the question of the supposed serial homology between the pineal outgrowths and the lateral optic vesicles, but, of course, if these can be shown both to belong to one and the same neuromere, as suggested by VON KUPFFER, the argument is seriously affected. I do not think, however, that the evidence for regarding them as belonging to the same neuromere is any more convincing than that for regarding them as belonging to different neuromeres, and, if my suggestion as to the neuromery is correct, they are actually separated by an intervening neuromere. We shall have occasion to refer to this question again when we come to deal with the comparison of the pineal organs with the lateral eyes.

V.—THE PINEAL COMPLEX.

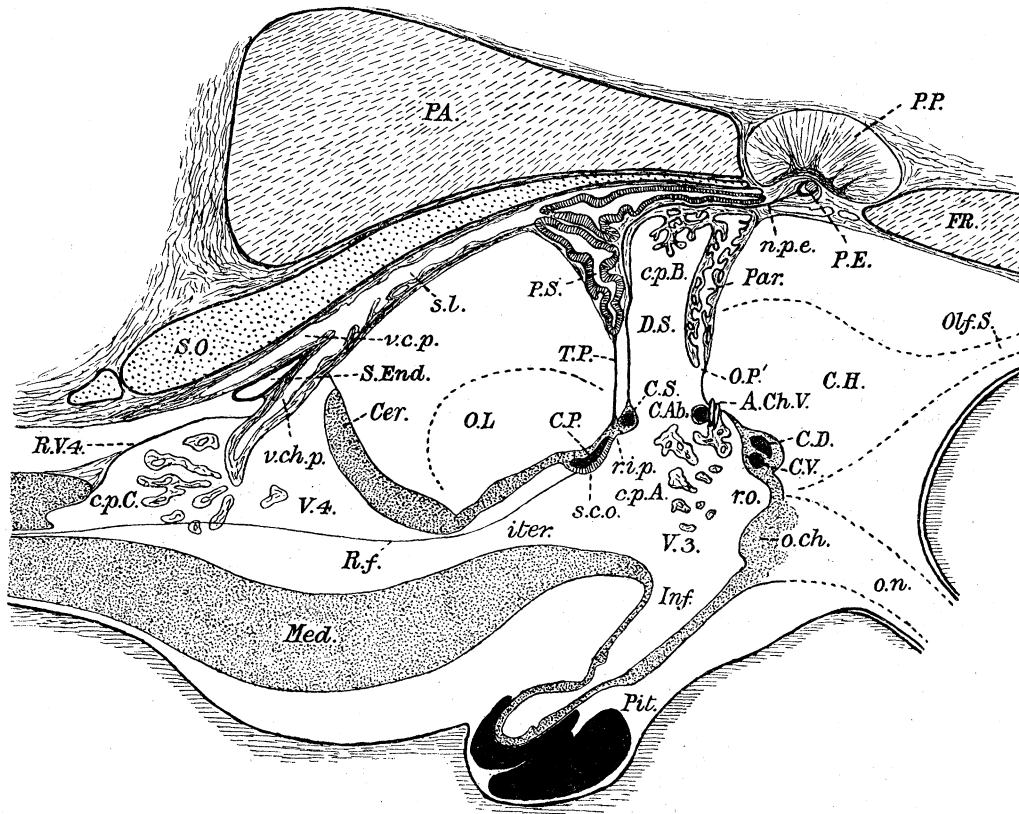
Under this heading I propose to describe the minute structure and relations of those organs which form the main subject of the present memoir, viz., the dorsal

* My attention has been called to the fact that in mammals the *recessus geniculorum* are said to belong to the fore-brain. In *Sphenodon* they certainly appear to belong to the mid-brain (*cf.* text-fig. 10), and I think this view facilitates the interpretation of the neuromery. I have not attempted any comparison with the mammalian brain in this respect, and it is, of course, possible that the use of the term *recessus geniculorum* for the structures in question in the case of *Sphenodon*, in which I have followed GISI, will prove to be unjustifiable. I am indebted to Prof. ELLIOT SMITH for information on this point.

sac, the paraphysis, the pineal eye, the pineal sac (right pineal organ), the pineal nerves, and the parts of the brain with which these latter are immediately connected. The pineal complex, thus defined, comprises nearly, but not quite, the same group of structures as the "epithalamus" of various writers.

Apart from the pineal eye, which lies in the parietal foramen, and the central connections of the pineal nerves, the pineal complex in the adult animal forms a compact structure, triangular in side-view, attached below to the roof of the brain between the cerebral hemispheres and optic lobes, and gradually widening upwards to its attachment to the cranial roof by means of the *dura mater*, as already described in the section dealing with the relations of the brain and its membranes to the cranial cavity. It has roughly the form of a bilaterally compressed cone standing on a truncated apex. In side view the hinder margin of the cone, however, does not form an even line, a secondary apex being formed by the lower extremity of the pineal sac, as shown in fig. 1.

The general structure of the pineal complex in the adult animal is illustrated in text-figs. 12 to 16. The central portion is formed by the thin-walled dorsal sac (*D. S.*);



TEXT-FIG. 12.—Diagrammatic Sagittal Section of the Brain of *Sphenodon*, lying in the Cranium.
(For explanation of lettering see pp. 327-329.)

the anterior portion by the paraphysis (*Par.*), which also extends backwards for some distance over the roof of the dorsal sac, and the posterior portion by the

pineal sac (*P. S.*), which also extends forwards over the roof of the dorsal sac and over the paraphysis. These three structures together form the so-called "pineal gland" of some of the older writers. Though quite distinct in origin, they become very intimately associated in the adult and are held together by a common pial investment. At the lower extremity of the dorsal sac, right and left, posteriorly, lie the two habenular ganglia, connected together behind by a median portion beneath which lies the superior commissure (text-fig. 16).

A. *The Dorsal Sac.**

We have already noticed the origin of the dorsal sac from the strongly arched epithelial roof of the third ventricle, between the *commissura aberrans* and the *commissura superior*. It has at first (text-fig. 1) the form of a low dome, widest below, where it communicates freely with the lower part of the third ventricle, into which its wall dips down anteriorly to form the posterior face of the *velum transversum*. As development proceeds, the dorsal sac becomes compressed in two directions, antero-posteriorly by the mutual approximation of the *commissura posterior* and the *commissura aberrans* as already described and transversely by compression between the developing cerebral hemispheres (text-fig. 7), and by its attachment to the habenular ganglia (text-figs. 8, 9, 16). The compression in both directions affects chiefly the lower part of the dorsal sac, and in such a way that its opening into the lower division of the third ventricle, which latter is now itself greatly compressed bilaterally, in the adult forms a comparatively short and rather narrow longitudinal slit. Thus the upper part of the dorsal sac widens out both laterally and antero-posteriorly.

Beginning at about Stage O, the anterior wall of the dorsal sac bulges forwards over the *commissura aberrans* and the opening of the paraphysis, no doubt as a result of the antero-posterior compression of its opening. This forward bulging is clearly shown in text-figs. 1 and 2. It becomes counteracted, to some extent, by the pressure of the developing paraphysis, which lies against the anterior wall of the dorsal sac in the middle line, bulging it in in such a manner that the dorsal sac in the adult is produced forwards for a short distance on either side of the paraphysis, as shown in text-figs. 13 and 14 (*D. S.*). In Embryo II (Stage S) the pressure of the growing paraphysis has produced a backward slope of the anterior wall of the dorsal sac (fig. 45), but in the adult it slopes upwards and slightly forwards, as shown in text-fig. 12. That portion of the anterior wall which lies between the secondary paraphysial opening (*O. P.*) and the attachment of the lateral choroid plexuses in the adult is, as I have already pointed out, really paraphysial in origin (compare text-fig. 3). In the adult it becomes bulged backwards over the *commissura aberrans*, in such a manner as to give rise in transverse sections

* = "Zirbelpolster" (e.g. BURCKHARDT, 1894).

to the appearance of a recess of the dorsal sac, as shown in text-fig. 13 (*s. c. c.*). This recess, in part, represents the supra-commissural canal of earlier stages.

Posteriorly the mutual approximation of the posterior commissure and the *commissura aberrans* causes the wall of the dorsal sac to bulge backwards over the superior commissure, at the same time distorting the developing pineal sac, which lies immediately behind it, into the shape of a V, as shown in fig. 45 and text-fig. 12. The pressure of the latter, however, causes a counteracting inward bulging of the posterior wall of the dorsal sac in the middle line, on either side of which the dorsal sac projects backwards for a short distance as a blind diverticulum. The diverticulum on the right side may project further backwards than that on the left (fig. 43 and text-fig. 18, *D. S.*).

Below the lower extremity of the pineal sac, in the adult, the posterior wall of the dorsal sac narrows to a mere edge, which runs down to the median habenular ganglion, to which it is attached (fig. 55 and text-figs. 12, 16). Immediately above this ganglion the cavity of the dorsal sac may be produced backwards to form a small median posterior diverticulum (fig. 55).

The lateral walls of the dorsal sac in the adult are freely exposed except for their pial investment. They are attached below, posteriorly to the right and left and median habenular ganglia (text-fig. 16, figs. 54, 61, 62) and in front of these to the upper margins of the optic thalami (text-figs. 14, 15), passing into the anterior wall above the *commissura aberrans* (text-fig. 13). As they ascend from their attachment they may at first slope slightly inwards towards one another, but then outwards, so that the dorsal sac is considerably wider above than below (text-figs. 15 and 16).

The dorsal wall or roof of the dorsal sac is not exposed at all in the adult, being covered in front by the upper limb of the paraphysis and behind by the upper limb of the pineal sac, as shown in text-figs. 12, 14, 15, 16. Indeed these relations are already clearly shown at Stage S (fig. 45) and to a rather less extent at Stage R (DENDY, 1899, fig. 15). The pressure of the overlying paraphysis and pineal sac causes an inward bulging of the dorsal wall as shown in text-figs. 14-16.

The choroid plexus of the dorsal sac is a perfectly well defined structure, with its own special blood supply. It resembles the choroid plexuses of the lateral and fourth ventricles and consists of a series of irregular folds of the roof of the dorsal sac which hang down into its cavity and into which branches of the saccular arteries penetrate (fig. 74 and text-figs. 12, 15, 17, *c. p. B.*). These folds begin to form at about Stage Q (fig. 34), and in the adult they may be developed to a slight extent on the upper portions of the lateral walls, as well as on the dorsal wall of the dorsal sac.

The dorsal sac is everywhere lined by a single layer of epithelial cells (figs. 63, 64, *ep. w. d.*). On the choroid plexus these are large and cubical, elsewhere they may become more flattened, especially on the lower parts of the walls. The exposed

portions of the wall of the dorsal sac are very thin, the epithelial layer being backed up on the outside only by a thin pial investment composed of wavy fibrous connective tissue containing a few small blood-vessels (fig. 62) and doubtless also nerve-fibres, though these are difficult to demonstrate (compare, however, figs. 59, 61).

The histological structure of the choroid plexus deserves a more detailed description. The epithelial cells which cover its folds are very well defined, polygonal in surface view (fig. 73); almost square, but with convex outer surfaces, in vertical section (fig. 72). They have large spherical nuclei, lying slightly nearer to their inner than to their outer surfaces. There is no distinct nucleolus but a considerable number of well-defined chromatin granules fairly uniformly scattered through the nucleus. One or more of these granules, however, may be larger and more conspicuous than the remainder. The cytoplasm is finely granular and may exhibit a distinctly reticulate character (fig. 73). The cell boundaries are remarkably well-defined.

The most noteworthy histological feature, however, is the presence just outside and attached to the epithelial layer, in the interspaces between the folds of the choroid plexus (and therefore in the cavity of the dorsal sac), of a delicate, apparently cytoplasmic network containing numerous nuclei and closely resembling the endogastric network met with in some calcareous sponges (fig. 72, *C. P. N.*). I do not profess to understand the significance of this structure. One is tempted at first to suppose that it consists of moribund cells which have been shed from the epithelium, but this view is rendered untenable by the fact that the shape of the nuclei is different, being elongated and much more like that of the nuclei of the connective tissue which underlies the epithelium. In fact the network looks as if it were composed of extrusive connective tissue rather than of epithelial cells. As we shall see presently, a somewhat similar network occurs in the tubules of the paraphysis. Very similar networks also occur in the choroid plexuses of the fourth and lateral ventricles, which, indeed, are practically identical in structure with that of the dorsal sac.

The middle of each fold of the choroid plexus is occupied by a gelatinous- and only slightly fibrous-looking connective tissue, containing elongated nuclei, and concentrated beneath the epithelium to form a thin basement membrane. In this tissue run the slender, thin-walled, branching capillaries, lined by a very thin epithelial layer, as shown in fig. 72.

B. *The Paraphysis.*

The paraphysis first appears at about Stage N, some little time after the out-growth of the primary parietal vesicle. At this stage, as we have already seen, the *lamina supraneuroporica* becomes thrown into three folds, one median, the paraphysis, and two lateral, the lateral choroid plexuses (*cf.* text-figs. 1 and 2). These

structures arise in direct continuity with one another, but whereas the choroid plexuses grow inwards into the brain cavity, the paraphysis grows outwards as a hollow tube or sac, the posterior wall of which is continuous with the anterior limb of the *velum transversum*. The walls of the paraphysis remain thin, and consist throughout life of a single layer of epithelial cells. From their first appearance they are irregularly folded. As development proceeds the paraphysis grows upwards in close proximity to the anterior wall of the dorsal sac, and when Stage R is reached its distal end has turned backwards over the roof of the latter (DENDY, 1899, *b*, fig. 15). Meanwhile, folding of its wall has increased in such a manner as to give rise to a great number of irregular blind diverticula or crypts arranged more or less radially around the central lumen, which remains large and clearly recognisable throughout life. The condition at Stage S is shown in fig. 45. Numerous irregular blood-spaces develop between the diverticula, and the whole spongy mass of paraphysial crypts and blood-vessels becomes united together and firmly attached to the wall of the dorsal sac by the connective tissue of the *pia mater*.

The paraphysis originally opens into the prosencephalon in front of the *velum transversum*. I have already described how the opening becomes shifted during the course of development, so that it finally comes to lie in the anterior wall of the dorsal sac some distance above the *commissura aberrans* (text-fig. 3).

In the adult (compare text-figs. 12-16, and figs. 74, 75, 76) the paraphysis may be described as a compound tubular gland, with a central lumen opening direct into the cavity of the dorsal sac. The entire gland is somewhat flattened against the anterior wall of the dorsal sac, whose curvature of course it closely follows. Thus it at first slopes upwards and slightly forwards from its opening, and then turns sharply backwards between the choroid plexus of the dorsal sac and the ventral wall of the pineal sac, extending about as far backwards as the most posterior folds of the choroid plexus. We can thus distinguish between a long ascending limb of the paraphysis and a much shorter, upper, horizontal limb, as shown in text-fig. 12 and fig. 74. The central lumen is conspicuous throughout the ascending limb. The diverticula which it gives off are very irregular in shape and size, and arise mostly from its anterior and posterior faces. In *Sphenodon* VI the spaces between the diverticula on the posterior face of the ascending limb are occupied by an extraordinarily well developed network of thin-walled blood sinuses or capillaries, as shown in fig. 76. In other cases the reticulate arrangement of these sinuses is less evident, and they appear to be more strongly developed on the anterior face (*Sphenodon* V, fig. 74, *B.V.*). Dorsally, between the choroid plexus of the dorsal sac and the pineal sac, we find several large paraphysial diverticula, as well as a number of smaller ones (fig. 74, text-figs. 14, 15). The blood spaces or capillaries of the paraphysis are supplied by branches of the saccular and of the anterior choroidal arteries, and drain into the *sinus longitudinalis*, beneath the pineal sac (text-fig. 17 and fig. 74).

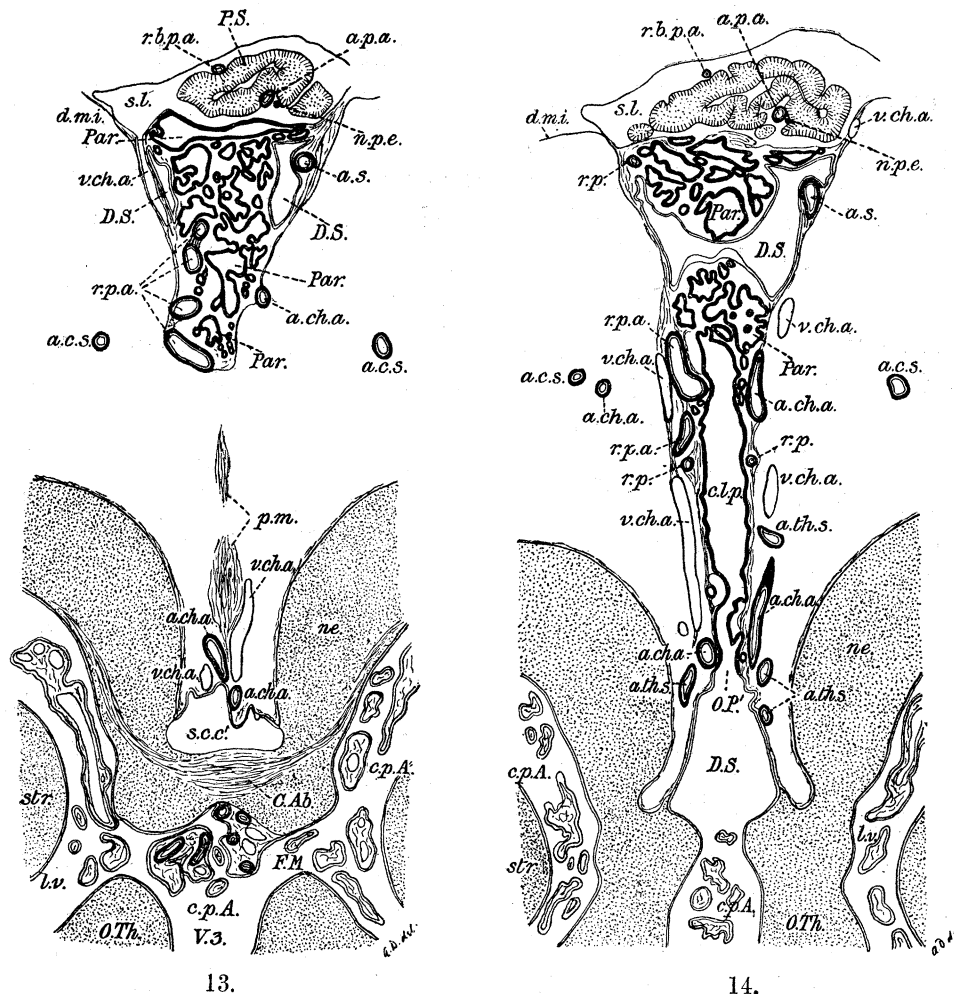
Histologically the paraphysis exhibits features of considerable interest, and differs sufficiently from the choroid plexuses to indicate that, although essentially similar in origin, it has become specially modified for a different function. Its epithelial lining, as already stated, consists of a single layer of cells, but the individual cells are not sharply defined as in the epithelium of the choroid plexus. On the contrary, there are no distinct cell-boundaries, and the finely granular cytoplasm of adjacent cells is connected by radiating strands, so that we have a kind of reticulate syncytium in which the nuclei are scattered at approximately equal intervals, as shown in fig. 77. The nuclei, again, differ from those of the epithelium of the choroid plexus in being usually more or less elongated instead of spherical (compare fig. 73). The chromatin, however, is arranged in much the same way in scattered granules with no nucleolus, but perhaps the nuclear reticulum is rather more distinct. In connection with this epithelium there is a very conspicuous but irregular network of nucleated cytoplasm lying in the paraphysial lumina (figs. 72, 75, *Par. N.*). The nuclei in this network are very poor in chromatin, and sometimes are seen to be undergoing amitotic division, as shown in fig. 78; I conclude, therefore, that they are degenerating. This network may be of the same nature as that which I have described above in connection with the epithelium of the choroid plexus, but in this case there appears to me to be more reason for regarding it as being derived from the epithelium itself rather than from the underlying connective tissue. It is far too constant and definite to be regarded as an artifact, a view which is also rendered untenable by the peculiarities of the nuclei.

In *Sphenodon VI* there is a very curious development of little rounded knobs projecting from the walls of the paraphysis into its various cavities (fig. 75, *Par. K.*). These knobs are covered by the ordinary paraphysial epithelium, and seem to be caused by the accumulation beneath this epithelium of a substance which stains conspicuously violet with picro-indigo-carmin (the material having been fixed and hardened in acetic bichromate). It may be that we have in these places a strong local thickening of the basement membrane, which elsewhere exhibits a very similar staining reaction, and is continuous with the deeply staining core of the paraphysial knobs. Here and there in the basement membrane immediately beneath the epithelium may be noticed a small spherical body of a deep violet colour (fig. 75, *s. b.*), which may represent the commencement of one of the knobs in question. In *Sphenodon V*, treated in the same manner, these structures are at the most only doubtfully recognisable. In *Sphenodon II* they appear to be present, but the staining is not suitable for their clear differentiation.

The interspaces between the various diverticula of the paraphysis are filled with slightly fibrous connective tissue containing numerous elongated nuclei, and thin-walled blood-vessels (figs. 72, 75, 76).

That the paraphysis is glandular in function there can, I think, be no doubt, and its anatomical relations suggest that it probably plays an important part in the

secretion of the cerebro-spinal fluid. The fact that it was interpreted as a vestigial sense-organ by its original discoverer, SELENKA (1890), and compared with the auditory organ of Ascidians, as the "Epiphysis" had previously been compared with the Ascidian eye, simply illustrates the danger of theorising upon an insufficient basis of fact, and the manner in which one erroneous comparison leads to another.



TEXT-FIGS. 13, 14.—Transverse Sections of the Pineal Complex, etc., of *Sphenodon* VI.*
(For explanation of lettering see pp. 327–329.)

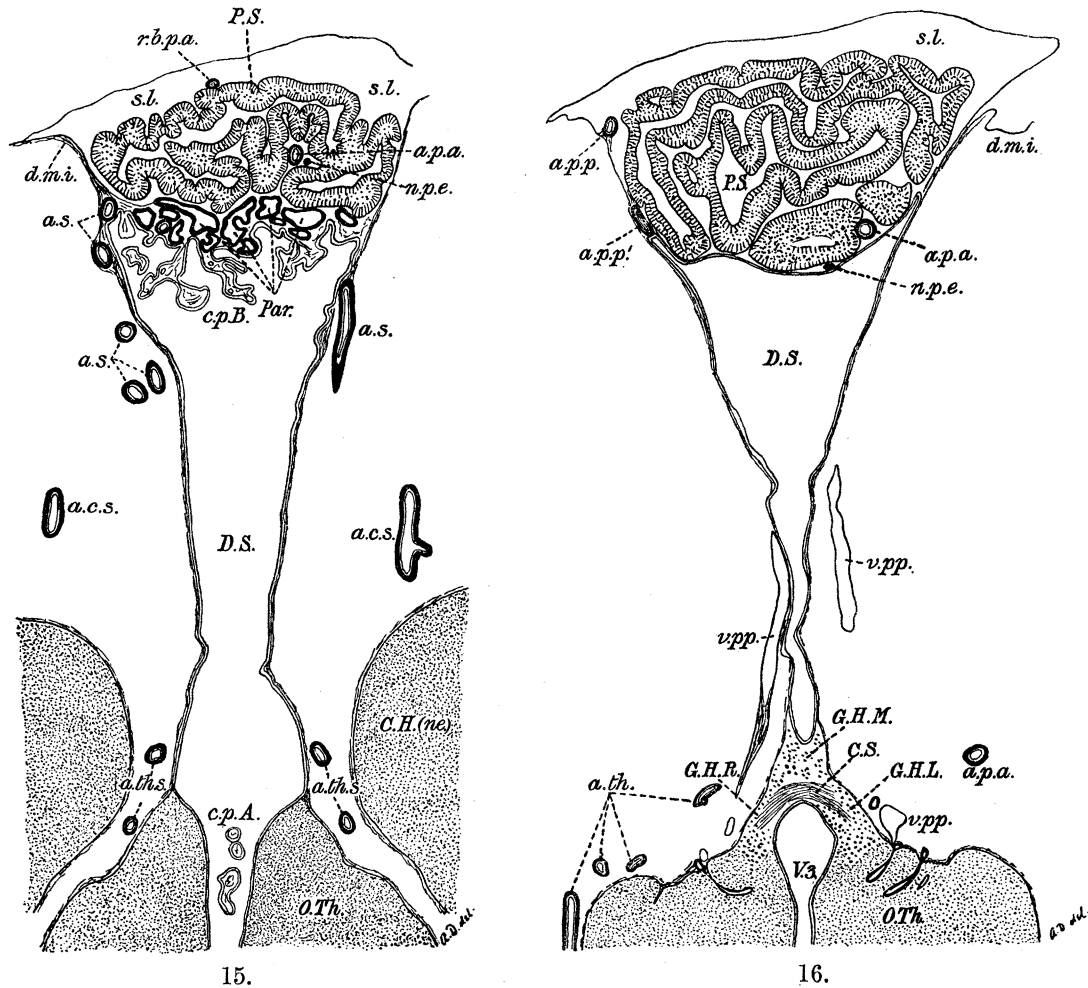
Morphologically, as I have more than once pointed out, the paraphysis is to be regarded merely as part of the same system of folds of the non-nervous portion of the brain-roof as gives rise to the choroid plexuses of the third and lateral ventricles.

C. The Pineal Sac.

The conspicuous and well-defined organ which I propose to term the pineal sac is, according to the interpretation adopted by me, the right-hand member of the original

* Right and left sides are reversed in these figures.

pair of pineal outgrowths. It has already received a variety of names at the hands of different writers. Of these the name "epiphysis" is perhaps the best known; but this term, having been very variously employed by different writers (and especially as a synonym for the supposedly unpaired "pineal gland," which includes in some cases much more than the pineal sac), appears now to be incapable of precise



TEXT-FIGS. 15, 16.—Transverse Sections of the Pineal Complex, etc., of *Sphenodon* VI.*
(For explanation of lettering see pp. 327–329.)

definition.† Similarly the term "pineal gland" itself is no longer applicable, partly owing to the loose manner in which it has been applied to different structures in different animals, and partly because it is doubtful how far the organ in question is really glandular in function.‡ *STUDNIČKA* (1905) terms the structure in question

* Right and left sides are reversed in these figures.

† I have discussed the use of the term "epiphysis" more in detail in my memoir on the development (*DENDY, 1899, b*).

‡ I must plead guilty, however, to having myself used the term "pineal gland" in my memoir on the Intracranial Vascular System (*DENDY, 1909*). *BURCKHARDT* (1894) and other German writers frequently make use of the term "Zirbel" to designate the structure in question.

simply the "pineal organ," and homologises it quite correctly with the pineal eye of the lampreys. The term "pineal organ," however, seems to be hardly sufficiently distinctive, for according to the view adopted by me it is only one of a pair of pineal organs, of which the other member in *Sphenodon* forms the pineal eye. It might be precisely defined as the right pineal organ, but some people would probably still object to this name on the ground that its paired origin has not yet been absolutely proved, however great the probability may be in favour of this view, and in any case it actually occupies a median position. The term "pineal sac," on the other hand, is not likely to lead to any confusion, and, while indicating the general character of the organ (at any rate in *Sphenodon*), commits us to no theory either as to its morphological interpretation or as to its function. It appears to me preferable to the term "parietal stalk," which I at one time used (DENDY, 1899, *b*).

The origin of the pineal sac cannot be considered apart from that of its fellow, the pineal eye, but we may conveniently deal with it in this place, though we shall have to return to it again when we come to discuss fully the evidence for and against the primitively paired nature of these two organs.

I have already shown in my memoir on the development of the pineal or parietal organs (1899, *b*) how at Stage K the primary parietal vesicle arises as an outgrowth from the roof of the fore-brain (sometimes, if not always, a little to the left of the middle line) before either the superior or posterior commissure has put in an appearance. This outgrowth has the form of a slightly flattened sac, with a constricted aperture on its ventral aspect, through which it communicates with the cavity of the brain; it lies wedged in between the brain-roof and the superficial epiblast, causing a prominent outward bulging of the latter, and at Stage L it projects both backwards and forwards above the brain-roof from its point of attachment, but already more forwards than backwards (fig. 29).

By the time Stage O is reached two vesicles have developed, one lying in front of the other. The anterior of the two at first communicates with the posterior,* while the latter communicates with the brain cavity (fig. 30). The anterior vesicle gives rise to the pineal eye and the posterior to the pineal sac. Very soon the eye vesicle becomes completely constricted off from the pineal sac (fig. 31), and in most cases it lies a little to the left of the latter, as I have shown in my earlier work. (In Embryo 32*a*, however, it appeared to lie slightly to the right of the pineal sac, but this embryo had lain many years in alcohol before it was examined, and may have been distorted by shrinkage.)

Exactly how the two pineal vesicles now present are related to the original single vesicle is by no means clear. The latter may have grown forward and constricted into two, which I now think the more probable explanation, or the pineal sac may have been formed as a second evagination of the brain-roof, involving the aperture of

* I was unable to demonstrate this communication in my earlier work. SCHAUINSLAND (1903) has since done so, and I have myself now found it in Embryo 32*a* (fig. 30).

the first. There can be no doubt that they actually lie one behind the other rather than side by side, but the tendency of the anterior one to lie a little to the left of the posterior is very strongly marked, and the fact that the primary vesicle also generally (?) originates on the left side of the middle line seems to me to indicate that it may possibly give rise only to the pineal eye, and that the pineal sac may be formed by a fresh evagination in the middle line.*

From its first appearance, at any rate as an independent structure, apart from the pineal eye, the pineal sac points forwards over the roof of the brain (fig. 31). It rapidly assumes a finger-like shape, and its aperture becomes constricted as the superior and posterior commissures develop in front of and behind it respectively (figs. 31, 33, 35, 45, 46). At the same time, the lumen disappears more or less completely from its proximal portion, and it remains connected with the brain-roof only by the pineal tract, which will be dealt with more fully when we come to discuss the right pineal nerve.

Up to about Stage R the wall of the pineal sac remains unfolded; although already the elongated sac itself has become strongly curved, following the curvature of the posterior wall of the dorsal sac, against which it is closely pressed. This condition is shown very clearly in fig. 15, Plate 12, of the memoir already referred to (DENDY, 1899, *b*). At Stage S the curvature of the pineal sac has become converted into a strongly-marked angulation, and the folding of its wall has commenced, as shown in fig. 45. The first conspicuous fold is formed, as might be expected, at the bend, and divides the entire pineal sac into proximal and distal portions, the cavity, however, still remaining continuous throughout, in spite of the appearance of discontinuity represented in the figure.

The pineal sac has now acquired its characteristic V-shaped form, with the proximal limb sloping upwards and backwards and the distal limb extending forwards between the roof of the dorsal sac and the forward extension of the supra-occipital cartilage (fig. 45, *S. O. C.*). The extent to which the distal limb extends forwards in the adult varies in different specimens. In *Sphenodon* II it reaches the external capsule of the pineal eye beneath the parietal plug (fig. 8). The folding of the wall of the pineal sac becomes greatly intensified in the adult and both limbs are involved therein, but the distal limb tapers off anteriorly into a narrow tube with comparatively unfolded walls (text-figs. 12, 13; fig. 8). The proximal limb tapers more abruptly to its ventral extremity, and the widest part of the sac is at the bend. The folding takes place in a very irregular manner, both transversely and longitudinally, as shown in text-figs. 12-16, but the cavity, though partially subdivided into numerous bays or diverticula, remains continuous throughout.

The proximal limb of the pineal sac becomes enveloped in the connective tissue of the *pia mater*, by which it is firmly attached to the posterior wall of the dorsal sac.

* Much light is thrown on this problem by Nowikoff's recent work, briefly discussed in the Postscript (p. 329).

The distal limb rests upon the roof of the dorsal sac posteriorly (text-figs. 12, 16) and upon the paraphysis more anteriorly (text-figs. 12-15), but it may project in front of the paraphysis between the inner and outer layers of the *dura mater* (fig. 8). The distal limb is everywhere to a greater or lesser extent surrounded by the *sinus longitudinalis*, which penetrates between the folds of the wall of the pineal sac in the form of innumerable irregular blood-spaces (text-fig. 17). The pineal sac is supplied with arterial blood by branches of the anterior and posterior pineal arteries, as will be described more fully in the section dealing with the blood-vessels of the pineal complex.

The histological structure of the wall of the pineal sac is very complicated, and, while differing entirely from that of the choroid plexus and paraphysis, agrees in essential particulars with that of the pineal eye, for in both cases the wall of the vesicle consists not only of sensory epithelial cells but also of neuroglia, ganglion-cells and nerve-fibres, and the fundamental structure and arrangement of these elements in the two cases are identical.

The only accounts hitherto published of the histology of the pineal sac in *Sphenodon* are, so far as I am aware, those of HOFFMANN (1890) and GISI (1907, p. 52). Both are, unfortunately, without illustrations; the latter is the more complete but it is so short that it may be quoted in full: "Die eigentliche Wand des Pinealorgans besteht aus brachypilösen Neurogliazellen mit kleinen, stark gefärbten Kernen. Flaschenförmige Epithelzellen, deren Kerne alle gegen das Lumen des Organs angeordnet sind, sitzen dazwischen. Unter diesen Epithelzellen, meist dicht dahinter, liegen in nervösem, feinstreifigem Fasergeflecht grosse Ganglienzellen mit blassen, kugligen und elliptischen Kernen. Ihnen eigen ist die Nervenfasern mit dem typisch konischen Ansatzglied. Die Epithelzellen enden gegen den Hohlraum mit feinen stäbchenförmigen Fortsätzen, an denen oft in grossen Klumpen ein feinkörniges Coagulum klebt. Ebenso wie in den Zellen der Wand ist im Innern des Organs vielfach ein wolkiges Secret abgeschieden. Kleine, stark gefärbte Zellkerne sitzen darin, ohne dass man die Struktur von Zellen erkennen könnte. Auch wenige blasse und grosskernige Zellfragmente lagern innerhalb der Secretwolken. An andern Orten sind Häufchen von Blutzellen, ohne dass eine Gefässmembran zu erkennen wäre, mit Secret vermischt. Wenige dunkle pigmentartige Ballen finden sich im Innern. Sie waren nur auf einzelnen Schnitten zu sehen. Dagegen liegen an mehreren Stellen riesengrosse, sphärische Elemente, deren Grundton schwach gelblich ist. Ihr Inhalt besteht, soweit das Mikroskop erkennen lässt, aus kleinen rundlich polyedrischen Teilen, die dunkel gekörnt sind."

It is clear from this brief description that GISI has recognised the essentially nervous character of the wall of the pineal sac and the main features of its histological structure; and I am glad to be able to confirm and amplify her description and supply the necessary illustrations.

Dealing first with the development, we find at a very early stage, one might almost

say from its first appearance, that the nuclei in the wall of the pineal sac are arranged in more than a single layer, while the wall has begun to thicken (figs. 30, 31). At Stage R, as I have shown in my earlier memoir (1899, *b*, fig. 21), the wall may have already become differentiated, at any rate distally, into two conspicuous layers, a thin outer layer with a single layer of nuclei, and a very much thicker inner one in which the very numerous nuclei are irregularly scattered. I pointed out also that in this respect the wall of the pineal sac exactly agrees with the developing retina of the pineal eye. I now find this apparently two-layered condition very strongly marked at Stage S, and recognisable throughout the whole length of the pineal sac, except perhaps in the most proximal portion, from which the lumen has by this time disappeared (figs. 45, 46). I say "apparently two-layered condition," because I have been able to demonstrate that, exactly as in the pineal eye, the two conspicuous nucleated layers are in reality separated by a much less readily recognisable layer of nerve-fibres, to the development of which, indeed, they owe their sharp distinction from one another. As I shall show in dealing with the development of the nerve of the pineal sac, this layer of nerve-fibres is already commencing to appear at Stage O (fig. 30, *l. n. f. s.*). As it develops, it separates the nuclei of the wall into two sets—a single outer layer and a multiple inner layer (fig. 46). The nuclei of the outer layer belong to neuroglia cells which become differentiated to form radial supporting fibres. Those of the inner layer belong to at least two kinds of cells, viz., the elongated epithelial (sensory) cells, which arrange themselves radially beneath the inner surface of the wall, and the ganglion-cells, which take up their position in the middle of the thickness of the wall, and from which doubtless the nerve-fibres actually grow out, though this latter point has not been observed.

We come now to my own observations on the histological structure of the wall of the pineal sac in the adult animal, which is illustrated in figs. 63–68. Outside the true wall we have first the highly vascular connective tissue of the *pia mater* (figs. 63–65, *p. m.*), in which also run bundles of nerve-fibres. The inner portion of the *pia* forms a kind of basement membrane (*b. m.*) on which rest the expanded ends of the radial neuroglia fibres, forming a *membrana limitans externa*, which is not, however, sharply defined.

The radial fibres (figs. 63–66, 68, *r. f.*) are very strongly developed, and evidently extend right through the entire thickness of the wall, though I have not been able to trace any individual fibre throughout. Their inner extremities are expanded to form a very delicate *membrana limitans interna* (fig. 65, *m. l. i.*) bounding the lumen of the pineal sac. Their nuclei vary much in position; sometimes they are placed near their outer extremities (fig. 65), sometimes more in the middle (fig. 68, *n. r. f.*), and sometimes apparently at their extreme inner ends, even projecting slightly beyond the surface (figs. 64, 66, *n. r. f. ?*). I am not quite sure, however, whether these last-mentioned nuclei really belong to radial fibres, though I do not know what

else to make of them, unless they belong to secreting cells. It will be seen from the illustrations that the nuclei of the radial fibres may be distinguished from those of the epithelial (sense) cells and those of the ganglion cells by their smaller size. Sometimes they appear to have a small nucleolus. The radial fibres may be compared to the Müller's fibres in the retina of the lateral eye, and like them are doubtless supporting structures.

Scattered between the inner ends of the radial fibres we find numerous elongated, spindle-shaped ependymal cells, which, from their resemblance to the sense-cells of the pineal eye, and from the presence beneath them of a well-developed layer of ganglion-cells and nerve-fibres, are to be interpreted as sense-cells. These cells are marked *s. c.* in figs. 64–67. The conspicuous oval nucleus lies in the thickest part of the cell at a considerable distance from either extremity. In addition to minute scattered chromatin granules it contains a small but conspicuous nucleolus. The rod-like inner extremity of the cell-body projects for a very short distance into the cavity of the pineal sac, while the outer extremity tapers away into the layer of nerve-fibres. STUDNIČKA (1905) has shown that ependymal cells of this type, presumably sensory, are characteristic of the pineal sac of many widely separated Vertebrates.

In the middle of the thickness of the wall lies the layer of ganglion-cells and nerve-fibres (figs. 64–68, *g. c., l. n. f. s.*). The ganglion-cells may be recognised by their large oval nuclei, more rounded, however, than those of the sense-cells, which they resemble in the possession of a small but conspicuous nucleolus and numerous minute scattered chromatin granules. The cytoplasm of the ganglion-cells is finely granular, and appears to be most frequently uni- or bi-polar, though one can never be certain that some of the processes have not been cut off. That these cells are, as HOFFMANN and GISI state, really ganglion-cells, admits, I think, of no serious question. The numerous nerve-fibres run in various directions. They are connected partly with branches of the nerve of the pineal eye (figs. 63, 64, *b. n. p. e.*) and partly with the nerve of the pineal sac itself (fig. 60, *T. P.*), as I shall describe later on.

The cavity of the pineal sac is probably filled during life with lymph. My sections show that it contains a considerable number of cells, which I take to be a variety of leucocyte, though they differ somewhat from the leucocytes which occur in the blood-vessels. The latter (fig. 65, *leuc.*, and fig. 71) are almost spherical or amœboid cells with highly granular cytoplasm and usually two small nuclei. The former (fig. 69) are considerably larger, more uniformly rounded in shape, and have a single, very eccentrically placed nucleus with scattered chromatin granules, while the cytoplasm is less coarsely granular and has a characteristic brownish colour, which I do not think is due to the staining (borax carmine followed by picro-indigo-carmine).* These brown cells sometimes occur in groups in the cavity of the pineal

* In a specimen stained with hæmatoxylin (Sphenodon II) they have taken the stain so deeply that it is impossible to say what was their original colour.

sac (fig. 9, *leuc.*), but this grouping is probably, at any rate to a large extent, accidental. Somewhat similar cells, except for their smaller size and the absence of the brownish colour, occur abundantly in the loose connective tissue around the longitudinal sinus just above the pineal sac (fig. 70). GISI's description of the cells which she found in the cavity of the pineal sac (*vide supra*) is not detailed enough to admit of any satisfactory comparison. I have not been able to recognise any pigment-cells in this situation.

Here and there traces may be observed in the cavity of the pineal sac of a reticulum somewhat resembling that found in the pineal eye, especially at the tip of the organ in *Sphenodon* II (fig. 9), but it is relatively much less strongly developed and more suggestive of mere coagulum. There is no nucleated network, such as is formed in connection with the epithelium of the paraphysis and choroid plexuses.

As a general rule, there appears to be no pigment in the walls of the pineal sac. I have, however, already described the occurrence of pigment near the distal extremity of the organ in an embryo of Stage R (DENDY, 1899, *b*), and I have now to note a similar occurrence in the adult (*Sphenodon* II). In this specimen, as I have already pointed out, the distal extremity of the pineal sac extends unusually far forwards, so that it lies close to the pineal eye beneath the transparent parietal plug (fig. 8). A small and relatively thin-walled, well-rounded diverticulum of the wall of the sac has been developed at the apex, as shown more in detail in fig. 9. Unfortunately, the sections are very thick in this case, and the material is not in the best condition for histological investigation, but it is obvious at once that the wall of this diverticulum is deeply pigmented, and exhibits at any rate a general resemblance to the retina of the pineal eye, the pigment taking the form of minute granules arranged in dense radial streaks.

This occurrence appears to me to be of great interest, as supporting my view that the structure of the pineal sac is fundamentally identical with that of the pineal eye, and as showing that it only requires the stimulus of light to complete the resemblance by the acquisition of pigment. The diverticulum is probably comparable to the "Nebenparietalorgane" described by LEYDIG (1891) in an embryo of *Anguis fragilis*, but it is evidently of a totally different nature from the "accessory vesicle" which I have previously described (1899, *b*) in an advanced embryo of *Sphenodon*, and which probably has nothing whatever to do with the pineal sac.

It is noteworthy that the pigmented outgrowth of the pineal sac in *Sphenodon* II lies distinctly on the right-hand side of the pineal eye.

As to the function of the reptilian pineal sac we know no more than we do of that of the so-called pineal gland of mammals, with which I believe it to be more or less homologous. Its structure, however, undoubtedly points to a sensory rather than to a secretory function, though possibly the two may be combined. The position and structure of the organ, together, preclude us from comparing it with any other sense-organs with which we are acquainted, and it does not seem likely

that it is concerned with any sensory function as yet known to us. It may, however, be capable of receiving and transmitting to the brain stimuli of which we know nothing, and which we ourselves are quite incapable of appreciating, for the mammalian pineal gland is probably too degenerate in structure to be of any value as a sense-organ. Until some experimental method of testing its function can be discovered—which, unfortunately, does not seem very likely at present—we shall probably remain as ignorant thereof as most people are of the function of the wireless telegraphy apparatus which may be seen hung aloft in the rigging of a modern man-of-war.

D. *The Pineal Eye.*

a. Personal Observations.

(1) *Position and Relations.*—The pineal or parietal eye in *Sphenodon* is, as I have already shown (DENDY, 1899, *b*), the left-hand member of the original pair of pineal outgrowths. I have found it well developed, and exhibiting but little variation in structure, in all the six adult specimens in which I have looked for it, and in all the numerous sufficiently advanced embryos which I have examined. I am therefore inclined to think that GISI (1907) must be in error in her description of an adult specimen in which the pineal eye was apparently absent, especially as she found the left pineal nerve (“Parietalnerv”) to be well developed in the same specimen.

The adult pineal eye lies in the lower part of the parietal foramen beneath a mass of more or less transparent connective tissue which I (1907, *a*) have termed in the case of the lamprey the “parietal plug.” This parietal plug will be described later; it is sufficient now to state that it practically fills the parietal foramen and that, whereas its outer surface is strongly convex, its inner surface is concave. In this concavity lies the pineal eye, surrounded by its internal and external capsules, as shown in figs. 1, 3 and 7. It is possible, as I have already pointed out, to dissect the parietal plug, with the eye, clean out from the parietal foramen, and then when it is examined as a transparent object (*e.g.*, in cedar oil without staining) it exhibits the appearance shown in fig. 6.

The upper surface of the pineal eye (*i.e.*, the outer surface of the lens) is more or less closely pressed against the lower surface of the parietal plug, and the outer capsule of the eye here merges completely into the latter (figs. 2, 3). Elsewhere, however, the outer capsule lies at a considerable distance from the inner capsule which immediately invests the eye, and the intervening space is filled with a loose network of connective tissue. In this tissue run the branches of the anterior pineal artery, without entering the eye itself, while immediately outside the external capsule lie irregular branches of the *sinus longitudinalis* (figs. 3, 7). Both outer and inner capsules are, of course, composed of connective tissue, and are probably to be regarded as parts of the *dura mater*. The double capsule and the eye itself are both drawn

out, as it were, downwards and backwards, the capsule extending for some distance around the nerve as shown in fig. 3.

(2) *Shape and Size*.—The characteristic shape of the adult pineal eye is obliquely conical, the base of the cone, represented by the outer surface of the lens, being slightly convex and turned upwards and more or less forwards, and the apex, to which the nerve is attached, pointing downwards and backwards. There is no doubt a certain amount of individual variation in shape, but the variation seen in sections (*cf.* figs. 2 and 3) is probably in most cases more apparent than real, depending chiefly on the plane of the sections. The longer diameter of the eye measures about 0.53 mm. (*Sphenodon* V, fig. 3). This is the longitudinal diameter from the outer surface of the lens to the point of entrance of the nerve; the maximum diameter at right angles to this is very little less.

(3) *General Structure and Development*.—The most striking feature of the pineal eye, as compared with the ordinary vertebrate eye, is, of course, that it consists always of a simple vesicle which never becomes cupped by invagination. The outwardly turned wall of this vesicle forms the lens, and the remainder the retina. The apparent formation of a double optic cup, sometimes seen in advanced embryos, is due simply to the development of a shrinkage cavity in the zone of nerve-fibres which tends to separate the retina into two layers. I have already (1899, *b*) insisted upon the absence of a true optic cup, comparable to that of the lateral eyes, in the pineal eye, but it seems necessary to do so again as I have been made responsible for a somewhat misleading figure in the latest edition of WIEDERSHEIM'S 'Comparative Anatomy.'

The separation between the lens and the retina is remarkably sharply defined in the adult, considering that both are formed from an originally continuous and uninterrupted layer, the wall of the optic vesicle. The distinction between the two is emphasised by the fact that the retina gradually thins out to almost a sharp edge as it approaches the lens, and this edge meets a somewhat similar edge which marks the junction between the outer and inner surfaces of the lens. The cavity of the optic vesicle has the form of a deep cup, and the lens may be compared to a stopper placed in its mouth (figs. 2, 3, 7).

The differentiation of the wall of the optic vesicle into lens and retina takes place at a remarkably early stage of development. It may commence even before the two pineal outgrowths have separated from one another, which occurs at about Stage O (fig. 30). At this stage and immediately after the separation of the two outgrowths (fig. 31) the optic vesicle is a somewhat flattened sac lying between the roof of the brain and the superficial epiblast, between which it appears to be compressed, although a little mesoblast is already present between the superficial epiblast and the developing lens. Both upper and lower walls of the vesicle are thickening, the upper to form the lens, and the lower the retina. The retinal portion, however, encroaches slightly upon the upper part of the wall, thereby restricting

the area of the lens. Between the two the wall of the vesicle remains unthickened, or even thins out, forming already at Stage O a sharp line of demarcation (fig. 31).

By the time Stage P is reached a considerable amount of connective tissue has grown in between the retina and the roof of the brain (dorsal sac), but the lens still remains very close to the epiblast (fig. 32). As if released from compression, the optic vesicle has begun to deepen downwards. At the same time it is pushed forwards, as if by the growth of the finger-like pineal sac behind it. It is already attached to the brain-roof by the left pineal nerve (figs. 32, 34, *n. p. e.*), and it is probably the tension of this nerve which causes the optic vesicle to assume its characteristic obliquely conical form, with backwardly directed apex. This form may be already completely acquired at Stage Q, by which time also the differentiation between lens and retina may be fully expressed (fig. 34). At Stage Q also the dermal mesoblast, between the lens and the superficial epiblast, has begun to thicken (fig. 34), and at Stage S this has further differentiated to form the parietal plug (fig. 45, *P. P.*). The extent to which the pineal eye becomes separated from the tip of the pineal sac (right pineal organ) varies greatly in different cases. Sometimes the separation is already wide at Stage S (fig. 45). In other cases the tip of the pineal sac may extend forwards as far as the capsule of the eye, even in the adult (*Sphenodon* II, fig. 8), as I have already had occasion to point out.

(4) *The Retina: (a) General Structure and Development.*—The histological differentiation of the retina commences at a very early stage, and the first recognisable feature thereof appears to be the development, at about Stage O, of a zone of delicate nerve-fibres (figs. 30, 31, *l. n. f. e.*), which presently comes to divide the ventral wall of the optic vesicle into two layers. At first these two layers may be of nearly equal thickness, or the outer may be thicker than the inner, as shown in fig. 31, but by the time Stage Q is reached the numerous nuclei which lie in the retina have arranged themselves in a single layer outside the zone of nerve-fibres and in a multiple layer inside it, and we thus arrive at the condition superficially resembling a double-layered optic cup, the inner layer of which is very much thicker than the outer, as shown in fig. 34. This is a very characteristic stage in the development of the pineal eye.

The nuclei of the outer layer belong, chiefly at any rate, to the supporting elements of the retina, the radial fibres. Those of the inner layer belong to the sense-cells, and doubtless also to the ganglion-cells, from which we must suppose the nerve-fibres to have grown out. Pigment first appears at Stage R, in the inner layer of the retina, in the form of very small granules arranged in radiating lines (fig. 26).

In the adult retina we find the nuclei of the ganglion-cells lying in the nerve-fibre zone and nearer to the nuclei of the radial fibres than to those of the sense-cells, in fact they have begun to assume this position already at Stage R (fig. 26, *n. g. c.*). We can now, therefore, distinguish three layers of nuclei: an outer layer belonging to the radial fibres, an inner layer belonging to the sense-cells, and a middle layer

belonging to the ganglion-cells. These are the only three kinds of cells which occur in the retina of the pineal eye, if we except the wandering pigment-cells which seem to have the power of passing into the retina from the surrounding connective tissue.

It is hardly necessary to point out again that the histological structure of the retina is thus fundamentally identical with that of the wall of the pineal sac.

(β) *The Radial Fibres.*—These elements constitute the supporting framework of the retina, and are thus comparable, as in the case of the pineal sac, to the Müller's fibres of the lateral eye. They are greatly elongated, and no doubt extend from the outer to the inner surface of the retina, though, owing to their irregular shape and to the large amount of pigment developed in the inner layer of the retina, I have been unable to trace any individual fibre right through. The distinctness with which they can be recognised depends a good deal upon the mode of preparation of the material. They are most distinct when separated from one another by a little shrinkage, as represented in fig. 5. Their outer ends are expanded, and abut against one another so as to form a kind of *membrana limitans externa*, which lies closely against the internal capsule of the eye (fig. 18, *m. l. e.*), but may shrink away from it in the course of preparation. In these more or less conical outer ends lie the nuclei, and when, as frequently happens, the section passes obliquely instead of vertically through the retina, the outer portions of the radial fibres, with the nuclei, are cut off from the inner portions, and appear as a distinct outer layer of conical cells. This is shown to some extent in fig. 4.

The inner ends of the radial fibres are not nearly so obvious as the outer ones, but I think there can be no reasonable doubt that they meet together to form the internal limiting membrane, which is itself quite clearly recognisable in sections (figs. 4, 5, 12-14, *m. l. i.*). This membrane has frequently a somewhat beaded appearance in section, as shown in several of the figures, due apparently to variations in thickness giving it a reticulate character, and the manner in which it tends to break up under shrinkage, as shown in fig. 5, appears to me strongly to support the conclusion that it is formed from the united inner extremities of the radial fibres.

The nuclei of the radial fibres (*n. r. f.*) are well defined, large, and oval in shape, with a distinct nuclear membrane, and numerous minute chromatin granules scattered in the nuclear reticulum. They frequently show a single small, sharply defined, deeply staining nucleolus (figs. 4, 16), especially in material fixed with Flemming's solution and stained with hæmatoxylin.

The cytoplasm of the radial fibres takes the usual plasma stains, assuming a red colour with eosin (fig. 4), and bluish or greenish with picro-indigo-carmin (fig. 5), and the same statement applies to the limiting membranes formed by their expanded ends.

(γ) *The Sense-Cells.*—The sense-cells (*s. c.*) lie radially between the inner ends of the radial supporting fibres (figs. 4, 5, 11-14). It is very difficult to get a satisfactory view of them, on account of the large amount of pigment in this part of the

retina. In thin sections, however ($7\ \mu$), it is sometimes possible to find a portion of the retina comparatively free from pigment, especially near the point of entrance of the optic nerve, in which the shape of the sense-cells can be quite distinctly seen.

They are slender, elongated, fusiform cells, with one end projecting for a short distance beyond the limiting membrane into the cavity of the eye, and the other tapering off into a process, which loses itself in the layer of nerve-fibres, as shown in fig. 11. The cytoplasm is very slightly granular or almost homogeneous, and takes the usual plasma stains, the body of the cell showing very distinctly, for example, in sections stained with eosin (fig. 4). It contains no pigment. The large oval nucleus (*n. s. c.*) lies in the thickest portion of the cell, nearer to its outer* than to its inner end, *i.e.* away from the cavity of the eye. In shape, size, and minute structure it closely resembles the nucleus of a radial fibre, though perhaps on the average a little larger. The nuclear membrane is well defined; there are numerous small chromatin granules scattered in the nuclear reticulum, and in specimens stained with hæmatoxylin, especially after fixation with Flemming's solution, there is usually a very distinct but small nucleolus (fig. 12).

The sense-cells, or at any rate their inner ends, are separated from one another for the most part by considerable intervals, but sometimes (in *Sphenodon* I) show a tendency to group themselves in twos and threes. This is well shown in figs. 14 and 15, the latter representing a tangential section, stained with hæmatoxylin and eosin, in which the inner ends of the sense-cells are cut across and appear as deeply-stained discs (*t. s. s. c.*), the diameter of which varies according to the distance of the particular section from the nucleus.

In view of the comparison of these cells with the corresponding cells of the lamprey and with the visual cells of various Invertebrates, especial interest attaches to the structure of their innermost extremities. That these project for a short distance into the cavity of the eye has now been repeatedly observed in the pineal eye of various Vertebrates, and in *Sphenodon* these projecting ends form a conspicuous feature even under a low power of the microscope (figs. 2, 3). For a long time I supposed that the fibres of the vitreous reticulum were attached directly to the inner ends of the sense-cells, as they often appear to be in ordinary preparations, although the connection is usually broken through by the shrinkage of the vitreous body in the course of preparation, as shown in figs. 2 and 3. Careful study of my most successful sections under a $1/12$ inch oil immersion lens, however, has led me to adopt a somewhat different interpretation of the appearances, which may be best explained by reference to figs. 12 and 13.

Fig. 13 represents a small portion of a section of the pineal eye of *Sphenodon* I, which was fixed in Zenker's fluid, stained in bulk with Ehrlich's hæmatoxylin, and counterstained on the slide with picro-indigo-carmin. A number of little cap-

* It would be more accurate to say "apparent outer end," for the process into which the sense-cell tapers off is usually cut off short in sections.

shaped structures (*cap*) are seen projecting from the internal limiting membrane into the cavity of the eye, and to the apex of each of these is attached a thread of the vitreous reticulum (*f. ret.*). Sometimes, as shown on the left-hand side of the figure, the base of the cap appears quite distinctly as a well-defined circular aperture in the internal limiting membrane. Through this aperture the inner extremity of a sense-cell projects into the cap, but whether it lies freely in the latter or is attached to its apex internally, it is impossible to decide from these sections. In tangential sections these little caps can also be recognised as distinct structures (fig. 15, *cap*).

My sections of the pineal eye of *Sphenodon* A show the connection of the vitreous reticulum with the retina better than any others, the shrinkage having taken place in such a way as to rupture the reticulum in the middle, and leave the connections with the retina for the most part intact. This material was fixed in Flemming's solution, and, in spite of decalcification, the sections are in some ways the best I possess. Had I discovered in time that it was possible to dissect out the entire parietal plug with the pineal eye from the parietal foramen, and thus avoid the necessity for decalcification, I should doubtless have been able to obtain even better results, especially as regards the thickness of the sections, and this is the method which I most strongly recommend to future workers. Fig. 12 represents a small part of one of these sections, showing the junction of the retina with the vitreous reticulum (*ret.*). The little caps projecting from the internal limiting membrane are again very distinctly seen. The fibres of the vitreous reticulum with which they are connected are a good deal thicker than in the previous case, being probably less shrunken, and the junction of these fibres with the apices of the caps is marked by a rather darkly staining band. The staining of this section (hæmatoxylin) is not very suitable for differentiating the sense-cells, but pretty clear indications of their inner ends can sometimes be made out inside the caps.

It appears, in short, that the inner extremity of each sense-cell is covered by a little cap (derived presumably from the internal limiting membrane) in which I think it probably lies freely, though this point is by no means certain, and it is the caps rather than the extremities of the sense-cells themselves which are connected with the network of fibres in the vitreous body. The apex of the sense-cell itself, so far as I have been able to make out, exhibits no sort of special differentiation, nothing comparable to the "rods" which occur in connection with the visual cells of many Invertebrates.

(δ) *The Ganglion-Cells and Nerve-Fibres.*—The ganglion-cells are quite abundant, though considerably less numerous than either the sense-cells or the radial fibres. They lie, as already stated, in the outer part of the nervous layer of the retina, just inside the layer of nuclei belonging to the radial fibres (figs. 4, 16, 17, *g. c.*). They are readily recognisable on account of their large and almost spherical nuclei, and the conspicuous shrinkage cavity by which they are usually surrounded.

The amount of cytoplasm in proportion to the size of the nucleus is very small, and it appears to be drawn out into one thick process which extends into the layer of nerve-fibres, as shown in fig. 17. To what extent other processes may be present, but cut off in the sections, I am unable to say. The cytoplasm is finely granular. The nucleus has a very distinct membrane, numerous minute chromatin granules scattered in the nuclear reticulum, and in the best preserved sections a sharply defined nucleolus (fig. 17). In fact, the structure of the nucleus is closely similar in all three categories of cells of which the retina is composed.

The nerve-fibres are closely interwoven with one another to form a "molecular" layer (fig. 4, etc., *l. n. f. e.*), connected with the nerve itself at a single point at the back of the retina (fig. 3). Histologically, this layer differs from the nerve itself only in the entire absence of the elongated nuclei which occur in the latter, and which doubtless belong to supporting or nutrient connective-tissue cells.

(ϵ) *The Pigment and its Origin.*—The amount of pigment present in the adult pineal eye is very large and it is practically confined to the retina, where it occurs chiefly in the inner portion, between the sense-cells, but also, to a varying extent, between the outer ends of the radial fibres. It is most abundant, in both the inner and outer layers of the retina, near the margin of the retinal cup, close to where it joins the lens, and gradually diminishes towards the bottom of the cup near the point of entrance of the nerve (figs. 2, 3). The lens is almost, if not quite, free from pigment. The vitreous body also usually contains extremely little, but in *Sphenodon* II it contains a very considerable amount, aggregated in balls.

The pigment takes the form of minute, usually more or less spherical granules, individually of a light brown colour, but very dark when massed together. Their size varies considerably, ranging up to about 0.0014 mm. in diameter. The smaller ones are relatively more abundant in the innermost part of the retina next to the internal limiting membrane, where they tend to assume a rod-like appearance with a length of only about 0.0012 mm., so that they are actually very much smaller than most of those which are more deeply situated in the retina (fig. 15). As I have already stated, the pigment first appears in the retina at Stage R, and at this stage consists solely of very minute granules, neither larger granules nor pigment balls being present (fig. 26).

Concerning the chemical nature of this pigment I have nothing to say, except that it is insoluble or only partially soluble in any of the reagents employed in making the preparations, including the strong acids used for decalcification.

It has hitherto been generally believed that the pigment is associated with special cells of the retina, but very contradictory views have been held on this point, for while BALDWIN SPENCER believed it to be associated with the sense-cells, NOWIKOFF (1907) has lately maintained that it lies actually inside the radial fibres (in *Anguis* and *Lacerta*). I do not think that either of these views is correct, but rather that

the pigment lies, at any rate for the most part, between the various retinal elements. In the inner part of the retina it is found in dense masses exhibiting a distinctly radial arrangement, and frequently separated from one another by sharp lines of demarcation, as shown in figs. 4, 5, 11-14. This arrangement certainly suggests that it is here lodged in the inner ends of the radial fibres, but the boundaries between these are so irregular and ill-defined that the pigment might just as well be supposed to lie between them, and in tangential sections (fig. 15) it is seen to lie, not in separate blocks, but forming an irregular network between the sense-cells.

When we come to examine the arrangement of the pigment in the outer part of the retina this view is considerably strengthened, for here the pigment occurs chiefly in large rounded masses or balls, which are sometimes distinctly nucleated (figs. 4, 18, *Pig. C.*), while a few scattered granules are seen apparently streaming along the radial fibres, as shown in figs. 5, 18. These look as if they had been derived from the breaking up of the large pigment balls which lie between the outer ends of the radial fibres.

It is of great interest to notice that similar pigment balls may occur in the vitreous body (*Sphenodon* II) and also, sometimes in great abundance (*e.g.* *Sphenodon* II), outside the pineal eye altogether, in the gelatinous connective tissue which fills the space between the inner and outer capsules of the eye (figs. 2, 4, 7, 8, 10, 21, *Pig. C.*). Amongst these latter some show a distinct nucleus (figs. 4, 21), and we also find other nucleated cells containing similar pigment in very much smaller quantities, as shown in figs. 20, 21. These nucleated pigment balls are doubtless wandering cells and I think there can be no question that they have the power of passing through the internal capsule of the eye into the retina. Indeed fig. 19 represents a pigment ball actually lying in the internal capsule, though whether the nucleus which is associated with it in this case actually belongs to the pigment-cell or to the connective tissue of the capsule is an open question.

Fig. 18 again shows a pigment ball with an enclosed nucleus, which seems to have just passed through the internal capsule and external limiting membrane, for these exhibit distinct signs of disorganisation in its immediate neighbourhood. This is perhaps the strongest evidence I can adduce for the view that the pigment-cells migrate in to the retina and not out from it, and that they then usually discharge their pigment-granules, which stream inwards towards the cavity of the eye, following the lines of the radially arranged elements, and probably breaking up to form the smaller rod-shaped granules. NOWIKOFF (1907) has shown experimentally that in *Anguis* and *Lacerta* the pigment-granules actually have the power of streaming backwards and forwards in the retina according to the intensity of the light, as is, of course, the nature of pigment-granules.

Occasionally, as already indicated, pigment balls are even met with in the vitreous body, and on at least one occasion I have found a nucleus in connection with one of these also, but the vitreous body always contains a good many nuclei, and it is

possible that the pigment-granules had become secondarily associated with one of these. On the other hand it is conceivable that some of the nuclei in the vitreous body are really those of wandering cells which have for the most part given up their pigment in the retina and then passed on into the cavity of the eye, while occasionally one may pass right through the retina into the vitreous body without giving up its pigment.

Occasionally, but very rarely, a pigment ball may find its way round to the front of the eye, between the lens and the parietal plug, but I have only seen one in this situation two or three times (fig. 28, *Pig.*).

The evidence before us, however, is perhaps not sufficient to enable us to determine with absolute certainty in which direction the wandering pigment-cells migrate; and we are equally unable to answer with certainty the question—where is the pigment first formed? If the pigment-cells are migrating towards the eye, as I believe, the pigment must be derived from some source outside it; and in this connection it is interesting to note the occurrence in the *dura mater*, in the immediate neighbourhood of the pineal eye, of numerous gigantic, much branched pigment-cells filled with pigment-granules similar to those which occur in the pineal eye. These branched cells all lie outside the outer capsule of the eye, as represented in fig. 10, and they are easily visible scattered around the parietal foramen when the inner aspect of the cranial roof is examined with a pocket-lens. These cells may possibly be the source of the pineal eye pigment; but, on the other hand, they may themselves derive their pigment from the pineal eye, and in either case the pigmented wandering cells may serve as go-betweens. Similar large, stellate, branched pigment-cells, however, may be found in the *dura mater* in situations far removed from the pineal eye, and I have even seen them in the neighbourhood of the infundibulum, while the fact that such cells also occur in the choroid coat of the lateral eye is particularly significant in this connection.

In the case of the ordinary (lateral) Vertebrate eye it is, I think, generally believed that the pigment originates *in situ* in the pigment epithelium. If so, we should naturally expect a similar origin for the pigment of the pineal eye, and perhaps the fact that pigment may appear in the apex of the pineal sac when the latter extends forwards into the light (figs. 8, 9) tends at first sight to confirm this expectation. On the other hand, the development of the pigment cannot be entirely dependent on the presence of light, for it appears in the embryo, both in the pineal eye and in the pineal sac, long before hatching, while the egg is still buried in the nest. Moreover, the fact that wandering pigment-cells occur both in the cavity of the eye (vitreous body) and outside the eye altogether, as well as in the retina, indicates that these cells may pass right through the retina in one direction or the other.

I have also shown in my earlier account of the development of the pineal organs (DENDY, 1899, *b*) that at Stage R pigment granules, similar to those found in the pineal eye and sac, may occur in the corpuscles in the blood-vessels which lie between

the paraphysial tubules just (at this stage) beneath the pineal eye. This fact seems to me to suggest that the pigment is migrating towards the pineal eye, for we can hardly suppose that there is sufficient in the latter to require carrying away at this early stage in its development; indeed, it has only just begun to make its appearance in the retina.

In two very interesting papers (BERNARD, 1896, *a*, *b*) dealing with the origin of the sense of sight and the possible derivation of the Vertebrate eyes, both pineal and lateral, from the skin, published as far back as 1896, H. M. BERNARD has already expressed the view that the pigment-granules migrate into the eye from the surrounding tissues. This migration in the case of the lateral eyes is greatly obscured by secondary complications in the structure of the eye, but in the case of the pineal eye BERNARD (1896, *b*) observes: "I would call attention to SPENCER'S figures, a study of which leaves no doubt whatever that the pigmented cells are streaming from the connective tissue capsule round the eye through the retina, just as in the rest of the skin they stream out from the cutis through the palisade layer of the epidermis. In the series of sections of Hatteria, kindly lent me by my friend, Mr. MARTIN WOODWARD, in addition to the pigmented cells, there are others making their way alike through the retina and the palisade layer of the epidermis. These are cells containing enormous vacuoles which force the nuclei to one side. On reaching the horny layers these cells flatten out, and their vacuoles form flat spaces which give the cuticle a sort of false lamination."

I have seen nothing comparable to the large vacuolated cells in the pineal eye in my own preparations of Sphenodon (Hatteria), nor does the situation of the pineal eye favour a direct comparison with the skin in this respect, but as regards the pigment I think that my observations on the whole tend to support BERNARD'S views. This pigment is further supposed, on reaching the cavity of the pineal eye, originally to have become clarified and given rise to the vitreous body, but in the degenerate pineal eyes of to-day it appears "usually to escape into the cavity of the eye, in some cases at least unaltered" (BERNARD, 1896, *a*).

I have made a careful examination of the pigment of the lateral eyes of Sphenodon from this point of view, and it seems worth while to compare it with that of the pineal eye. In the lateral eye there are two quite distinct kinds of pigment-granules:

(1) In the choroid proper we find branched pigment-cells filled with more or less spherical granules closely resembling in shape, size and colour the great majority of those found in the retina of the pineal eye as well as in the wandering pigment-cells in the capsule and in the adjacent branched pigment-cells of the *dura mater*, with which latter the pigment-cells of the choroid are closely comparable.

(2) In the pigment epithelium of the retina, immediately adjacent to the layer of rods and cones, we find slender pigment rods of a similar brown colour, and about 0.00245 mm. in length. I am inclined to compare these with the shorter rod-like

granules found in the innermost portion of the retina of the pineal eye, and I believe that in both cases the rods are in some way derived from the more or less spherical granules which lie externally to them.

The parallelism between the lateral and pineal eyes with regard to the pigment is very interesting, and seems to me to support BERNARD'S views on the subject. The difference between the two consists in the fact that in the lateral eye the spherical granules do not appear to penetrate (as such) into the retina at all, while in the pineal eye they do, and in the latter the spherical and rod-shaped granules cannot be sharply separated into two categories and the rods are much less elongated; indeed the shortness of the rod-like granules in the pineal eye suggests that they may really be flattened discs seen edge on rather than true rods.

I shall have to return to the question of the pigment later on in discussing how far the pineal eye of *Sphenodon* can really be considered as degenerate.

(ζ) *Accessory Cavities in the Retina.*—I have already had occasion to observe that the pigment tends to accumulate to an unusual extent around the margin of the retinal cup. It does so both in the inner and outer layers of the retina, being radially arranged as usual in the inner layer, but in the outer layer occurring in irregular masses. Not infrequently a larger or smaller cavity makes its appearance in one or more of these masses, and around this cavity the pigment becomes radially arranged as it does around the principal cavity of the eye, but of course on a much smaller scale.

The best example which I have seen of this is in *Sphenodon* V. Here, even when the entire parietal plug with the pineal eye was examined as a solid transparent object in cedar oil, unstained, an accessory cavity surrounded by pigment was clearly recognisable under a low magnifying power in the anterior wall of the eye, not far from the margin of the lens (fig. 6), and so strongly developed was it in this case that the shape of the eye was considerably distorted by its presence. The appearance of this accessory cavity in section is shown in fig. 3. It is completely surrounded by pigment arranged in short radiating masses, but less strongly developed on its inner aspect, where there is less room for it owing to the presence of the radiating pigment masses in the inner layer of the retina, from which those of the accessory cavity keep quite distinct. It contains the remains of a vitreous body which stains blue with picro-indigo-carmin like that of the main cavity. I have not, however, been able to detect any sense-cells in the wall. Several much smaller accessory cavities occur both in the neighbourhood of this comparatively large one and also near the opposite (posterior) margin of the retinal cup.

I have observed similar small accessory cavities in corresponding positions in *Sphenodon* II, and there are indications of one or more in *Sphenodon* III, but in the latter case the sections are badly broken and not much is to be made out of them in this respect. *Sphenodon* A, *Sphenodon* I and *Sphenodon* VI, on the other hand, have not developed any accessory cavities, though they all exhibit the same tendency

towards the accumulation of pigment in irregular masses in the outer layer of the retina near the margin of the retinal cup. The development of accessory cavities is therefore doubtless to be regarded as an abnormality rather than as a constant feature of the pineal eye.

(5) *The Lens*.—The structure of the lens of the pineal eye in *Sphenodon* is by no means so simple as it is usually represented to be, and can be properly understood only by reference to its development.

We have already seen that, even so early as Stage O, the outer portion of the wall of the optic vesicle has begun to thicken and to be constricted off from the inner portion (fig. 30). At first there is unbroken continuity between the lens and retina thus differentiated, but very soon a sharp cleavage takes place between the two (figs. 31 and 32). This cleavage cuts out a circular piece, the lens, from the wall of the optic vesicle, and this piece henceforth develops quite independently of the retina, though remaining in contact with it all round its edge.

Almost from the first a differentiation may be observed amongst the rapidly increasing nuclei in the lens, and this differentiation is very clearly recognisable in the section of Embryo 37*a* (Stage O-P) represented in fig. 22. It will be seen that the great majority of the nuclei have acquired an oval form and arranged themselves with their long axes at right angles to the surfaces of the developing lens. They are much crowded and arranged in several irregular layers, and the boundaries separating the cells to which they belong are sufficiently distinct to show that the cells also are arranged at right angles to the surfaces of the lens, though even at this early stage I have not found it possible to trace any particular cell right through from one surface to the other. The lens has now become distinctly bi-convex, and the consequence is that the cell boundaries curve inwards towards the middle of the lens in the manner already well known.

The unthickened margin of the lens, however, contains a number of nuclei of more rounded form and quite irregularly arranged. I regard these as belonging to cells which have not yet become differentiated in the characteristic manner, and which form what we may term the "marginal zone" of the lens (figs. 22-26, *m. z. l.*). This marginal zone forms a more or less conspicuous feature of the developing lens right up to Stage S (inclusive), but I have not been able to recognise it with certainty in the adult. In Embryo 142 (Stage R) some of the nuclei of the marginal zone are undergoing mitosis, a late stage of which is represented on the right side of fig. 24 (*m. f.*). I therefore conclude that the marginal zone is a zone of specially active growth, from which cells pass inwards towards the centre of the lens, where they elongate and otherwise undergo the typical differentiation of lens-cells. By the elongation and possibly also by the further multiplication of these cells in the middle of the lens, the rapid increase in the thickness of the latter is brought about. The thickening takes place in such a way that while the outer surface of the lens remains relatively feebly convex throughout life, the inner surface comes to project more and

more into the cavity of the eye. In the meantime the surface of contact between the lens and the retina becomes reduced to a narrow ring around the margin of the lens, the margin itself becoming more and more prominent as development goes on. Fig. 3 shows what I take to be approximately the true shape of the lens in the adult as seen in sagittal section. It will be seen that the optic axis of the lens is now about equal in length to its greatest transverse diameter, while the inner end has a characteristic truncated appearance.

Of course, the actual appearances presented in sections differ very much according to the plane of cutting. Fig. 24, for example, obviously passes to one side of the optic axis, so that the marginal zone appears unduly wide in proportion to the central mass with elongated nuclei. Fig. 27, again, represents a section which is too oblique to show the true shape of the lens.

Turning now to the histological structure of the adult lens, the first thing we have to notice is that the distinction between marginal zone and central mass can no longer (at any rate with certainty) be made out (figs. 2, 3, 27, 28). Presumably all or most of the undifferentiated cells have been used up in the formation of definite lens-tissue. The nuclei are probably all or nearly all more or less elongated, frequently spindle-shaped, but they are not so closely crowded together as in the earlier stages and far less regularly arranged, so that they appear cut through in very various directions. The cells themselves have evidently become greatly elongated and irregularly curved, so that they also appear cut across in various directions, even in an approximately median section, and it is very difficult to get an idea of their true form. Towards the outer surface of the lens the cell boundaries are only faintly indicated; towards the inner surface they are more distinct, and the innermost ends of the cells project into the cavity of the eye as small hemispherical protuberances (figs. 27, 28). It is, of course, impossible to follow any individual cell through from the outer to the inner surface of the lens, but I am now* inclined to think that they probably do, for the most part, run right through, even in the adult, though not in the regular manner represented in BALDWIN SPENCER'S figure.

Towards the outer surface of the lens the cell bodies appear to be filled with dense protoplasm, which exhibits a delicate longitudinal striation. In the inner ends of the cells (and sometimes in the middle portions) the protoplasm is much less dense and arranged in the form of very slender, mostly longitudinal threads or fibrillæ, as represented in figs. 27 and 28. This fibrillated character of the inner ends of the lens-cells appears to be very constant, and may be observed in sections treated by various methods. It is, perhaps, best shown in *Sphenodon* A, where the pineal eye was fixed in Flemming's solution and stained with Ehrlich's hæmatoxylin. In this

* On a previous occasion (DENDY, 1907, *b*) I expressed the view that the cells do not extend through the lens from surface to surface, but are arranged in two layers, outer and inner, being misled by the difference in character between the two ends of the cells and by the impossibility, owing to the shape of the cells, of following any one right through in sections.

specimen also many of the lens-cells show a small darkly stained spot, resembling a centrosome, close to the inner extremity (fig. 27, *c. s. ?*).

The nuclei of the lens-cells contain much chromatin pretty uniformly scattered in small granules, one of which, somewhat more conspicuous than the remainder, may commonly be distinguished as a small nucleolus. Usually the lens is entirely free from pigment, but in *Sphenodon I* it contains a few granules as shown in fig. 28 (*Pig.*).

In all adult specimens which I have examined, with the exception of *Sphenodon III*, in which the pineal eye is too badly damaged to allow this point to be determined, the lens exhibits a very remarkable differentiation in its interior, in the neighbourhood of the optic axis, either about the centre of the lens or nearer to the inner surface. The lens-cells here appear to have become converted into large, irregular, deeply staining, very finely granular masses, in which nuclei may be embedded. It was the discovery of such a mass in *Sphenodon A* which chiefly led me to undertake the present investigation. Fig. 27 shows the large granular body in the middle of the lens in this specimen, with a very distinct nucleus. In my communication to the British Association at York in 1906 I referred to this as the "central cell," and compared its appearance to that of a large ganglion-cell, a comparison which has not been justified by my subsequent observations.

The examination of additional material has thrown much light upon the nature of this enigmatical body. In the first place it soon became obvious that there may be more than one such body in the lens (figs. 2, 3, 28), and that although they may contain nuclei it is extremely doubtful whether they have the morphological value of single cells. Rather they appear to be formed by conversion of lens-cells into what, for want of a better term, I propose to call mucus. The truth of this view was to my mind pretty conclusively established by the discovery of a specimen in which some secretion is actually being discharged through an aperture in the middle of the inner surface of the lens into the cavity of the eye, as represented in figs. 2 and 28.

This specimen (*Sphenodon I*) demands further consideration. Fig. 2 represents a section stained in bulk with Ehrlich's hæmatoxylin and counterstained on the slide with eosin. Near the centre of the lens are seen two irregular, finely granular masses, which have stained very deeply with the eosin, and obviously correspond to the central mass in *Sphenodon A*. They appear to contain no nuclei, but nuclei which may possibly belong to them occur in neighbouring sections. Lying close by, however, are nucleated cells, with very dense, deeply staining, finely granular cytoplasm, which probably represent an early stage in the degeneration of the cells into mucus (compare fig. 28). Below these darkly staining masses, and separated from them by a considerable interval, is a small oval cavity opening by a minute pore in the middle of the lower surface of the lens into the cavity of the eye. This cavity is surrounded by dense, darkly stained tissue exhibiting a fine radial striation, and evidently formed by modification of the inner ends of the lens-cells. (This is

better shown in fig. 28.) It is filled with a substance which has not taken the stain, or hardly at all, but contains numerous minute, highly refractive granules. These granules are undoubtedly artifacts caused by precipitation in the process of staining, for similar granules occur in connective tissue outside the pineal eye altogether, while they do not occur in adjacent sections differently treated (fig. 28). Their presence is of importance, however, because it makes it easier to trace the connection of the contents of the cavity in the lens with the vitreous body in the cavity of the eye, the part of which next to the lens has reacted to the reagents employed in a precisely similar manner, as shown in fig. 2. It is evident, I think, that this portion of the vitreous body has recently been extruded through the aperture in the inner surface of the lens, leaving only a small portion behind in the cavity above mentioned. The aperture is probably merely a temporary one, visible only at the time when mucus is being discharged, for I have not found it in any other specimen.*

Other sections of this series were counterstained on the slide with picro-indigo-carmin, and entirely confirm these observations. The finely granular masses in the centre of the lens are stained light green, the contents of the small cavity darker green; the thread of mucus which connects the contents of the cavity with the vitreous body is stained like the contents themselves, but elsewhere the part of the vitreous body which exhibited the granulation in the previous section is stained more lightly green. Fig. 28 represents one of these sections, taken a little to one side of the actual connection between the vitreous body and the mucus in the cavity of the lens.

I think we are justified in concluding from the above observations that some of the cells in the centre of the lens become converted into mucus and that this mucus, secreted from the inner surface of the lens, takes part in the formation of the vitreous body. In other words, the lens has to some extent a glandular character.

It appears that nuclei may pass out from the lens with the mucus; one such is represented lying in the mucus close to the secretory aperture in fig. 2, and others are to be found in the recently exuded portion of the vitreous body (figs. 2, 28). These are probably the remains of the nuclei of those lens-cells by the degeneration of which the mucus was formed in the interior of the lens. It does not follow, however, that all the nuclei which occur in the vitreous body are derived from this source (*vide ante*, p. 272).

I have naturally looked carefully in my embryological material for indications of this remarkable process of mucus-formation in the lens, and I think there can be little doubt that in some cases it has already begun to take place at Stage R, while the development of the lens is still incomplete and the cells of the marginal zone by no means all converted into definite lens-tissue.

Thus Embryo 162 (Stage R) shows a pear-shaped drop of mucus attached to the

* Sphenodon II, however, shows a small cavity, filled with darkly stained material, closely resembling that found in Sphenodon I, and in precisely the same situation at the bottom of the lens. In this case the sections were overstained in bulk with Ehrlich's hæmatoxylin, after prolonged decalcification.

middle of the inner surface of the lens, from which it has apparently just exuded, and Embryo 141 (Stage R, fig. 26) shows a very similar condition, except that in this case nuclei as well as mucus appear to have been already discharged from the lens.

The most remarkable result, however, was obtained from Embryo 159 (Stage R) and is represented in fig. 25. In this case we have, in the optic axis of the lens, towards but still at some distance from the inner surface, a sub-spherical body (fig. 25, *mu. m.*) with a definite, capsule-like wall, containing the remains of three or four nuclei, and with another nucleus pressed against the wall externally, as shown in the figure. This preparation is one of the HOWES-SWINNERTON set, and was stained with hæmatoxylin and orange G. The nuclei are stained dark blue, while the capsule and its remaining contents have taken the orange with a slight purplish tint. The contents, except the nuclei, are almost clear, but with a slightly flocculent appearance. The whole thing is probably a large globule of mucus with imbedded nuclei, waiting to be discharged into the cavity of the eye.

I think there can be little doubt that this process of mucus-formation by the lens is not merely the result of degeneration but represents a normal occurrence. It is probable that as the lens-cells are used up in the middle of the lens in the secretion of the mucus, they are replaced by others of the ordinary lens-cells, and it is even possible that the supply of lens-cells may be kept up by cell-division in the marginal zone throughout life, but, as already stated, I have not been able to detect a distinct marginal zone in adult specimens.

(6) *The Vitreous Body*.—The presence of a *corpus vitreum* as a normal constituent of the pineal eye of Sphenodon can no longer be questioned, and the observations recorded above indicate sufficiently clearly that it is formed, in part at any rate, as a secretion from the lens. Whether or not it is entirely derived from this source is, however, doubtful. In sections, however carefully prepared, the vitreous body has always shrivelled up to a greater or less extent, but it usually remains more or less connected by slender threads both with the retina and with the lens (figs. 12, 28, etc.). These threads, however, are frequently broken through, doubtless as a result of the contraction of the vitreous body, and are then seen projecting freely from the inner surfaces of the lens and of the retina, while corresponding threads radiate outwards from the contracted mass of the vitreous body (figs. 2, 3, etc.). The latter itself exhibits a reticulate structure in my preparations. The reticulation usually appears to consist of delicate threads, but in Sphenodon A, which appears to be in an exceptionally good histological condition, the reticulation seems to consist rather of thin sheets (fig. 12). In the case of Sphenodon I, which I have already partially described in dealing with the lens, the shrunken mass of the vitreous body consists of two portions, continuous with one another but differentiated by their staining properties as shown in fig. 2. The portion next to the lens has evidently just been secreted by the latter, and in this freshly formed condition hardly stains with eosin, but exhibits a fine granular precipitate entangled in a very delicate network of

fibrillæ, this network being connected by fine threads with the protruding ends of the cells on the inner surface of the lens. The deeper portion, next to the retina, stains well with eosin and contains no granular precipitate. It is less dense and more coarsely reticulate, and the numerous threads by which it was connected with the retina are all, or nearly all, broken through by contraction (figs. 2, 28). Both portions stain, but in different greenish or bluish tints, with picro-indigo-carmin. The deeper portion of the vitreous body is apparently older than the portion which lies next to the lens, and has undergone some change in its staining reactions since it was first formed. Similarly, as we have already seen, the staining reactions of the mucus-masses in the interior of the lens are different from those of the mucus at the moment of its extrusion. These differences are clearly brought out in fig. 2.

The question now arises: Does the vitreous body in *Sphenodon* contain any fibres which are not merely the result of *post-mortem* changes in the more or less homogeneous secretion formed by the lens? I am not in a position to answer this question decisively, but from the analogy of the pineal eye of the lampreys (*cf.* DENDY, 1907, *a*) I am inclined to think that such fibres may be present in the vitreous body of the living animal. The connection of the vitreous body with the walls of the optic vesicle, and especially with the retina, takes place in a very definite manner. At first sight it appears as if the ends of the sense-cells themselves were prolonged into threads which join the network of the vitreous body, but, as I have already shown, careful examination of well-preserved material shows that the end of each sense-cell is covered by a delicate cap (possibly an extension of the *membrana limitans interna* of the retina), and that it is to the apices of these caps that the fibres of the vitreous body are attached, as shown in figs. 12 and 13. It is possible that these fibres may be a further extension of the supporting elements of the retina into the cavity of the eye, but the examination of *Sphenodon* A (fig. 12), where they are very sharply marked off from the caps of the sense-cells, hardly supports this view.

In this connection I may call attention to the appearance represented in the section of the very young pineal eye of Embryo 24*a* (Stage N-O), represented in fig. 31. Even here one or two very definite-looking strands are seen stretching across the cavity of the eye from the lens to the retina. These certainly look like normal structures, but no doubt, even at this stage, the cavity of the eye contains a certain amount of albuminous fluid, and the strands in question may be due to coagulation. In fact, a reticulum, formed presumably by coagulation, is already present in the primary parietal vesicle represented in fig. 29.

The occurrence of nuclei, scattered sparsely in the vitreous body, has already been mentioned. These are no doubt partly extruded from the lens with the vitreous secretion, as already described, but they may be in part derived from another source, viz., the wandering pigment-cells, as previously suggested, and here again we must note that nuclei may occur in the coagulum, even in the primary parietal vesicle (fig. 29).

The vitreous body is usually free, or nearly free, from pigment, but occasionally pigment may occur in it in large quantities, in the form of pigment balls (Sphenodon II). I have, however, already dealt with this question when speaking of the pigment itself. I may add that in Sphenodon I a considerable number of pigment-granules occur in the newly secreted portion of the vitreous body, close to the aperture in the lower surface of the lens, as if they had been passed out from the lens with the secretion (fig. 28).

b. Comparison with the Descriptions of the Pineal Eye of Sphenodon given by other Observers.

The first observer to give any account of the pineal eye of Sphenodon was, of course, BALDWIN SPENCER (1886), who dealt with it somewhat briefly in his often quoted work "On the Presence and Structure of the Pineal Eye in Lacertilia." It is nearly a quarter of a century, however, since this work was published, and it is only natural that the results obtained by the use of more recent methods of histological investigation should differ considerably from those obtained by SPENCER.

It is unnecessary to give a long account here of SPENCER'S well-known description. The points in which we differ with regard to the structure of the eye itself are chiefly as follows :—

(1) SPENCER'S description of the lens is extremely brief, and according to his figure it has a very uniform structure, being composed of elongated cells arranged with great regularity side by side; no cytological details are given, nor is the process of mucus-formation in the centre of the lens mentioned. His statement that the cells of the lens are directly continuous with those of the retina perhaps requires a little modification, in view of the very sharp line of cleavage which separates the two. As he had only adult material at his disposal, he, of course, gives no information as to the development.

(2) SPENCER describes no less than six different kinds of elements as taking part in the formation of the retina :—

(*a*) A layer of "rod-like bodies" which evidently correspond in some degree to the sense-cells described above. The true sense-cells are, however, obviously confounded, to a large extent, with the radial masses of pigment which lie between them. This accounts for the supposed elongation of those rods which lie in the optic axis, and are said to be connected with a special group of nucleated cells lying in the commencement of the "pineal stalk" (nerve). Like HOFFMANN (1890), I have been unable to detect any such group of cells, nor have I been able to detect any transverse striation of the pigment on the rods such as SPENCER describes and figures. The projection of the inner ends of the rods into the cavity of the eye is not referred to by SPENCER.

(*b*) A double or triple row of spherical nucleated elements which appear to be connected by processes, on the one hand with the rods, and on the other with the

layers external to them. These are evidently the nuclei of the sense-cells, which are, however, represented as spherical instead of oval.

(c) A "molecular" layer, which is evidently the layer of nerve-fibres, and is quite correctly represented as separating the retinal elements into an internal and an external division.

(d) A layer of nucleated spherical elements lying outside the molecular layer. These are evidently in part the nuclei of the ganglion-cells, and probably in part the nuclei of the radial fibres.

(e) A layer of cone-shaped bodies in which no nuclei can be detected. These are clearly the outer ends of the radial fibres.

(f) A series of nucleated spindle-shaped elements lying between the bases of the cone-shaped bodies. These also are probably parts of the radial fibres; at any rate I cannot otherwise identify them.

(3) The vitreous body is represented by SPENCER (fig. 3) as an entirely undifferentiated humour.

HOFFMANN (1890) gives an account of the minute structure of the pineal eye of *Sphenodon* which agrees much more closely with my own observations. He describes the lens as consisting of a finely fibrous ground substance whose fibres run parallel to the optic axis, and in which nuclei of two kinds are imbedded. Most of these nuclei are round, the remainder elongatedly oval, and they occur mixed together. There is no distinctly cellular structure in the lens as described by SPENCER. According to my own interpretation the round nuclei described by HOFFMANN are merely the cross-sections of oval nuclei; but the most important difference between our results lies in HOFFMANN'S omission of all reference to the process of mucus-formation. HOFFMANN was unable to satisfy himself whether the lens remains in continuity with the retina or is separated from it by a fine fissure.

The most important advance made by HOFFMANN is his description of the retina as composed of only three layers. These are, from within outwards:

(1) A layer of deeply pigmented rod-like bodies. These are nucleated and produced into processes which run outwards. These are obviously the sense-cells still confounded with the pigment-masses between them.

(2) A layer of large round nuclei, arranged in two or three rows and imbedded in finely granular ground substance. These are obviously the ganglion-cells imbedded in the nerve-fibre layer, but they are not described as such, only their nuclei, apparently, having been observed.

(3) A layer of conical or pear-shaped cells, with broad base directed outwards, and apex inwards; the cell-body almost filled by the large nucleus, and the apex produced into a slender, finely granular process which appears to be connected with the slender prolongation of one of the rod-like cells. These are undoubtedly the radial supporting cells or fibres. Their connection with the sense-cells is, I believe, entirely illusory.

The vitreous body is described as probably consisting of nothing but coagulated cerebro-spinal fluid.

HOFFMANN adopts the view that the pineal eye is constricted off from the "epiphysis." He was the first, so far as I know, to recognise the ganglion-cells in the wall of the latter, and it is remarkable that he failed to recognise them also in the retina of the pineal eye.

LEYDIG also (1891) has given an account of the minute structure of the pineal eye of Sphenodon, but his material was apparently not in a very good state of preservation, and his description is nothing like so satisfactory as that of HOFFMANN. Indeed LEYDIG even tries to demonstrate that the nerve of the pineal eye is nothing but a bundle of connective tissue. It is difficult to believe that what he saw can have been the real nerve at all. Perhaps the unsatisfactory nature of his results is to be partly explained by the great difficulty which he experienced, like myself, in softening the cranial roof, so that he was finally obliged, after decalcification had proved useless, to remove the eye from the parietal foramen altogether before cutting.

The last writer to deal with the structure of the pineal eye in Sphenodon was GISI, who so recently as 1907 gives a brief description of its histological structure, without illustrations. This description differs but little from that of BALDWIN SPENCER, and need not detain us further.

c. Comparison with the Pineal Eye of other Reptiles.

In view of the comparatively recent publication of STUDNIČKA's admirable summary of our knowledge of the subject (1905), it is not necessary for me to endeavour to make any exhaustive comparison with the observations of earlier writers on the pineal eye of other reptilian types. Since the publication of STUDNIČKA's work, however, important papers have been published by NOWIKOFF (1907) and SCHMIDT (1909). The former contains by far the most satisfactory account of the reptilian pineal eye which has yet appeared. The types investigated by NOWIKOFF are *Lacerta* and *Anguis*, and in most respects the pineal eyes of these lizards make a very close approach to that of Sphenodon. There appears, however, to be nothing comparable to the process of mucus-formation in the lens, the cytological structure of which seems to be a good deal simpler.*

In the retina NOWIKOFF recognises precisely the same constituent elements as I find in Sphenodon, viz. : sense-cells, ganglion-cells and nerve-fibres, and radial supporting cells, and these occupy the same relative positions in the two cases. In only two respects is there any important difference between our results. In the first place, NOWIKOFF regards the pigment as being lodged in the radial supporting cells. This is of course a difficult point to decide, and I have already given my reasons for considering that it lies between and not in the cells in Sphenodon, migrating into the retina from the surrounding tissue. The presence of numerous

* See, however, the postscript at the end of the present memoir (pp. 329-331).

large pigment-cells around the pineal eye in *Anguis* and *Lacerta* (as figured by NOWIKOFF) seems to me to render it probable that the pigment of the retina in these types has a like origin. We are agreed in regarding the sense-cells as being entirely free from pigment.

In the second place NOWIKOFF describes and figures the projecting inner ends of the sense-cells as exhibiting a somewhat different structure from that which I find in *Sphenodon*. "Die distalen Enden der Sehzellen tragen je einen eigentümlichen Fortsatz (fig. 6, 7, 8, *Szf.*), welcher in das Augenumen hineinragt. Diese Fortsätze sind verschieden lang, und erinnern in ihrem Aussehen etwas an zusammengeklebte Cilien von Flimmerzellen. Auf fig. 9, welche das distale Ende einer Sehzelle von *Lacerta agilis* bei starker Vergrößerung darstellt, sieht man an der Basis dieser Fortsätze (*Szf.*) besondere, stark tingierbare Gebilde (*Bk.*), welche an die Basalkörperchen von Cilien erinnern und die Ähnlichkeit der Sehzellen mit Flimmerzellen noch auffälliger machen. Diese Fortsätze sind, meiner Ansicht nach, keine lichtperzipierenden Teile der Sehzellen, sondern beteiligen sich zum Aufbau des Glaskörpers, worauf weiter unten näher eingegangen werden soll" (pp. 406, 407).

It is probable that there is really no great difference between the structure of the projecting ends of the sense-cells in the different types referred to. Differences in mode of preparation might account for a good deal, and even in *Sphenodon* the projecting ends generally *appear* to be directly connected with the fibres of the vitreous body, as I have shown above. The appearances represented in NOWIKOFF'S fig. 9 might possibly be due to shrinkage of the "caps" of the sense-cells and the internal limiting membrane.

As regards the vitreous body itself, in *Anguis* and *Lacerta* there seems, as I have already said, to be no indication of its origin, in part at any rate, as a secretion from the lens. In some other respects, however, NOWIKOFF'S results agree closely with mine. It is evident that he regards the fibres as a normal constituent of the vitreous body, "Er besteht nämlich sowohl bei *L. agilis* als auch bei *A. fragilis*, gewöhnlich aus dreierlei Elementen: 1. Fortsätzen der Pellucidazellen, 2. Fortsätzen der Sehzellen und 3. einige verästelten Zellen, deren Ausläufer miteinander anastomosieren und auf diese Weise ein Netzwerk bilden" (p. 410).

I have given reasons above for believing that the fibres of the vitreous body which are attached to the retina are not processes of the sense-cells themselves, though possibly they may be derived from the supporting elements of the retina. In this respect they would agree with the processes of the Müller's fibres which are said to take part in the formation of the vitreous body of the lateral eye, though of course the vitreous body occupies a morphologically different position in the two cases.*

I also doubt whether there are any cellular elements really proper to the vitreous

* Cf. NOWIKOFF (1907), p. 411.

body of the pineal eye. Nuclei occur in it in *Anguis* and *Lacerta* as they do in *Sphenodon*, but I am inclined to regard them in all cases as intrusive.

d. Comparison with the Pineal Eye of the Lamprey.

Here again I may content myself with referring to *STUDNIČKA'S* valuable treatise (1905) for a summary of the work of the earlier writers on the pineal eye of the lampreys. Since the appearance of this treatise, however, I have myself published a detailed account (*DENDY, 1907, a*) of the morphology and histology of the pineal or parietal organs in the New Zealand lamprey, *Geotria*, which may serve as a basis for comparison with *Sphenodon*.

The first point to notice, of course, is that in the lamprey the median pineal eye is formed from the right-hand member of the original pair of sense organs, and not, as in *Sphenodon*, from the left-hand member. Morphologically, therefore, it should be compared with the pineal sac of *Sphenodon* rather than with the pineal eye, which latter is the homologue of the greatly reduced "parapineal" organ in the lamprey. From the physiological and histological points of view, however, the comparison between the actual pineal eyes in the two types is what chiefly interests us.

In both cases the eye consists of a simple hollow vesicle lying between the roof of the brain and the transparent parietal plug, and in both cases the lower part of the wall of this vesicle forms the retina, while the upper part serves to transmit the light. In the lamprey, however, we cannot speak of a distinct lens, for the shape of the "pellucida" is not lens-like and it could not possibly serve to focus the light rays, for it varies much in thickness and its inner surface is produced into irregular outgrowths. The pellucida in the lamprey, like the lens in *Sphenodon*, is made up chiefly of much elongated columnar cells with their long axes at right angles to the outer surface. There is no indication of the process of mucus-secretion which takes place in the lens of *Sphenodon*.

In the lamprey the retina, as in *Sphenodon*, is made up of sense-cells, ganglion-cells and nerve-fibres, and supporting cells; but there are conspicuous differences with regard to the minute structure and arrangement of these elements.

The supporting cells are arranged radially in the inner part of the retina, between the sense-cells, and I have not been able to trace them right through to the outer surface. Their nuclei lie near the middle of the thickness of the retina. In *Sphenodon* the supporting cells are most conspicuous in the outer part of the retina, where their nuclei are also situated. More important is the fact that in the lamprey the so-called pigment undoubtedly lies in the supporting cells, which are consequently often called pigment-cells. The pigment, however, cannot be compared with that in the pineal eye of *Sphenodon*, for, as is well known, it is white and consists probably of phosphate of lime. Another peculiarity of the pigment-cells (in *Geotria*) is that their inner ends project as rounded knobs into the cavity of the eye.

The sense-cells are not unlike those of *Sphenodon*, but their inner extremities are

swollen into rounded knobs, which project beyond the knobs of the pigment-cells into the cavity of the eye. The ganglion-cells and nerve-fibres are not arranged in such an even layer as in *Sphenodon*, and the former are accumulated in a great mass around a separated portion of the cavity of the eye known as the atrium.

In the interior of the eye there is a well-developed reticulum with fibres attached, on the one hand, to the back of the pellucida, and on the other apparently directly to the projecting knobs of the sense-cells.

It is thus evident that, while there is a very substantial agreement in structure between the pineal eyes of the lamprey and of *Sphenodon*, yet there are considerable differences in histological detail, though perhaps not more than we might reasonably expect in such widely separated types.

The so-called parapineal organ of the lamprey, representing morphologically the left pineal organ, simply reproduces, in a greatly reduced condition, the structure of the pineal eye.

e. The Functional Capacity of the Pineal Eye.

It is extremely difficult to form any conclusion as to how far the pineal eye of *Sphenodon* still functions as a light-percipient organ. Such experiments as have hitherto been made have yielded entirely negative results. The concentration of a bright light upon the skin above the pineal eye elicits, so far as I have been able to make out, no response; but then it must be remembered that the animals are extremely sluggish, and a similar experiment with the paired eye may be continued for some time without producing any visible effect beyond the contraction of the pupil.

I also attempted, in the case of *Sphenodon* III, as already stated, to observe the effect of light upon the migration of the pigment-granules in the retina, but being unable to sacrifice a specimen entirely to this experiment, I met with no success. I have since found, however, that NOWIKOFF (1907) was able to perform a similar experiment successfully in the case of *Anguis* and *Lacerta*, and to demonstrate thereby the backward and forward movement of the pigment-granules in the retina of the pineal eye, in accordance with the varying intensity of the light.

It may be questioned, however, whether the movement of the pigment-granules in the retina under the stimulus of light proves very much as to the functional capacity of the pineal eye, for such movement of pigment-granules is by no means confined to eyes. Thus, G. H. PARKER (1906) observes: "It is now generally recognised that, of the various factors concerned in the integumentary colour changes in lizards, none is so important as the migration of the pigment granules in the large pigment cells of the derma. . . . Thus, a *distal* migration of the pigment results in a *dark-coloured* skin, a *proximal* migration in a *light-coloured* one. . . . The migration of the pigment is influenced both by internal and external factors. Not only do the emotional states and the nervous conditions of the lizard make themselves evident in the colour changes of its skin, but external factors, such as heat and light,

also induce these changes. . . . Thus, in Chamæleon and Anolis, light induces a distal migration of pigment, whilst in Stello, according to FILIPPI ('66), and in Varanus and Uromastix, according to THILENIUS ('97), light calls forth a proximal migration."

Direct experiment, in short, has so far taught us practically nothing as regards the functional capacity of the pineal eye, either in Sphenodon or in any other type, and, in endeavouring to form a judgment on this question, we must at present rely solely upon such indirect evidence as we can obtain from morphological and histological investigations.

That the pineal eye in some of the types described by BALDWIN SPENCER (1886) is in an advanced condition of degeneration, is clearly indicated by its greatly reduced structure. It would be difficult to believe, for example, that the pineal eyes (if one may use the term) of Cyclodus and Chamæleo, which are represented as simple vesicles with no differentiation into lens and retina, and entirely devoid of pigment, can have any value as organs for the perception of light; while, on the other hand, in Varanus, pigment is accumulated to such an extent in the lens as must greatly interfere with the transmission of light to the underlying retina. Thus it appears that degeneration of the pineal eye may take place in one of two ways, either by a general simplification of histological structure, accompanied by total loss of pigment, or by excessive accumulation of pigment in situations where it must interfere with the efficiency of the eye.

If the pineal eye of Sphenodon is degenerate at all, it is in the latter of these two ways that degeneration has taken place. I have already dealt at length with the arrangement and origin of the pigment in the pineal eye, and shown how, in the adult animal, the amount of this pigment is probably increased by the migration into the retina of wandering cells heavily laden with relatively coarse pigment-granules. The lens, however, is still left almost, if not quite, free from pigment, and usually there is only a very little in the vitreous body, though occasionally there may be much.

How far the large amount of pigment in and about the pineal eye can justly be looked upon as a sign of degeneration is a very difficult question. Perhaps some light may be thrown upon the problem by comparing the description given by EIGENMANN (1909) of the degenerating lateral eyes of the blind fishes *Lucifuga* and *Amblyopsis*. Speaking of *Lucifuga*, he says (p. 214 *et seq.*): "Near the eyes of all specimens above a certain size there are found masses of pigment. They are probably cells gorged with pigment which are aggregated in one or several masses. . . . From the above it is seen that the pigment masses make their appearance at about the time the eye begins to actively degenerate, a short time after birth, and that they reach their maximum development when the eye has reached the vanishing point. . . . The appearance and gradual increase of these pigment cells and masses with the beginning and progressive degeneration of the eye makes an intimate

dependence of the one phenomenon on the other very plausible. That pigment cells may sometimes appear and become pigmented at some distance from the degenerating eye is seen in the optic cavity of the largest individuals, where cells with but few pigment granules were seen remote from the eye. Furthermore, no phagocytes or pigment cells in the process of gorging were seen in the eye. But in one case at least there were found a number of fully pigmented cells between the pigment layer and the rest of the retina. There seems to be little doubt, therefore, that there is direct association of at least some pigmented cells with the degenerating eye. Other indications as to the possible origin of the pigment masses are given under the head of the lens. In some of the degenerating lenses cells containing pigment granules were found."

These observations seem clearly to support the view that the development of an unusually large amount of pigment in connection with the pineal eye is also to be looked upon as an indication of degeneration. In short, I think we must admit that the pineal eye of *Sphenodon* is no longer at the summit of its career as a light-percipient organ, but the indications of degeneration in structure are very slight, not approaching in degree those which are exhibited by the degenerating lateral eyes of the blind fishes above referred to. It is impossible for me to believe that an organ which retains such a complex histological structure, which is provided even in the adult (as we shall see presently) with a well-developed nerve and an abundant supply of ganglion-cells, and which occupies a position where it is actually exposed to light, can be entirely functionless, and this view is further supported by the fact that it is provided with a special artery of its own, and, above all, by the fact that the overlying connective tissue (parietal plug) is very specially modified to form a transparent light-transmitting organ. There can, of course, be no question of the formation of definite images; the irregular arrangement of the scales above the parietal plug entirely precludes such a possibility; but the organ still seems well adapted for the perception of variations in the intensity of the light, and may perhaps still be of use under conditions of which we are entirely ignorant. That light actually does pass through the integument above the parietal plug, and through this plug itself, I have proved by direct observation.

It also appeared to be worth while to find out whether, by any chance, the pineal eye of *Sphenodon* might exhibit any luminosity, but examination of living specimens in the dark yielded entirely negative results.

E. *The Pineal Nerves.*

Each of the pineal organs, right and left (pineal sac and pineal eye), is provided with an abundant nerve-supply, consisting of non-medullated fibres which pass from their respective organs to the roof of the brain in the habenular region. As we can still distinguish between the left and right pineal organs, although these have become shifted so as to occupy an antero-posterior position with regard to one another,

so we are also able to recognise left and right pineal nerves which have come to occupy a corresponding antero-posterior position, though, as we shall see directly, the anterior nerve actually lies considerably, and apparently constantly, to the left of the middle line throughout the greater part of its course—an important piece of evidence in favour of its paired origin.

(1) *The Left Pineal Nerve (Nerve of the Pineal Eye) in the Adult.*—The left pineal nerve is connected with the retina of the pineal eye, and by some authors is referred to simply as the “pineal nerve.” It is the “parietal nerve” of STUDNIČKA’S terminology.

BALDWIN SPENCER, as is well known, regarded this nerve (in *Sphenodon* and in *Lacertilia*) as being derived directly from the “Epiphysis” (right pineal organ or pineal sac) by the same constriction which, according to his views, separated off the pineal eye. More recent observers are probably unanimous in attributing to it an independent origin. STRAHL and MARTIN (1888) and BÉRANEK (1892) maintained that (in lizards) it arises quite independently of the “epiphysis,” and is connected with the roof of the brain in front of the latter and in the neighbourhood of the habenular commissure.

DE KLINCKOWSTRÖM (1893), working on *Iguana* embryos, states that he traced the nerve of the pineal eye to the *right* habenular ganglion, but also found, sometimes, another nerve joining the pineal eye to the left habenular ganglion, and in one case yet a third nerve joining the “epiphysis” (right pineal organ) to the posterior commissure. He found the pineal eye vestigial in the adult and the nerve degenerate.

In *Sphenodon* itself, we find that various more or less divergent statements have been made with regard to the anterior or left pineal nerve. BALDWIN SPENCER, by whom it was first described in 1886, observes: “There can be little doubt that this median, azygos, nerve represents the originally hollow process uniting the proximal with the distal portion of the epiphysis, and which, losing its connection with the optic vesicle in some forms (*e.g. Anguis*), is in others (*e.g. Hatteria*) transformed into a solid stalk serving as the nerve of the pineal eye.”

I myself (1899, *b*) described this nerve in advanced embryos of *Sphenodon* (Stage R) as follows:—“It passes in front of and beneath the distal extremity of the parietal stalk,* and becomes connected with the outer layer of the retina (figs. 15 and 16). Unfortunately I have been unable to trace it to its point of origin from the roof of the brain, but I have little doubt that the connection takes place at or near a point immediately in front of the origin of the parietal stalk, corresponding to what BÉRANEK terms the parietal centre, and lying between the posterior ends of the two ganglia habenulæ, above the fibres of the superior commissure (fig. 26). It seems probable that the nerve is actually connected with one or other of the ganglia habenulæ, as in *Ammocœtes*, but I have been unable to detect any such difference in

* Right pineal organ or pineal sac.

size between the two ganglia as occurs in the lamprey.* The fact that the parietal eye itself in *Sphenodon* originates on the left side of the middle line seems to make it probable that the nerve is connected with the left ganglion habenulæ. The observations of DE KLINCKOWSTRÖM, however, point to the right ganglion. Possibly the nerve crosses over from right to left, but this is a question which cannot be decided in the present state of our knowledge, and one which is well worthy of further investigation."

In 1903, SCHAUINSLAND published a figure (Taf. VIII, fig. 73) taken from a somewhat advanced embryo of *Sphenodon*, in which the nerve in question ("Parietalaugennerv") is shown passing from the pineal eye beneath the "epiphysis" and joining the superior commissure immediately in front of the origin of the "epiphysis." He states that it lies a little to one side of the middle line, but does not say which side. He also gives in the same work (Taf. IX, fig. 74) a drawing of a section of a more advanced embryo, in which he shows the nerve exactly as I had done, disconnected from the brain. He considers that the nerve has already undergone degeneration. "Der Strang (*bs*) welcher das Parietalauge mit der jetzt weit von dem Auge abgerückten Epiphyse (*ep*) verbindet (oder vielmehr bis zum distalen Ende der Epiphyse zieht und dann ausserhalb an der unteren Seite derselben verläuft), besteht in diesem Entwicklungsstadium zwar schon zum grössten Teil aus Bindegewebe, doch lässt sich auf Querschnitten in ihm der jetzt bereits rückgebildete Parietalaugennerv noch mit grösster Deutlichkeit nachweisen."† We shall discuss later on the question as to whether or not the conclusion that the nerve has become degenerate is justified.

As regards the pineal nerve in the adult *Sphenodon*, we have some very precise statements from JULIA GISI (1907) in her work on the brain: "Zwischen der Paraphyse und dem Pinealorgan hindurch windet sich der aus dem Parietalauge kommende Nervus parietalis. Er schlängelt sich der Decke des 3. Ventrikels entlang, teilweise in den Falten des Pinealorgans verborgen, und endigt im medialen, rechtsseitigen Ganglion habenulæ. Den Eintritt in das Ganglion konnte ich nur an einer Schnittserie deutlich beobachten. Doch zieht nicht der ganze Nervus parietalis ins Habenularganglion hinunter. Der ins Ganglion einmündende Teil des Nervs war etwas dünner als ein weiter oben sichtbares Stück. Auf 2 andern Schnittserien bog ein Teil des Nervs direkt in das Pinealorgan hinein. Die Limitans externa des Organs war unterbrochen. Mit Blutgefässen zog das Faserbüschelchen aufgelöst in den ventralsten Teil der pinealen Zellwand hinein. An jener Stelle fanden sich in der äussern Wand des Pinealorgans wenige jener grossen blassgelblichen, sphärischen Elemente, wie ich sie für das Innere des Organs beschrieb.

"Der Nervus parietalis, der bis dahin nur für die Embryonen bekannt war, ist

* I show in the present memoir, however, that some asymmetry between the two ganglia occurs in the adult *Sphenodon*.

† *Op. cit.*, p. 55

prinzipiell zusammengesetzt wie der Opticus; nur sind die langen, spindelförmigen Kerne vorwiegend, indes die rundlichen und blass gefärbten mehr zurücktreten. Er ist von einer dünnen Membran umgeben, die mit der Hülle des Pinealorgans zusammenhängt. Ausser Bereich des Pinealorgans zwischen seiner frontalen Spitze und dem Parietalauge, ist die Hülle sehr dick, bis $\frac{1}{4}$ des Nervendurchmessers. Eine kurze Strecke weit kann der Nerv wie bei Iguana in 2 Teile gespalten sein. Jeder der Teile ist mit einer besondern Hülle versehen, doch sind sie fest aneinander gelagert. Immer zieht er in welligem Verlauf von dem frontalen Ende des Pinealorgans über das caudale Drittel der Vorderhirnhemisphären direkt in das Parietalauge.”*

Our faith in the accuracy of this description is a little disturbed by the fact that, a few pages later on, the authoress states that the main part of the nerve in question enters the *left* habenular ganglion: “Er kann distal gespalten sein; proximal sendet er spät und post-embryonal immer wenige Fasern ins Pinealorgan, das Hauptkontingent aber ins linke Habenularganglion.”† In another place she speaks of a well-developed nerve, apparently the “parietal nerve,” “der ganz normal ventral vom Pinealorgan verläuft und ventral teilweise im Pinealorgan endet, grösstenteils jedoch mit dem Tractus pinealis ins Habenularganglion einmündet.”‡

It is to be feared that these statements have not done very much towards settling what is certainly a very difficult question.

I now propose to describe my own observations on the nerve of the pineal eye in the adult Sphenodon, based upon several series of transverse and longitudinal (vertical) sections. We may conveniently begin with an account of its course as seen in a series of transverse sections (Sphenodon VI), in which it can be followed, up to a certain point, with great ease, being for the greater part of its extent easily recognisable as one or more well-defined bundles of very fine, non-medullated fibres interspersed with elongated nuclei, and, at any rate in the more anterior portion of its course, enclosed in a thick sheath of connective tissue (fig. 53).

Commencing at the postero-ventral portion of the wall of the pineal eye, where it is formed by the association of the numerous fine fibres from the nervous layer of the retina, it passes backwards and downwards across the cavity of the eye-capsule (fig. 47), the wall of which is produced for some distance as a kind of outer sheath for the nerve (compare fig. 3). It then passes into the *dura mater* beneath the hinder part of the parietal plug (figs. 48, 49, *n. p. e.*). Here it comes into association with the branches of the anterior pineal artery (*r. a. p. a.*), lying, together with the latter, in the middle of the irregular loop formed by the *sinus longitudinalis (s. l.)*. In this region the nerve, excluding its sheath, measures about 0.04 mm. in diameter. While still within the loop of the sinus it divides into two (fig. 50), and then into

* *Op. cit.*, pp. 52, 53.

† *Op. cit.*, p. 62.

‡ *Op. cit.*, p. 56.

three strands, which keep close together and take up their position beneath the now undivided anterior pineal artery (fig. 51). Up to this point the nerve has lain approximately in the middle line, and just beneath the dense connective tissue of the cranial wall, in the *dura mater*. It now passes, once more as a single strand, to the left of the pineal artery (fig. 52), and at a distance of 2.73 mm. behind the pineal eye the nerve and artery together meet the anterior extremity of the pineal sac. Here they take up a position beneath the ventral wall of the pineal sac and on the left of the middle line (text-fig. 13). This position is maintained with little alteration, except for the varying extent to which the nerve and artery are enveloped in the folds of the pineal sac, for some distance (text-figs. 14 and 15). At one point the pineal nerve divides again into two strands which surround the artery, but these soon re-unite into a single nerve, which presently ceases to be buried in the folds of the pineal sac and comes to lie between the latter and the wall of the dorsal sac, no longer in such close association with the artery (text-fig. 16). In this position, still keeping well on the left side of the middle line, it runs on to a point not far from the lower extremity of the pineal sac, where its histological character undergoes an abrupt change and it ceases to exist as a single well-defined nerve, breaking up into a number of separate strands of fibres, from which the characteristic nuclei of the main nerve are absent and the course of which is extremely difficult to follow. All one can say from this series of sections is that these strands lie between the wall of the pineal sac and the dorsal sac, which are here in intimate contact with one another; I have not been able to follow them to the habenular region.

As GISI has already noticed, the connective tissue sheath of the left pineal nerve is much thicker before it joins the pineal sac (anteriorly) than it is afterwards. Indeed, where the nerve lies more or less enclosed in the folds of the ventral wall of the pineal sac, it is sometimes difficult, if not impossible, to recognise the sheath at all.

These results have been abundantly confirmed in several series of transverse and longitudinal (vertical) sections. In the latter the left pineal nerve is easily recognisable as a well-defined bundle of very fine fibres interspersed with elongated nuclei, running backwards from the pineal eye (fig. 3) and curving downwards in the latter part of its course, between the ventro-anterior wall of the pineal sac and the adjacent wall of the dorsal sac, as shown in figs. 58, 63, and 64, and ending abruptly, as a single nerve, near the lower extremity of the pineal sac, at the spot marked *x. n. p. e.* in fig. 58.

It receives bundles of fibres from the nervous layer of the wall of the pineal sac, as shown in Figs. 63 and 64, which pierce the enveloping membrane of the latter. These bundles of fibres, like the strands into which it breaks up at its lower extremity, are destitute of the elongated nuclei which characterise the main trunk.

The point (fig. 58, *x. n. p. e.*) where the left pineal nerve finally breaks up into a number of non-nucleated fibre-bundles is situated somewhat above the line along which the wall of the dorsal sac parts company with that of the pineal sac, this line

again being a little above the lower extremity of the latter, which projects freely downwards in the sub-dural space. These relations are shown in figs. 58-61. It will also be evident from these figures that at no great distance from the point where the left pineal nerve breaks up, the thin wall of the dorsal sac joins the left habenular ganglion (fig. 61, *G. H. L.*).

In one series of longitudinal sections (*Sphenodon* V) I have succeeded in tracing a very distinct bundle of fibres from the extremity of the main trunk of the nerve well into the free portion of the wall of the dorsal sac, where it is seen in fig. 59 (*s. n. p. e.*), but I could not follow it to the left habenular ganglion. Numerous fibres, however, enter this ganglion from the wall of the dorsal sac. This is also the case with the right habenular ganglion and with the median portion of the ganglion above the habenular commissure. Hence it seems not impossible that all three may be directly connected with the main trunk of the left pineal nerve. The fact, however, that the left habenular ganglion is produced upwards into the wall of the dorsal sac in such a characteristic manner at the point where it receives the nerve-fibres from the latter in special abundance (figs. 54, 61, *n. p. e.*), affords strong evidence that it receives at any rate the greater part of the fibres of the left pineal nerve.

It is also possible that some of the fibres of the left pineal nerve may run downwards along the wall of the pineal sac to join the upper end of the right pineal nerve (*tractus pinealis*) where the latter enters the wall of the pineal sac, but owing to the difficulty of distinguishing these fibres from the connective tissue of the *pia mater* in this region, I have not been able to satisfy myself on this point.

It is evident from the above observations that the nerve of the pineal eye does not pass from the eye to the brain as a single undivided cord, but that, having reached a certain point, it suddenly subdivides into a number of separate strands, which are extremely difficult to follow. The explanation of this will be forthcoming when we deal with the development of this nerve. Even in the adult, however, there is strong evidence that the nerve is not a median structure but belongs to the left side.

There is little more to be said about the histology of the left pineal nerve. The main trunk, from its origin at the pineal eye to its termination, presents the usual characters of a bundle of non-medullated nerve-fibres accompanied by elongated nuclei, such for example as is represented in fig. 138 of SCHÄFER'S "Essentials of Histology," (ed. VI), and such as I myself have already described (1907, *a*) in the case of the right pineal nerve of the New Zealand Lamprey (*Geotria*). It may, as we have seen, be provided with a well-developed sheath of connective tissue (fig. 53, *c. s. p. n.*). There is not the slightest indication of the degeneration which SCHAUINSLAND (1903) believed to have taken place already in the advanced embryo. The elongated nuclei (figs. 63, 64, *n. p. n.*) which lie embedded in large numbers amongst the very slender fibres, and which are, as Prof. HALLIBURTON has suggested to me, possibly nutrient in function, are confined to the main trunk and cease abruptly at its two extremities. They are not found in any of the branches of the trunk, nor are they continued quite

up to the retina of the pineal eye (fig. 3). BALDWIN SPENCER (1886) describes and figures "a special group of nucleated cells (n^3) which lie enclosed by a somewhat definite membrane in the pineal stalk," close to the junction of the left pineal nerve with the retina. There may be a few nuclei here, probably belonging really to the retina, but I have found no such definite group as SPENCER describes, the nerve-fibres passing direct from the nervous layer of the retina into the nerve itself.

(2) *The Right Pineal Nerve* (Tractus pinealis) *in the Adult*.—This is the *tractus pinealis* of STUDNIČKA'S terminology. GISI (1907) observes:—"Das Pinealorgan sitzt an einem kurzen Gliastrang, dem Tractus pinealis, nur minim vom Gehirndach entfernt. (An 2 Exemplaren ist der Tractus pinealis länger, die Entfernung Gehirn—Pinealorgan deshalb auch grösser.)"* To judge from this paragraph alone, GISI apparently did not recognise the fact that with the "Gliastrang" an important bundle of non-medullated nerve-fibres leaves the wall of the pineal sac. She speaks, however, of the *tractus pinealis* containing a few ganglion cells, and in another place (p. 56) she speaks of it as if it entered the habenular ganglion in association with the left pineal nerve.

If we apply the term *tractus pinealis* in a wide sense to the entire band or cord of tissue which unites the lower extremity of the pineal sac to the roof of the brain (text-figs. 12, 18, *T. P.*), we may say that it arises ontogenetically from the constricted proximal portion of the pineal sac of the embryo, together with a certain amount of pial connective tissue. As I have shown in my memoir on the development of the pineal organs (1899, *b*), the pineal sac ("parietal stalk") originally communicates with the cavity of the third ventricle by an aperture which lies between the superior (habenular) and posterior commissures (figs. 30, 31, 33, 35, 42, 45, 46, *O. P. S.*). By the solidification of the proximal portion of the pineal sac this aperture is closed, but its position is easily recognisable in the adult brain. It lies between the superior and posterior commissures and at the extreme anterior end of the highly developed sub-commissural organ or "ependymal groove." Its position is clearly shown in fig. 62, representing a sagittal section, in which it will be seen that the most proximal part of the original cavity of the pineal sac is still represented by an irregular fissure (probably to be regarded as the *recessus infra-pinealis* or part thereof), lined by epithelium, in the brain-wall, lying beneath the base of the pineal tract. In the transverse section represented in fig. 56 we see how the cavity of the third ventricle is continued upwards between the anterior extremities of the lips of the sub-commissural organ into the base of the pineal tract, forming a well-marked *recessus infra-pinealis* (*r. i. p.*), much as in the lamprey.† GISI (1907) places the spot where the pineal tract joins the brain-roof a little to the left of the middle line:—"Etwas links von der dünnsten Stelle zwischen Schaltstück und Commissura superior ist die Verbindung Gehirn—Tractus pinealis." I cannot, however, agree altogether with this author's

* *Op. cit.*, p. 51.

† *Cf. DENDY* (1907, *a*).

description of the *tractus pinealis* and its connections. Indeed, she herself is by no means consistent in her statements, for in another place (p. 56), as I have already had occasion to point out, she speaks of the *tractus pinealis* as entering the habenular ganglion.

According to my own observations, the point where the *tractus pinealis* joins the brain-roof lies as nearly as may be in the middle line, as shown in fig. 56. Towards the lower extremity of the *tractus pinealis* a remnant of the original cavity may persist (fig. 57, *C. T. P.*), but it is for the most part entirely solid and composed of a bundle of nerve-fibres surrounded by connective tissue and closely accompanied by slender blood-vessels. These vessels, in the only case in which I traced them to their origin (Sphenodon VI), are a small branch of the anterior pineal artery (the latter in this case coming off direct from the left posterior cerebral) and a couple of very slender veins, one of which I traced into the left parapineal vein (text-fig. 18).

At the upper end of the *tractus pinealis* some, at any rate, of the fibres of the right pineal nerve enter the lower extremity of the pineal sac and spread out in the nervous layer of the latter (fig. 60), just as the fibres of the left pineal nerve spread out in the nervous layer of the retina of the pineal eye. It is possible that some of the nerve-fibres may not enter the wall of the pineal sac immediately but spread out first over the surface of the latter and enter it higher up. Some may perhaps join the left pineal nerve, and this may account for the fact that the latter gives off branches to the right pineal organ. These points, unfortunately, I have not been able to determine for want of a method by which small bundles of non-medullated nerve-fibres may be readily and with certainty distinguished from connective tissue—a difficulty which will be referred to again later on.

At its lower end the fibres of the right pineal nerve enter the roof of the brain just between the posterior and superior (habenular) commissures (figs. 56, 62, *T. P.*). Some of them pass downwards on the right side and some on the left of the *recessus infra-pinealis* (fig. 56) towards the posterior extremity of each habenular ganglion, which they appear to join close to the spot where the bundle of Meynert (*m. b.*) is given off on either side, if they are not directly continuous with the latter, and in Sphenodon VI some of them appear to run directly to the median habenular ganglion, as shown in fig. 57. Longitudinal vertical sections show that some of the fibres from the pineal tract, on the other hand, run backwards towards the posterior commissure and sub-commissural organ (fig. 62).

The lower extremity of the pineal tract lies more or less close behind the narrow postero-ventral margin of the dorsal sac, and in one specimen is actually fused with this (Sphenodon VI, figs. 55–57). In this specimen the cavity of the dorsal sac is continued backwards in the form of a small blind diverticulum above the median habenular ganglion, as shown in fig. 55. This diverticulum is separated by only a very thin septum from a cavity lying in the lower part of the *tractus pinealis* (fig. 57, *C. T. P.*) and in the floor of this latter cavity is a small pit lined by

columnar ependymal cells, as shown in the figure, and suggesting a vestige of an upward extension of the sub-commissural organ. In another case (Sphenodon V, fig. 62), however, the lower end of the *tractus pinealis* is separated from the wall of the dorsal sac by about the length of the unpaired (median) portion of the habenular ganglion.

The histological structure of the right pineal nerve closely resembles that of the left. It consists of very slender non-medullated fibres and in one specimen the same characteristic elongated nuclei are present in abundance. In another, however, such nuclei are few and far between.

The wavy fibrous connective tissue (figs. 56, 57, *p. m.*) which, to a greater or less extent, envelopes the pineal tract is doubtless to be regarded as part of the *pia mater*. It is continuous below with the pial investment of the rest of the brain, and above it spreads out over the surface of the pineal sac.

As in the case of the left pineal nerve it is sometimes extremely difficult to distinguish between the real nerve-fibres and the connective-tissue fibres which accompany or surround them. Where either nerve exists as a single well-defined trunk it is easily recognised, but when it breaks up into smaller bundles the case is different. It is, however, frequently possible to detect a distinct difference in staining reaction between nerve and connective tissue. In sections stained with borax carmine followed by picro-indigo-carmine the exact tint of any structure varies very much according to the degree to which differentiation has been carried in the staining process, but, speaking generally, we may say that the connective tissue fibres stain more deeply and of a bluer tint than the nerve-fibres, and they generally have a much coarser appearance and frequently also a more coarsely wavy character. In the sections represented in figs. 56 and 57, at the lower end of the *tractus pinealis*, the differentiation between the nerve-fibres and the connective-tissue fibres of the *pia mater* is very clearly brought out by the picro-indigo-carmine method, the nerve-fibres being stained bright green and the connective tissue showing a strongly contrasted blue or purple tint.

(3) *The Development of the Pineal Nerves.*—The results arrived at above regarding the arrangement of the nerves of the pineal organs in the adult Sphenodon are confirmed in a very striking manner by a renewed investigation of the development of these nerves which I have lately undertaken. It was very necessary to do this as I was only able to give a very imperfect account of this part of the subject in my earlier work (DENDY, 1899, *b*).

The developing pineal nerves are very well shown in sections stained either with Ehrlich's hæmatoxylin and Orange G, or with borax carmine and picro-indigo-carmine. I have studied them in eight series of sections, of Stages O, P, Q, R, and S, in addition to those which I employed for my earlier work. In the latter they were not nearly so well shown, owing to the fact that the sections were stained with borax carmine alone.

a. Development of the Left Pineal Nerve.—SCHAUINSLAND (1903), as I have already pointed out, has, since my earlier observations were published, given a drawing of a section (Taf. VIII, fig. 73) of an advanced embryo showing the nerve of the pineal eye running from the eye itself to the superior (habenular) commissure. He states that this nerve lies somewhat to one side of the middle line, but does not say which side. He considers that at the next stage (Taf. IX, fig. 74) the nerve has begun to degenerate, apparently because of the nuclei which make their appearance in it, though exactly similar nuclei appear in ordinary adult nerves composed of non-medullated fibres.

GISI also (*loc. cit.*, p. 58 and p. 137, fig. R) has something to say about the development of the nerve of the pineal eye ("parietal nerve"), but her figure and description are very inaccurate. The superior commissure, at about Stage Q, is represented as being separated from the entrance of the pineal sac by a relatively long "Verbindungsstück." The nerve first touches the brain-roof at the hinder end of this "Verbindungsstück," and then runs forwards to the left habenular ganglion. According to my observations, no such "Verbindungsstück" exists, or at the most it is insignificant in extent, the superior commissure and habenular ganglia developing immediately in front of the opening of the pineal sac, while the nerve of the pineal eye approaches the left habenular ganglion by way of the wall of the dorsal sac, from above, as I shall show directly.

The earliest indication of the developing nerves which I have seen is in embryos of Stage O (or thereabouts), in one case even before the two pineal vesicles have separated from one another (figs. 30, 31). The vesicle of the pineal eye (*P. E.*) still lies compressed between the roof of the thalamencephalon and the superficial epiblast, its ventral wall resting upon the former. Both superior (*C. S.*) and posterior (*C. P.*) commissures can be recognised in the brain-roof, though as yet but feebly developed. The nuclei in the ventral wall of the pineal eye are just beginning to arrange themselves in two principal layers, separated by the commencing layer of nerve-fibres (*l. n. f. e.*). These fibres are as yet entirely enclosed in the retinal portion of the wall of the pineal eye, and, as I have seen no fibres in the immediately adjacent wall of the brain, I conclude that they appear first in the retina and thence grow into the brain-wall, as in the case of the ordinary paired eyes. In one case (Embryo 39*a*, Stage P), the arrangement of the nuclei of the retina in two distinct layers has apparently been delayed, and the nerve-fibres themselves do not as yet form a definite layer (figs. 36, 37). The characteristic arrangement, however, is very well shown in Embryo 52*a*, Stage Q (Fig. 34).

As the pineal eye becomes separated more and more widely from the roof of the brain by the development of the intervening mesoblast, the left pineal nerve, which has now grown out from the wall of the optic vesicle (retina), grows longer and longer, being attached at its ventral and posterior extremity to the brain-roof. Fig. 32 (Embryo 37*a*, Stage O-P) shows that it is absolutely independent of the pineal sac,

though it very soon comes to be crowded in between the latter and the brain-roof (fig. 34). At about Stage O-P the condition of affairs very closely resembles that described and figured by BÉRANEK in the embryo of *Anguis fragilis*, of which STUDNIČKA gives a good combined diagram (1905, fig. 74). It will be seen that in *Sphenodon*, however, the nerve comes into contact with the brain-roof at a point some little distance in front of the superior commissure. This is well shown both in longitudinal vertical (figs. 32, 34) and in transverse sections. It may even become almost embedded in the brain-roof before reaching the superior commissure (figs. 39, 40, *n. p. e.*).

In two series of transverse sections of about Stage P (Embryos 39*a*, 51*a*) and one of Stage R (Embryo 162) I have traced the nerve of the pineal eye continuously from the eye itself to the brain-roof *at the left side* of the superior commissure, and I have also found the nerve entering the left habenular ganglion in a longitudinal vertical series of Stage R (Embryo 142). In the younger embryos the habenular ganglia were not yet distinctly developed. I have never found it joining the brain-roof in the middle or on the right side.

Embryo 162 is particularly conclusive with regard to the sinistral character of the nerve of the pineal eye, which passes along the left hand side of the pineal sac on its way to the left habenular ganglion (text-fig. 9). Fig. 43, taken from the same embryo, shows how, having reached the hinder end of the dorsal sac, the nerve turns downwards, in close contact with the wall of the latter, and between its two posterior diverticula, but well on the left side. The sinistral character is also clearly shown in figs. 36-40, taken from Embryo 39*a* (Stage P).*

At Stage S the condition of the nerve of the pineal eye is practically as we find it in the adult, except that it has not as yet reached anything like its full length. It can be traced for some distance from the eye over the thin wall of the dorsal sac, beneath the pineal sac, and then disappears. What has probably happened is that the rapid growth of the dorsal sac has caused the fibres of the nerve to spread themselves out over its thin wall, to which they are, as we have already seen, closely attached in this region. Hence it is no longer possible to trace the nerve as a single well-defined strand, except in its anterior portion, where it never becomes firmly attached to the wall of the dorsal sac. The numerous elongated nuclei which form so characteristic a feature of the free portion of the pineal nerve in the adult do not make their appearance till about Stage S.

I think we may now regard it as conclusively established that in *Sphenodon* the nerve of the pineal eye enters the brain primarily by way of the left habenular ganglion. I believe that in all probability the same is true of the Lacertilia.† I have already referred to DE KLINCKOWSTRÖM'S work on Iguana, which seems to show that the

* It must be borne in mind that in the figures referred to in this paragraph right and left sides are reversed.

† See, however, the postscript at the end of the present memoir (pp. 329-331).

nerve of the pineal eye is connected with the *right* habenular ganglion, but as he found that there was sometimes another nerve connecting the pineal eye with the *left* habenular ganglion, and as, moreover, he found the eye itself degenerate and the nerve vestigial in the adult, I do not think that we need attach any very great importance to his results.

b. Development of the Right Pineal Nerve.—At Stage O, when the first nerve-fibres are beginning to make their appearance in the ventral wall of the vesicle of the pineal eye, a similar band of fibres may be seen in the posterior wall of the developing pineal sac, close to where it joins the roof of the thalamencephalon in the neighbourhood of the posterior commissure (fig. 30, *l. n. f. s.*). These fibres appear in the outermost part of the wall, outside all the nuclei, which have not yet begun to arrange themselves in layers. They constitute the commencement of the nerve of the pineal sac, which is thus from the very first in close proximity to the posterior commissure. From this point, at later stages of development, they extend upwards into the wall of the pineal sac, and downwards to the posterior commissure (figs. 33, 35, *T. P.*). When the nuclei in the wall of the pineal sac take on their characteristic arrangement in two primary layers, the nerve-fibres are found between the two, exactly as in the case of the pineal eye (fig. 46, with which compare fig. 34). When the proximal portion of the pineal sac solidifies by obliteration of its cavity, the nerve-fibres form the most important constituent of the “pineal tract” thus constituted, where they are associated with the remains of the epithelial cells, connective tissue and blood-vessels, as already described in the case of the adult.

There can be no doubt, I think, of the connection of the right pineal nerve with the posterior commissure, but it joins the brain in close proximity to the habenular ganglia and superior commissure and, as already indicated, probably gives off fibres also to these, as the corresponding nerve does in the case of *Geotria* (DENDY, 1907, *a*). The right habenular ganglion was in all probability primarily associated with the right pineal organ (pineal sac), just as the left habenular ganglion is associated with the pineal eye, and the connection of the nerve of the pineal sac with the posterior commissure is probably to be regarded as secondary, and to be correlated with the change of function which the pineal sac has evidently undergone.

It will be seen that the account of the development of the nerve of the pineal sac thus given for *Sphenodon* agrees with the observations of LEYDIG (1896) on *Platydictylus*, and differs somewhat from those of DE KLINCKOWSTRÖM (1893) on *Iguana*. The former observed what he took to be nerve-fibres in the “stalk” of the “epiphysis”; the latter describes a nerve (the “tractus pinealis”) running quite independently (in the embryo) from the posterior wall of the “epiphysis” (pineal sac), to the posterior commissure, parallel with that portion of the “epiphysis” which becomes solidified.

F. *The Central Connections of the Pineal Nerves.*

The nerves of the two pineal organs appear to be intimately associated, in the manner above indicated, with the posterior and superior commissures, the habenular ganglia and the bundles of Meynert, and though these structures have, of course, other relations as well, we may conveniently consider them as constituent parts of the pineal complex.

The posterior and superior commissures, as I have already pointed out, can be recognised as early as Stage O as transverse bands of nerve-fibres lying in the outer part of the roof of the brain just behind and in front of the opening of the pineal sac (text-fig. 1 and figs. 30, 31, *C. P.*, *C. S.*).

The posterior commissure grows with great rapidity (compare figs. 32, 35, 45), so that it soon comes to project into the cavity of the brain and also becomes thrown into transverse folds (fig. 45), while at the same time the ependymal epithelium on its ventral aspect becomes modified to form the sub-commissural organ (*s. c. o.*), to be described later on. The relations of the commissure in the adult, in which it appears to be somewhat straightened out again as compared with Stage S, are shown in fig. 62 and text-figs. 12 and 20. Almost, if not quite, from the commencement of its development it is closely connected with the nerve-fibres of the *tractus pinealis* or nerve of the pineal sac (fig. 30, *l. n. f. s.*, figs. 33, 35, 62, *T. P.*).

The superior or habenular commissure (figs. 30, 31, 32, 33, 35, 41, 45, 55, 61, 62, text-fig. 12, *C. S.*) is from the first much smaller than the posterior commissure. In the adult it connects together the right and left habenular ganglia and lies beneath the median habenular ganglion (fig. 55), and with the latter it forms a prominent projection into the brain-cavity in the middle line, just in front of the *recessus infra-pinealis* (fig. 62).

The right and left habenular ganglia project upwards from the postero-dorsal margins of the optic thalami to join the wall of the dorsal sac; they also bulge inwards towards the middle line so as to constrict the opening of the dorsal sac into the lower portion of the third ventricle. These relations are clearly shown in figs. 54 and 61. Fig. 54 also shows that the left habenular ganglion is of a somewhat different shape from the right one, being gradually drawn out upwards into the wall of the dorsal sac. This difference appears to be constant, for I have observed it in all of my three series of transverse sections (*Sphenodon* I, III, VI), and it is associated with the fact that at this point a specially strongly developed bundle of nerve-fibres (*n. p. e.*), doubtless from the pineal eye, enters the ganglion from the wall of the dorsal sac, as also shown in the longitudinal section represented in fig. 61.

The right and left habenular ganglia meet together posteriorly in a median portion which lies above the superior commissure (figs. 55, 57, 62, *G. H. M.*). Some idea of the shape of the ganglia and of the arrangement of the ganglion-cells may be gained from a study of the figures.

From the posterior end of each of the habenular ganglia, right and left, a conspicuous bundle of nerve-fibres is given off into the substance of the brain (figs. 55, 56, *m. b.*). These are the bundles of Meynert, *fasciculi retroflexi* or *tractus habenulo-pedunculares*, as they have been variously termed in different animals. Each one passes obliquely downwards and backwards, just in front of the *recessus geniculi*, to the base of the brain, which it joins at some distance behind the infundibulum, beneath the front part of the optic lobes.

There is no such marked inequality in size between the two bundles of Meynert as exists in the lampreys, but I suspect that the left one may be a little larger than the right. The inequality of their development in the lamprey clearly indicates their connection with the pineal organs, as has been pointed out by various writers (*e.g.* DENDY, 1907, *a*).

VI.—THE BLOOD-VESSELS OF THE PINEAL COMPLEX.

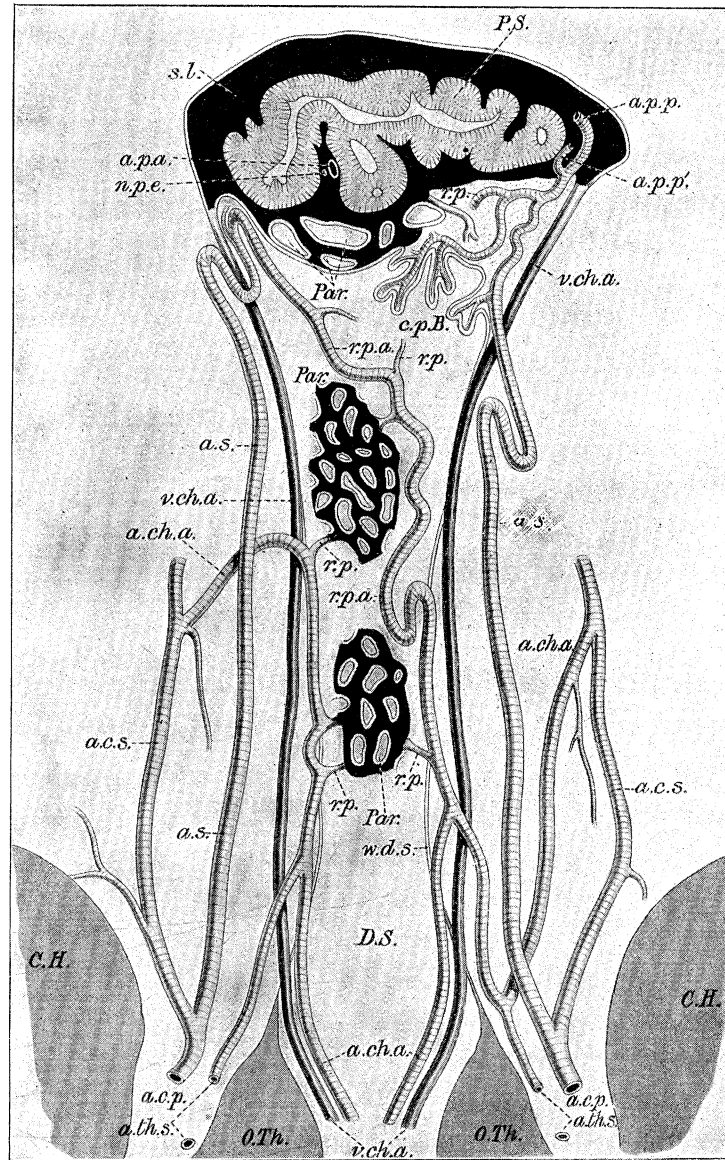
In my memoir on the Intracranial Vascular System of Sphenodon (DENDY, 1909, *a*) I have laid the foundation necessary for a detailed description of the blood-vascular system of the pineal complex.

There is much individual variation with regard to the disposition of these vessels, but all the arteries concerned appear always to be derived from the posterior cerebral artery, and all the venous blood is returned into the *sinus longitudinalis*.

I have already (DENDY, 1909, *a*, Plate 31, fig. 1) described how the posterior cerebral artery on each side divides into a saccular artery and a superior cerebral, the saccular running upwards alongside the wall of the dorsal sac and the superior cerebral running forwards over the cerebral hemisphere and giving off the anterior choroidal as well as a number of branches to the hemisphere. These relations also appear to be constant. I have further described how the anterior and posterior pineal arteries, the former running to the pineal eye and the latter to the hinder part of the pineal sac, may come off from the top of either the right or the left saccular artery. I shall now supplement my former account by a description of a specimen (Sphenodon VI) in which only the posterior pineal artery is given off from the top of the right saccular, while the anterior pineal is given off directly from the posterior cerebral of the left side. This specimen also exhibits other curious features of asymmetry, and in it I have been able for the first time to work out the blood supply of the paraphysis. The specimen in question was examined by means of transverse sections; a large number of camera drawings were made showing the disposition of the vessels—which are remarkably distinct—and these were combined into two diagrams, in each of which the vessels concerned are represented as being projected on to the transverse plane of one of the sections; the more anteriorly situated vessels are thus shown in one diagram (text-fig. 17), and the more posteriorly situated in the other (text-fig. 18). The vessels are drawn as if seen from behind.

Arterial System.

The left posterior cerebral (text-figs. 17, 18, *a. c. p.*, on left side), after giving off the anterior pineal, divides as usual into the left superior cerebral (text-fig. 17, *a. c. s.*), and the left saccular (*a. s.*).



17.

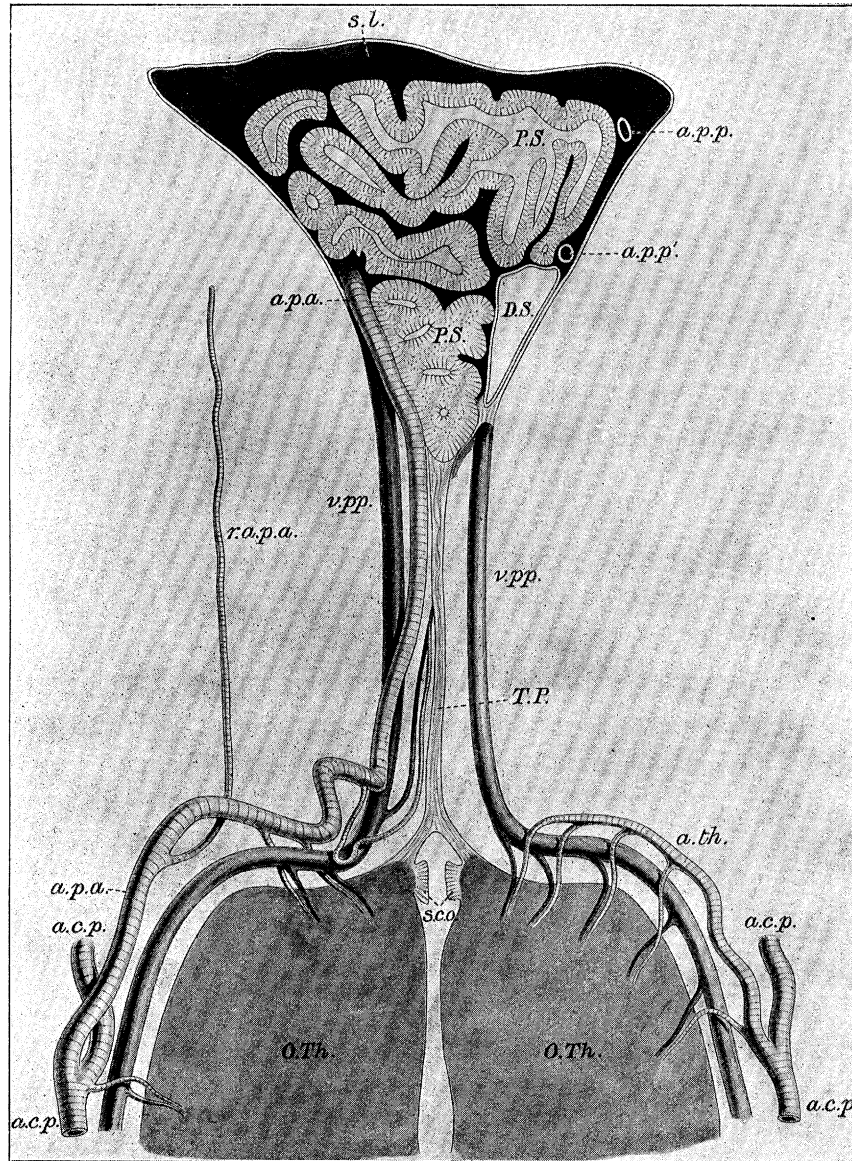
TEXT-FIG. 17.—Diagram of the more Anterior Blood-vessels of the Pineal Complex of Sphenodon VI, projected onto a transverse section.

(For explanation of lettering see pp. 327–329.)

For simplicity the choroid plexus is represented on the right side only.

The left saccular takes an almost straight course upwards alongside the wall of the dorsal sac, just behind the paraphysis, but does not come into contact with the wall until it reaches its upper limit, alongside the choroid plexus. At this point it is

thrown into a large **S**-shaped loop, and becomes more or less embedded in the pial investment of the pineal complex. It then turns sharply forwards and, still embedded in the pia, continues on till it reaches the left antero-dorsal angle of the paraphysis, where it becomes continuous with the large anastomosing paraphysial branch (*r. p. a.*)



18.

TEXT-FIG. 18.—Diagram of the more Posterior Blood-vessels of the Pineal Complex of Sphenodon VI, projected onto a transverse section.
(For explanation of lettering see pp. 327–329.)

of the right anterior choroidal artery, to be described presently. One or two small twigs are given off from the top of the **S**-shaped loop to the left side of the choroid plexus, but the chief blood-supply of the latter is from the right saccular artery.

At some considerable distance in front of the point of separation of the left saccular artery from the left superior cerebral, the latter gives off the left anterior choroidal artery (*a. ch. a.*), having previously given off at least one branch to the cerebral hemisphere. The left anterior choroidal at first curves upwards and inwards till it comes in contact with the wall of the paraphysis and then turns downwards alongside the paraphysis, giving off small branches to the latter (*r. p.*) at various points in its course. At about the level of the opening of the paraphysis into the dorsal sac it gives off an important branch, which I propose to term the superior thalamic artery (*a. th. s.*), and then runs on downwards to the lateral choroid plexus just in front of the *commissura aberrans*.

The left superior thalamic artery at first runs downwards almost to the anterior ventral angle of the dorsal sac and then turns sharply backwards and runs for a considerable distance in a horizontal direction alongside the lower part of the dorsal sac till it reaches about the level of the habenular ganglion. It then turns sharply forwards again, running parallel to and beneath its former course, in the fissure between the optic thalamus and cerebral hemisphere (as shown in the text-figure). It can be traced forwards as far as the foramen of Monro and it supplies the optic thalamus.

The anterior pineal artery (*a. p. a.*), which is unpaired, arises, as shown in text-fig. 18, directly from the left posterior cerebral artery considerably below the origin of the left saccular, and runs upwards to the lower extremity of the pineal sac. Having joined the latter, it continues upwards along its left side for some distance and then turns forwards and becomes hidden in the folds of its wall, still on the left side of the middle line. In this position it is conspicuous in transverse sections of the pineal sac (text-figs. 13-17, *a. p. a.*), and it can be traced forwards to the pineal eye, giving off branches to the pineal sac along its course. The most conspicuous of these is a recurrent branch which comes off from the anterior pineal artery immediately in front of the anterior extremity of the pineal sac, and runs backwards above the latter and on the right-hand side of the middle line for a considerable distance (text-figs. 13-15 and fig. 52, *r. b. p. a.*).

In front of the pineal sac the anterior pineal artery accompanies the left pineal nerve to the pineal eye, as shown in the series of transverse sections represented in figs. 47 to 52. Anteriorly it divides into a number of small branches, from which arise the capillaries which ramify in the connective tissue between the inner and outer capsules of the pineal eye, but without entering the eye itself.

The anterior pineal artery also gives off, a little above its origin from the left posterior cerebral, a considerable branch (text-fig. 18, *r. a. p. a.*) which runs upwards, at first free and then in the upper part of the wall of the dorsal sac behind the left saccular, and, amongst other smaller branches given off in the same neighbourhood, one which accompanies the *tractus pinealis* (right pineal nerve) upwards and probably enters the pineal sac at its lower extremity

(text-fig. 18). It also supplies twigs to the optic thalamus, as shown in the same figure.

On the right side of the same specimen the arrangement of the arteries of the pineal complex is conspicuously different in some respects. The right saccular (text-fig. 17, *a. s.* on right side) runs upwards to the right hand side of the choroid plexus of the dorsal sac (*c. p. B.*), its upper portion being very sinuous. It gives off branches inwards to the choroid plexus and to the upper part of the paraphysis as shown in the diagram, and then continues upwards for a short distance as the posterior pineal artery, which at once divides into two branches (*a. p. p.* and *a. p. p¹*). Each of these branches turns backwards to supply the right side of the posterior part of the pineal sac (compare text-fig. 18).

The right anterior choroidal artery (text-fig. 17, *a. ch. a.* on right side) is given off from the right superior cerebral (*a. c. s.*) at about the same level as the corresponding artery on the left side, but instead of curving upwards at once to meet the wall of the paraphysis it turns sharply down and forms a pendent loop, from the bottom of which the right superior thalamic artery (*a. th. s.* on right side) is given off. The ascending limb of this loop runs upwards to about the level of the paraphysial opening and then turns down again and runs alongside the lower part of the dorsal sac to the lateral choroid plexus in front of the *commissura aberrans*.

From the top of the ascending limb is given off a large branch which I propose to call the anastomosing paraphysial artery (*r. p. a.*). This takes a sinuous course obliquely upwards and round the front of the paraphysis to join the left saccular artery. It is more or less imbedded in the pial investment of the paraphysis, and gives off small branches to the latter at various points along its course.

There is no anterior pineal artery at all on the right side; a considerable branch, however, comes off from the right posterior cerebral in a position corresponding to that of the anterior pineal artery of the left side, and gives off a number of small twigs to the optic thalamus, as shown in text-fig. 18 (*a. th.*).

The membranous wall of the dorsal sac, apart from its choroid plexus, is not highly vascular, but it does contain a number of small vessels, some of which enter or leave it by way of the underlying nervous tissue of the brain (optic thalami and habenular ganglia) (*vide* fig. 54, *B. V.*).

Venous System.

The veins associated with the pineal complex are, as I have pointed out in my previous work, the *sinus longitudinalis*, the *venæ choroideæ anteriores* and the *venæ parapineales*. It is, however, doubtful whether either the anterior choroidal or the parapineal veins receive any blood from the pineal complex, with which their association appears to be merely one of juxtaposition. I may take this opportunity, nevertheless, of adding certain further details concerning these vessels.

The two parapineal veins (text-fig. 18, *v. pp.*) are made up, principally at any

rate, of branches from the optic thalami, which I had not observed when I published my memoir on the intracranial vascular system.

The left anterior choroidal vein (text-fig. 17, *v. ch. a.* on left side), in *Sphenodon VI*, does not receive the large *vena terminalis*, as it sometimes does. This latter vessel is, however, very conspicuous immediately in front of the *lamina terminalis*, between the two paraterminal bodies of ELLIOT SMITH, but cannot be traced far as a well-defined vessel. There is a rich plexus of veins in this neighbourhood, the relations of which are very complex, and I have not followed them out completely, but it appears to be drained by one or more of the more posteriorly situated superior cerebral veins.

The wall of the paraphysis contains a beautiful network of capillaries (as shown in text-fig. 17 and fig. 76), which occupies the interspaces between the paraphysial tubules, and which discharges its venous blood directly into the irregular sinuses (parts of the *sinus longitudinalis*) which lie beneath the pineal sac (text-fig. 17). A portion of the venous blood from the paraphysis may possibly be discharged into the upper parts of the anterior choroidal veins, but I have not been able to determine this point with certainty, and it is obviously a matter of small importance, as the anterior choroidal veins themselves open soon afterwards into the *sinus longitudinalis*.

The venous blood from the choroid plexus of the dorsal sac (text-fig. 17, *c. p. B.*) is returned to the *sinus longitudinalis* partly by small veins (text-fig. 17) which open into the blood spaces beneath the pineal sac and behind the paraphysis, and partly through the capillary network of the paraphysis where this intervenes between the choroid plexus and the pineal sac.

The antero-dorsal limb of the V-shaped pineal sac is almost completely surrounded by the *sinus longitudinalis*, which penetrates beneath it and into the folds of its wall in the form of irregular blood-channels (text-figs. 17, 18). The venous blood from the walls of the pineal sac is no doubt returned through these channels. In *Sphenodon VI* the parapineal veins also open into these irregular blood-spaces at the sides of the hinder part of the pineal sac, instead of running up to open independently into the main longitudinal sinus as they sometimes do.

Anteriorly, the *sinus longitudinalis* forms an irregular loop which extends forwards beneath the pineal eye, and through which the nerve and artery of the pineal eye pass. This loop appears to be connected with small irregular sinuses which drain the immediate neighbourhood of the pineal eye (*vide* figs. 47–52).

VII.—THE PARIETAL PLUG AND OVERLYING INTEGUMENT.

When the skin is stripped from the head of a freshly killed tuatara, the parietal foramen is seen to be occupied by a plug of gelatinous-looking tissue, which evidently corresponds to the closely similar structure which I have termed the “parietal

plug" in the case of Geotria (1907, α). In Sphenodon I this plug was conspicuous by its great transparency, projecting from the parietal foramen like a convex lens, with a well-defined circular outline. The parietal foramen, on the other hand, has the form of an elongated slit, so that the shape of the parietal plug is by no means entirely determined by that of the foramen in which it lies.

The parietal plug was also observed in the fresh condition in other specimens, but in no other case did it appear so remarkably transparent as in Sphenodon I. In all cases, however, it is doubtless capable of transmitting a certain amount of light to the underlying pineal eye. To the naked eye it appears sharply differentiated from the surrounding much more opaque connective tissue, and, as I have already pointed out, it can, after hardening, be readily dissected out in its entirety from the parietal foramen, when it exhibits the appearance shown in fig. 6, having the form of a concavo-convex lens with rounded margin, the concavity, which lodges the pineal eye, being situated on its inner (lower) aspect.

In sections the parietal plug is seen to be firmly united all round to the surrounding connective tissue, and it is not possible to find a sharp line of delimitation between the two (figs. 1, 7). The histological structure of the plug itself is, however, quite distinctive. It is composed of a mass of lightly staining connective tissue, in which the numerous slender fibres radiate outwards more or less at right angles to the outer convex surface of the plug (figs. 3, 6). Associated with these fibres occur numerous nuclei, for the most part elongated in the same direction, and apparently belonging to the fibres themselves. Others of the nuclei, however, clearly belong to stellately branched connective-tissue cells, which occur abundantly amongst the fibres, and from which the fibres are doubtless derived. This tissue is not very compact, and it is probable that in life a gelatinous matrix fills the interspaces between the fibres. Large shrinkage cavities sometimes appear in it during the process of preparation.

All round the periphery of the parietal plug, the characteristic tissue described above passes into a much more dense, deeply staining connective tissue, in which the fibres and nuclei are disposed parallel to the surface of the plug. This denser form of tissue is very strongly developed around the concavity on the under surface of the plug, immediately above the pineal eye, and it is from here that the radiating fibres of the plug appear to take their origin (fig. 3). As already pointed out, the outer surface of the lens of the eye is closely pressed against this dense connective tissue, into which the outer and inner capsules of the eye merge indistinguishably, as shown in figs. 2 and 3.

Above the parietal plug, between it and the epidermis, the denser connective tissue which surrounds the plug passes into the ordinary connective tissue of the dermis.

The parietal plug first appears in development at Stage S, as a thickening and differentiation of the deeper layer of mesoblast beneath the true dermis, as shown in

fig. 45 (with which compare fig. 26, Stage R, with no indication of the parietal plug yet visible). It is directly continuous with the dense connective tissue sheath of the supra-occipital cartilage, and is probably to be regarded as part of the connective tissue of the cranial wall. The connective tissue in the interior of the plug, however, has already begun to exhibit its characteristic radial arrangement, and its staining reactions are quite different from those of the dense perichondrial tissue. The latter has stained deeply orange with the orange G employed, the former has stained faintly blue with the hæmatoxylin and shows no orange colour. In both, of course, the nuclei are stained dark blue.

When the integument which has been stripped off from the top of the head is held up to the light, it is at once evident that there is in it a conspicuously translucent patch, which corresponds in position to the underlying parietal plug. This patch, however, is not definitely circumscribed. Like the rest of the integument in this region, it is covered with small, irregular, polygonal scales, which, however, are, at any rate sometimes, distinguished from the surrounding scales by their more or less flattened, instead of strongly convex, surfaces,* and by the absence of larger scales amongst them. SPENCER (1886) notes the comparatively unpigmented character of the skin in this region, but this seems to be a variable character.

Although sufficiently translucent to admit of the passage through them of a good deal of light, the scales are by no means perfectly transparent, and it is obvious that the irregularity of their shape and arrangement must render the focussing of a definite image of external objects upon the retina of the pineal eye impossible. Between the epidermis and the parietal plug, the dense white connective tissue of the dermal layer appears to thin away over the area in question.

VIII.—THE MORPHOLOGICAL INTERPRETATION OF THE PINEAL ORGANS.

A. *The Bilateral Theory of the Pineal Organs.*

Several investigators have from time to time put forward the view that the pineal organs (pineal eye and pineal sac) originally formed a pair, and that the antero-posterior relation which they now bear to one another is a secondary feature. I have myself adopted this view and brought forward what appears to me to be very strong evidence in favour of it in connection with my earlier work on the development of these organs in *Sphenodon* (DENDY, 1899, *b*) and on the corresponding organs in *Geotria* (DENDY, 1907, *a*). The theory, however, can hardly be said to have met with general acceptance. Thus STUDNIČKA, in his often quoted monograph (1905), treats it as extremely questionable. He observes (p. 3): “Gegen eine solche Annahme spricht, und zwar, wie es uns scheint, sehr gewichtig der Umstand, dass die Verhältnisse der Innervation beider Organe ziemlich verschieden sind, jedes von

* This distinction is by no means an absolute one, for the surrounding scales are not by any means always strongly convex.

ihnen zeigt ursprünglich zu einer anderen Kommissur eine Beziehung." Accordingly, in the series of diagrammatic figures representing the condition of the pineal organs in the principal Vertebrate groups, which he gives at the end of his work, he adopts the view that the relationship of the pineal eye and pineal sac to one another is fundamentally an antero-posterior one.

STUDNIČKA'S criticism of what, for the sake of brevity, I will term the bilateral theory of the pineal organs is, perhaps, the most serious that has yet been made, but the obvious answer to it is that the connection of the *tractus pinealis* with the posterior commissure is a purely secondary one, and that the primary connections of the two pineal nerves were with the right and left habenular ganglia respectively. I think this will be sufficiently clear from the following summary of the evidence:—

(a) *Evidence Derived from the Study of Sphenodon*.—*Sphenodon* supplies us with evidence in favour of the bilateral theory from the embryological, morphological and histological points of view. The embryological evidence I have already dealt with in part in my earlier work (1899, *b*), but I may briefly recapitulate and amplify what I there said. The first indication of the development of the pineal organs is seen in the appearance of what I have termed the primary parietal vesicle as an evagination from the roof of the fore-brain at Stage K. This vesicle lies, in the cases observed by me, a little to the left of the middle line, and overlaps the brain-roof both anteriorly and posteriorly. Its appearance at Stage L is represented in fig. 29. At the next stage observed two vesicles are present, one in front of the other. At first their walls are directly continuous and their cavities communicate freely (fig. 30). Very soon, however, the vesicles become completely constricted off from one another (fig. 31). The anterior one usually lies distinctly to the left of the posterior one; it will give rise to the pineal eye, while the posterior one will give rise to the pineal sac. Exactly how these rudiments of the pineal eye and pineal sac are related to the primary parietal vesicle is not yet quite clear;* it seems probable that they are formed by constriction of the latter into two parts, but in any case the position of the eye-vesicle to the left of the other is very significant. As development goes on, however, the pineal eye shifts completely into the middle line.

In the present memoir I have demonstrated that the nerve of the pineal eye also arises on the left side of the middle line, and is connected with the left habenular ganglion of the embryo (figs. 36–40, 43, text-figs. 8, 9), and although in the adult its connection with this ganglion has not, for reasons already explained, been actually demonstrated, I have been able to show that throughout a great part of its course it lies conspicuously on the left side of the middle line (text-figs. 13–16, etc.), and that the connection with the left habenular ganglion is almost certainly still maintained (figs. 54, 61). I have also shown that the left habenular ganglion itself differs from the right one in the extent to which it is elongated upwards before meeting the wall of the dorsal sac (fig. 54).

* See, however, postscript, pp. 329–331.

That the pineal eye in *Sphenodon* is primarily an organ of the left side is, I think, conclusively established. As regards the pineal sac, it must be admitted that the case is by no means so clear. From their first appearance both the sac itself and its nerve appear to be strictly median in position, and the nerve certainly appears to be connected with the posterior commissure, though it seems to be equally clearly related to the habenular ganglia and superior commissure, at any rate in the adult (figs. 56, 57, 62).

It is when we come to examine the histological structure of the wall of the pineal sac, and find that, as I have shown in the preceding pages, it is essentially identical with the very characteristic structure of the retina of the pineal eye, that we see the strongest reason, so far as *Sphenodon* itself is concerned, for regarding these two organs as bilaterally homologous. The pineal sac has, I believe, undergone a remarkable change both as regards position and function, which may sufficiently account for the fact that its nerve is apparently no longer especially related to the right habenular ganglion.

The case of *Sphenodon* cannot, however, be considered alone, and when we come to examine other types we shall find the evidence enormously strengthened.

(b) *Evidence derived from the Study of other Types: a. Cyclostomes.*—The lampreys furnish us with peculiarly satisfactory evidence in favour of the bilateral theory, because in these animals it is the *right* and not the *left* pineal organ which is developed as a pineal eye, while the left one (“parapineal organ”) remains in a vestigial condition. Moreover, in the type examined by myself (*Geotria*) I have been able to demonstrate that the nerve of the right-hand member of the pair is especially connected with the right habenular ganglion, though it also appears to send fibres to the posterior commissure. I quote the following summary of the evidence derived from the study of *Geotria* from my memoir on that animal (DENDY, 1907, *a*), with slight verbal alterations:—

(1) The “parapineal” organ, in its position to the left of the pineal (eye), still shows evidence of its primitive paired character.

(2) The structure of the pineal and “parapineal” organs is essentially identical, although the former is much more highly developed than the latter.

(3) Each of these two sense-organs is connected with the corresponding member of the habenular ganglion-pair.

(4) The marked asymmetry in point of size of the two habenular ganglia and of the two bundles of Meynert corresponds exactly to the unequal development of the two pineal sense-organs with which they are respectively connected, and leaves no doubt as to the paired character of the whole system.

It thus appears that the evidence supplied by the lamprey supplements that derived from the study of *Sphenodon* in exactly the way required. The one is complementary to the other, and taken together I think they leave no reasonable doubt as to the truth of the bilateral theory.

β. Other Vertebrates.—With the exception of certain fishes, to be referred to later, our knowledge of the pineal organs in other Vertebrates is hardly sufficiently accurate to be of much value from the point of view of the bilateral theory. Thus, DE KLINCKOWSTRÖM (1893) described the nerve of the pineal eye in embryos of Iguana, and traced it to the *right* habenular ganglion, but he sometimes found another nerve joining the pineal eye with the *left* habenular ganglion, and in one case he found a nerve joining the “epiphysis” (pineal sac) to the posterior commissure. In view of what we now know of Sphenodon, it would be a very remarkable thing if the pineal eye in Iguana were really specially related to the right habenular ganglion, and these results require confirmation.

Other writers who have dealt with the nerve of the pineal eye in Lacertilia have been content to describe it as joining the brain-roof in the neighbourhood of the habenular commissure, presumably in the middle line. The most recent of these are NOWIKOFF (1907) and SCHMIDT (1909), who figure the junction of the nerve with the habenular or superior commissure in sagittal sections of Lacerta. Sagittal sections are, however, of very little use for determining the question whether the nerve is really median or not, and I cannot help thinking that, had it been carefully followed from the eye to the brain in a series of transverse sections, it would have been found to lie on the left side, as in Sphenodon.*

CAMERON (1902–4) has obtained a certain amount of evidence that the “epiphysis” in Amphibia and in the chick is a bilateral structure, but it is not nearly so satisfactory as that which is afforded by the work of C. HILL (1891 and 1894) on the development of the ganoid *Amia* and certain genera of Teleostean fishes. I have already referred to HILL’S remarkable results on several occasions, and shall therefore deal with them very briefly in this place. He showed that in these forms (*e.g.*, *Coregonus*) the embryo possesses right and left pineal vesicles, originating as paired outgrowths from the roof of the fore-brain, and that the right one gives rise to the adult pineal organ, comparable to the pineal sac of Sphenodon, while the left is vestigial. Moreover, the left one may be placed more anteriorly than the right one, as in Sphenodon and the Cyclostomes, and HILL gives a figure of the two organs in the embryo of *Coregonus*, which bear an astonishing resemblance to the condition found at a corresponding stage in Sphenodon. Neither organ, however, ever develops an eye-like structure.

LOCY again (1894, *a*, *b*) derives the pineal organ of the Elasmobranch genus *Acanthias* from a pair of “accessory optic vesicles,” but it must be admitted that his results are not so conclusive as those of HILL.

Even in fossil fishes, as I have already pointed out (1907, *a*), we find a certain amount of evidence in favour of the bilateral theory of the pineal organs, especially in the paired character of the pineal foramen in *Titanichthys*. Whatever may be the value of the evidence derived from other types, however, the cases of *Geotria*,

* See, however, the postscript at the end of the present memoir (pp. 329–331).

Coregonus and Sphenodon appear to me to be sufficiently convincing with regard to the question under discussion.

B. *The Theory of the Serial Homology of the Pineal Organs with the Lateral Eyes.*

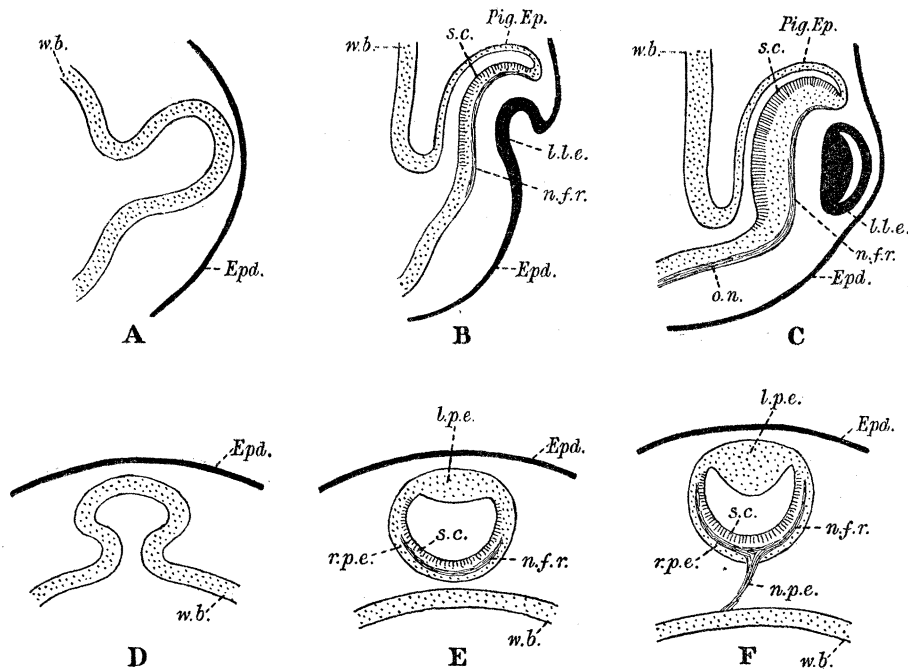
If we once admit that the pineal sense-organs are to be regarded as dislocated members of a pair, there seems no valid reason why we should not push our conclusions a little further and follow LOCY (1894, *a*, *b*) in regarding them as serially homologous with the lateral eyes. LOCY's conclusions were, as is well known, originally based upon his observation of the occurrence, on the yet unclosed neural plate of Acanthias, of two pairs of symmetrically developed "accessory optic vesicles" behind those which give rise to the lateral eyes, the pineal organ being derived from the middle pair of the three. These results undoubtedly require confirmation, but I think some of the facts which I have brought forward in the present memoir tend to strengthen his position. I have pointed out, in discussing the question of the neuromery of the fore- and mid-brain that we can recognise no fewer than six pairs of hollow outgrowths from these parts of the brain in Sphenodon, viz., the cerebral hemispheres, the optic vesicles of the lateral eyes, the *recessus thalami prænucleares*, the pineal outgrowths, the *recessus geniculorum*, and the optic lobes, and that each pair may perhaps be taken to indicate an originally distinct neuromere, while all six may be serially homologous.

VON KUPFFER (1906, p. 161) objects to the view that the pineal outgrowths (and also the more posterior of LOCY's accessory optic vesicles) are serially homologous with the optic vesicles of the lateral eyes, on the ground that the former arise dorsally and the latter ventrally, but I cannot see that there is much force in this objection, especially as it has been stated on good authority (JOHNSTON, 1906) that the optic vesicles of the lateral eyes arise from the dorsal part of the second neuromere. Subsequent displacement might very well be brought about by inequality of growth of the wall of the brain during the course of development, and precisely the same objection might be raised to the serial homology of the fourth pair of cranial nerves (pathetic) with the third (*motores oculorum*) and sixth (*abducentes*), a homology which, of course, is universally admitted.

Another objection might be based upon the difference in structure between the pineal and lateral eyes. It has often been insisted upon that the former is an eye of the so-called "Invertebrate" type, and therefore differs greatly from the latter. It is easy to demonstrate, however, that this difference is apparent rather than real, and when we eliminate obviously secondary modifications, a fundamental identity between the two becomes clearly manifest (see text-fig. 19).

Each originates as a hollow outgrowth of the fore-brain; in each the sensory elements are derived from the lining (ependymal) epithelium; in each the nerve-fibres and ganglion-cells lie on what is morphologically the outer side of the sensory layer;

in each the nerve-fibres probably grow back from the ganglion-cells of the retina to the brain, and in each pigment is deposited in that part of the wall of the optic vesicle which lies nearest to the brain. Here the resemblance for the most part ceases, and the structure of each is complicated by special modification along lines of its own. In the pineal eye the front wall typically thickens to form a lens, which may also secrete part, at any rate, of the vitreous humour, while the retina is formed from the part of the wall next to the brain. In the lateral eye the part of the wall of the optic vesicle next to the brain gives rise only to the pigment epithelium, the nervous and sensory elements of the retina being formed from the front wall, which



TEXT-FIG. 19.—Diagrammatic Comparison of the Development of a Pineal Eye (lower figures) with that of a Lateral Eye (upper figures). (For the sake of simplicity, the complication introduced by the development of the two pineal organs in continuity with one another is omitted; compare figs. 29–31.)

(For explanation of lettering see pp. 327–329.)

invaginates to form the optic cup; the lens is an entirely new formation derived from the superficial epiblast, and the outer coats of the eye are added from the mesoblast. The pineal eye has remained in a relatively low stage of development, and in most cases at the present day it is probably actually degenerate, while the lateral eye has continued to progress with the evolution of the Vertebrates. The resemblance of the pineal eye to any Invertebrate type of eye is, however, entirely superficial, for the Invertebrate eye is never formed as an outgrowth of the brain, but always from the superficial epiblast.*

* Compare, however, PATTEN (1890) for an attempt to get over this difficulty in the case of the Arthropod eye.

C. *The Comparison of the Pineal Eye with the Median Eyes of Arthropods.*

Several writers have drawn a comparison between the pineal eye of Vertebrates and the median eyes of Arthropods, and PATTEN (1890) and GASKELL (1890, 1908), in particular, have made use of this comparison in support of their theories of the origin of Vertebrates from Arthropod ancestors.*


This question has lately been under discussion at meetings of the Linnean Society, and I then had the opportunity (1910) of expressing my views on the comparison in question, so that it is unnecessary to go into the subject in detail in this place. I may state again, however, that my investigation of the minute structure of the pineal eye in *Sphenodon* lends no support to the Arthropod theory of Vertebrate ancestry, and the same is true of my researches on *Geotria* (1907, *a*). GASKELL has himself pointed out (1908) that the median eyes of Arthropods "are in all cases eyes with a simple upright retina and a simple cuticular lens," a description which will not fit any pineal eye known to us. In the pineal eye—in Cyclostomes, Lacertilia and *Sphenodon*—there is a cellular lens (when a lens is present at all), and the retina is of the so-called compound type, that is to say, it contains ganglion-cells. GASKELL (1908, 1910) has endeavoured to explain away the importance of these ganglion-cells by comparing them to what LANKESTER and BOURNE (1883) have described as connective tissue cells in the median eye of *Limulus*. The ganglion-cells in the retina of the pineal eye are, however, certainly not connective tissue cells; while GASKELL'S ingenious suggestion, that in the Lamprey they may be ganglion-cells which have migrated along the pineal nerve, does not meet with the slightest support from the study of *Sphenodon*, in which they certainly develop *in situ* in the retina. In short, the retina of the pineal eye is undoubtedly a compound retina, in the sense that it contains a well-developed layer of ganglion-cells, and this fact cannot be ignored or explained away in any comparison with the median eyes of Arthropods. The two types of eye, indeed, are fundamentally different in structure, as a comparison of LANKESTER and BOURNE'S figure of the median eye of *Limulus* (1883, Plate XII, fig. 27) with any modern figure of the pineal eye of a lamprey or lizard, or a tuatara, will at once demonstrate, to say nothing of the differences in their development.

IX.—THE SUB-COMMISSURAL ORGAN AND REISSNER'S FIBRE.

The sub-commissural organ (= "ependymal groove") and Reissner's fibre are both very strongly developed in the Tuatara, and have the usual structure and relations. The former occurs in the form of a deep longitudinal groove, horseshoe-shaped in transverse section, lying beneath the posterior commissure (text-figs. 10, 12, 18, 20, *s. c. o.*). It commences at the infra-pineal recess (figs. 56, 62) and ends somewhat abruptly (in the adult) near the posterior limit of the posterior commissure (fig. 62). Its appearance in transverse section clearly indicates that it is made up of two bands

* See also LEYDIG (1891).

of modified ependymal epithelium, right and left, united in the middle line. The abruptness with which this epithelium is marked off from the ordinary ependymal epithelium of the *iter* is very remarkable, and is very clearly shown in the photograph reproduced in text-fig. 20. It will be noticed that there is a conspicuous fold in the ordinary ependymal epithelium just where it joins the sub-commissural organ on either side, obviously due to the great development of the latter in a dorsi-ventral direction; this is probably a very constant character, for a very similar fold occurs in *Geotria* (DENDY, 1907, *a*) and in the mouse (DENDY and NICHOLLS, 1910). In fact the sub-commissural organ appears to have a remarkably uniform structure throughout the Vertebrate series, until it becomes more or less obsolete in the higher primates.



TEXT-FIG. 20.—Transverse Section through the Posterior Commissure and Sub-Commissural Organ of *Sphenodon* VI. (From a photograph.)
(For explanation of lettering see pp. 327–329.)

The sub-commissural organ exhibits the usual histological structure. It is composed of very greatly elongated columnar cells, almost deserving the name of fibres, placed side by side at right angles to the surface and with crowded nuclei lying at various levels, but always at some distance from the free surface. Tangential sections of the epithelium, taken between the nuclei and the free surface, exhibit a characteristic punctate appearance, the dots being evidently the transverse sections of the separate very slender cell-bodies. This is very well shown in the section of an embryo of Stage S represented in fig. 46.

The free surface of the epithelium appears to be covered in life with a thick coating of short cilia, the remains of which are clearly visible in thin sections, exactly as I described in the case of *Geotria* (DENDY, 1907, *a*).

The epithelial cells themselves are not all of the same length, but become gradually shorter towards the dorsal and ventral boundaries of the groove (text-fig. 20). Their nuclei are conspicuously elongated, and are thereby readily distinguishable from a number of spherical nuclei which lie between the inner extremities of the columnar cells, or just outside them in the punctate substance of the brain. These latter appear to be the nuclei of small nerve-cells, and I think it not improbable that future investigations will show that they are connected with some of the columnar cells of the sub-commissural organ.

At Stage S, as represented in fig. 45, the rapid growth of the posterior commissure, aided perhaps by the shortening of the brain-roof in the straightening out of the cerebral flexure, has caused both the commissure itself and the epithelium which covers it to become transversely folded. In this way the commissure and sub-commissural organ come to project conspicuously into the brain-cavity, while the hinder end of the sub-commissural organ becomes tucked in as a mesocœlic recess (*Mes. R.*), such as occurs in the frog and certain fishes, and such as has recently been described in the chimpanzee and man (DENDY and NICHOLLS, 1910). There is, however, another little involution of the epithelium immediately behind the mesocœlic recess, not shown in the particular section figured, which is less easy to account for, and it is very difficult to say where the sub-commissural organ really begins.

In the adult the posterior commissure appears to some extent to have straightened out again (fig. 62). It is much less prominent than at Stage S, and the mesocœlic recess seems to have disappeared, while the sub-commissural organ appears to begin (at its posterior end) very abruptly, and more anteriorly than at Stage S.

Reissner's fibre is very clearly shown in several of my section-series, both transverse and longitudinal. Anteriorly I have found it in the adult in the groove of the sub-commissural organ, in close contact with the epithelium, but I have not observed its subdivision into branches. I have no doubt, however, that it does subdivide as in other types (*e.g.* *Geotria*, DENDY, 1907, *α*), and that the branches are connected with the ependymal epithelium.

The course of Reissner's fibre through the brain is shown in text-fig. 12. From the sub-commissural organ it passes backwards through the *iter*, keeping near the middle line, beneath the inward projection of the cerebellum, where it lies in a longitudinal furrow on the ventral aspect of the latter, and then through the fourth ventricle to the *canalis centralis* of the spinal cord. I have not traced it down the cord further than the extent of the very short piece included in my sections.

In *Sphenodon* I, where Reissner's fibre can be traced for a long distance in transverse sections, and appears to be in a normally stretched condition, it measures about 2μ in diameter. In *Sphenodon* V a long uninterrupted piece of the fibre is visible beneath the cerebellum in a longitudinal section, but it has become disconnected from the sub-commissural organ and has sprung back into the fourth ventricle, where it measures up to about 5μ in diameter, having doubtless thickened

in contracting, but it does not appear to have "snarled," unless indeed a snarl has dropped out of the sections. I have not attempted to follow the development of Reissner's fibre and the sub-commissural organ in any detail, but I may say that the latter is already well developed at Stage R (text-fig. 10 and fig. 43), while the former is conspicuous in a sagittal section of Stage S (Embryo II).

I have already expressed the opinion that Reissner's fibre is not nervous in character as maintained by SARGENT (1904), but that its function is a mechanical one. I have suggested (DENDY, 1909, *b*, DENDY and NICHOLLS, 1910) that, together with the sub-commissural organ, it may form an apparatus for regulating automatically the flexure of the body. At present I can see no better explanation of this remarkably constant feature of the Vertebrate central nervous system. It is unnecessary, however, to discuss the matter further in this place, especially as my colleague, Mr. G. E. NICHOLLS, is engaged upon a detailed investigation of the whole problem of Reissner's fibre and the sub-commissural organ, which will, I hope, throw much light upon the subject. I am indebted to Mr. Nicholls for valuable assistance in revising the proof-sheets of the present memoir.

X.—REFERENCE LIST OF LITERATURE.*

1892. BÉRANEK, E. "Sur le nerf pariétal et la morphologie du troisième œil des vertébrés," 'Anat. Anz.,' Jahrg. 7.
- 1896, *a*. BERNARD, H. M. "The Sense of Sight: Sketch of a New Theory," 'Ann. and Mag. Nat. Hist.,' Ser. 6, vol. 17.
- 1896, *b*. *Idem*. "An Attempt to Deduce the Vertebrate Eyes from the Skin," 'Quart. Journ. Micro. Sci.,' vol. 39, N.S.
1894. BURCKHARDT, R. "Die Homologien des Zwischenhirndeckes bei Reptilien und Vögeln," 'Anat. Anz.,' Jahrg. 9.
- 1902-3. CAMERON, J. "On the Origin of the Pineal Body as an Amesial Structure, deduced from the Study of its Development in Amphibia," 'Proc. Roy. Soc. Edin.,' vol. 24.
- 1903-4. *Idem*. "On the Origin of the Epiphysis Cerebri as a Bilateral Structure in the Chick," 'Proc. Roy. Soc. Edin.,' vol. 25.
- 1899, *a*. DENDY, A. "Outlines of the Development of the Tuatara, *Sphenodon (Hatteria) punctatus*," 'Quart. Journ. Micro. Sci.,' vol. 42, N.S.
- 1899, *b*. *Idem*. "On the Development of the Parietal Eye and Adjacent Organs in *Sphenodon (Hatteria)*," 'Quart. Journ. Micro. Sci.,' vol. 42, N.S.
1906. *Idem*. "On the Pineal Sense Organs and Associated Structures in *Geotria* and *Sphenodon*," 'Brit. Ass. Report,' York, 1906.

* The reader is referred to STUDNIČKA's work (1905) for a more complete bibliography of the pineal organs.

- 1907, *a.* DENDY, A. "On the Parietal Sense Organs and Associated Structures in the New Zealand Lamprey (*Geotria australis*)," 'Quart. Journ. Micro. Sci.,' vol. 51, N.S.
- 1907, *b.* *Idem.* "The Pineal Gland," 'Science Progress,' No. 6.
- 1909, *a.* *Idem.* "The Intracranial Vascular System of Sphenodon," 'Phil. Trans. Roy. Soc.,' B, vol. 200.
- 1909, *b.* *Idem.* "The Function of Reissner's Fibre and the Ependymal Groove," 'Nature,' vol. 82, December 23, 1909.
1910. *Idem.* In discussion on "The Origin of Vertebrates," 'Proc. Linn. Soc. Lond.,' 1909-10.
1910. DENDY, A. and NICHOLLS, G. E. "On the Occurrence of a Mesocoelic Recess in the Human Brain, and its Relation to the Sub-Commissural Organ of Lower Vertebrates; with Special Reference to the Distribution of Reissner's Fibre in the Vertebrate Series, and its possible Function," 'Proc. Roy. Soc.,' Series B, vol. 82.
1899. EDINGER, L. "Untersuchungen über die vergleichende Anatomie des Gehirnes. 4.—Studien über das Zwischenhirn der Reptilien," 'Abhand. Senckenberg. Naturforsch. Gesell.,' Bd. 20, Heft 2.
1909. EIGENMANN, C. H. "Cave Vertebrates of America," Carnegie Institute of Washington.
1890. GASKELL, W. H. "On the Origin of Vertebrates from a Crustacean-like Ancestor," 'Quart. Journ. Micro. Sci.,' vol. 31, N.S.
1908. *Idem.* "The Origin of Vertebrates," (Longmans, Green & Co., London).
1910. *Idem.* In discussion on "The Origin of Vertebrates," 'Proc. Linn. Soc. Lond.,' 1909-10.
1907. GISI, J. "Das Gehirn von *Hatteria punctata*," 'Zool. Jahrb.,' Bd. 25, Abt. f. Anat.
1891. HILL, C. "Development of the Epiphysis in *Coregonus albus*," 'Journ. Morphol.,' vol. 5.
1894. *Idem.* "The Epiphysis of Teleosts and *Amia*," 'Journ. Morphol.,' vol. 9.
1900. *Idem.* "Developmental History of the Primary Segments of the Vertebrate Head," 'Zool. Jahrb.,' Abt. f. Anat. u. Ont., Bd. 13.
1890. HOFFMANN, C. K. "Reptilia—Epiphyse und Parietalaug," 'Bronn's Klass. und Ordn. d. Thierreichs,' Bd. 6, Abt. 3, S. 1981.
1901. HOWES, G. B., and SWINNERTON, H. "On the Development of the Skeleton of the Tuatara, *Sphenodon punctatus*, with Remarks on the Egg, on the Hatching, and on the Hatched Young," 'Trans. Zool. Soc. Lond.,' vol. 16, Part I.
1906. JOHNSTON, J. B. "The Nervous System of Vertebrates," P. Blakiston's Son and Co., Philadelphia.

1893. KLINCKOWSTRÖM, A. DE. "Le premier développement de l'œil pariétal, l'épiphyse et le nerf pariétal chez *Iguana tuberculata*," 'Anat. Anz.,' Jahrg. 8.
1906. KUPFFER, K. VON. "Die Morphogenie des Central-Nerven-systems," in Hertwig's 'Handbuch der Vergleichenden und Experimentellen Entwicklungslehre der Wirbelthiere,' vol. 2, Part 3.
1883. LANKESTER, E. R., and BOURNE, A. G. "The Minute Structure of the Lateral and Central Eyes of *Scorpio* and of *Limulus*," 'Quart. Journ. Micro. Sci.,' vol. 23, N.S.
1891. LEYDIG, F. "Das Parietalorgan der Amphibien und Reptilien," 'Abhand. Senckenberg. Naturforsch. Gesell.,' Bd. 16.
1896. *Idem.* "Zur Kenntniss der Zirbel und Parietalorgane," 'Abhand. Senckenberg. Naturforsch. Gesell.,' Bd. 19.
- 1894, *a.* LOCY, W. A. "The Optic Vesicles of Elasmobranchs and their Serial Relation to other Structures on the Cephalic Plate," 'Journ. Morph.,' vol. 9.
- 1894, *b.* *Idem.* "The Mid-Brain and the Accessory Optic Vesicles," 'Anat. Anz.,' Jahrg. 9.
1895. *Idem.* "Contribution to the Structure and Development of the Vertebrate Head," 'Journ. Morphol.,' vol. 11.
1907. NOWIKOFF, M. "Über das Parietalauge von *Lacerta agilis* und *Anguis fragilis*," 'Biolog. Centralbl.,' Bd. 27.
1906. PARKER, G. H. "The Influence of Light and Heat on the Movement of the Melanophore Pigment, especially in Lizards," 'Journ. Exper. Zool.,' vol. 3.
1890. PATTEN, W. "On the Origin of Vertebrates from Arachnids," 'Quart. Journ. Micro. Sci.,' vol. 31, N.S.
1904. SARGENT, P. "The Optic Reflex Apparatus of Vertebrates for Short-circuit Transmission of Motor Reflexes through Reissner's Fibre; its Morphology, Ontogeny, Phylogeny and Function. Part I.—The Fish-like Vertebrates," 'Bull. Mus. Comp. Zool. Harvard.,' vol. 45, No. 3.
1903. SCHAUINSLAND, H. "Beiträge zur Entwicklungsgeschichte und Anatomie der Wirbelthiere, I—III," 'Zoologica,' Bd. 16, Heft 39.
1909. SCHMIDT, W. J. "Beiträge zur Kenntnis der Parietalorgane der Saurier," 'Zeitschrift für wissenschaftliche Zoologie,' Bd. 92.
1890. SELENKA, E. "Das Stirnorgan der Wirbelthiere," 'Biolog. Centralbl.,' Bd. 10.
1903. SMITH, G. ELLIOT. "On the Morphology of the Cerebral Commissures in the Vertebrata, with special reference to an aberrant Commissure found in the Forebrain of certain Reptiles," 'Trans. Linn. Soc. Lond.,' vol. 8, Part 12.
1894. SORENSEN, A. D. "Comparative Study of the Epiphysis and Roof of the Diencephalon," 'Journ. Comp. Neurol.,' vol. 4.

1886. SPENCER, W. BALDWIN. "On the Presence and Structure of the Pineal Eye in Lacertilia," 'Quart. Journ. Micro. Sci.,' vol. 27, N.S.
1888. STRAHL, H., and MARTIN, E. "Die Entwicklungsgeschichte des Parietalauges bei *Anguis fragilis* und *Lacerta vivipara*," 'Arch. f. Anat. und Phys.,' Anat. Abt.
1905. STUDNIČKA, F. K. "Die Parietalorgane," In Oppel's 'Lehrbuch der Vergleichenden Mikroskopischen Anatomie der Wirbelthiere.'

XI.—DESCRIPTION OF PLATES.

(All the Figures are of *Sphenodon punctatus*. For explanation of Lettering, see pp. 327–329.)

PLATE 19.

- Fig. 1.—The brain, lying in the cranial cavity, the cranial wall having been removed from the right side; showing the delicate threads of connective tissue which stretch across the large sub-dural space, the natural position of the pineal complex, and the blood-vessels (for explanation of the blood-vessels, which are coloured red, see DENDY [1909, *α*]). (Sphenodon V.) × 6.
- Fig. 2.—A nearly sagittal section through the pineal eye. Stained with Ehrlich's hæmatoxylin and eosin; showing especially the formation of the vitreous body by secretion from the lens. (Sphenodon I.)

PLATE 20.

- Fig. 3.—Sagittal section of the pineal eye and nerve, capsule of the eye, parietal plug, etc. Stained with borax carmine and picro-indigo-carmine. (Sphenodon V.)
- Fig. 4.—Section of the retina of the pineal eye. Stained with Ehrlich's hæmatoxylin and eosin. (Sphenodon I.)
- Fig. 5.—Section of the retina of the pineal eye. Stained with borax carmine and picro-indigo-carmine. (Sphenodon V.)

PLATE 21.

- Fig. 6.—Optical sagittal section of the parietal plug and pineal eye viewed in cedar oil as a transparent object after removal from the parietal foramen, without staining. (Sphenodon V.)
- Fig. 7.—Transverse section through the pineal eye, lying in its capsule beneath the parietal plug. (Sphenodon VI.) × 75.
- Fig. 8.—Nearly sagittal section through the tip of the pineal sac and the capsule of the pineal eye, lying beneath the parietal plug; showing the pigmented diverticulum of the pineal sac, etc. (Sphenodon II.) × 50.

Fig. 9.—The portion of the same section containing the pigmented evagination of the pineal sac, more highly magnified. $\times 220$.

Fig. 10.—Part of another section of the same series showing the small pigment-cells inside and the large branched pigment-cells outside the capsule of the pineal eye. $\times 102$.

PLATE 22.

Fig. 11.—Portion of a vertical section of the retina of the pineal eye; stained with Ehrlich's hæmatoxylin and picro-indigo-carmin, to show especially the sense-cells in a place (near the optic axis) where there is comparatively little pigment. (Sphenodon I.) $\times 1000$.

Fig. 12.—Portion of a vertical section of the retina of the pineal eye, to show especially the sense-cells and the caps which cover their projecting ends, and the connection of the caps with the vitreous reticulum. Stained with Ehrlich's hæmatoxylin only. (Sphenodon A.) $\times 1660$.

Fig. 13.—Portion of a vertical section of the retina of the pineal eye, showing especially the sense-cells with their projecting ends and caps. Stained with Ehrlich's hæmatoxylin and picro-indigo-carmin. (Sphenodon I.) $\times 1660$.

Fig. 14.—Portion of a vertical section of the retina of the pineal eye, showing grouping of the sense-cells. Stained with Ehrlich's hæmatoxylin and eosin. (Sphenodon I.) $\times 1660$.

Fig. 15.—Tangential section of inner part of retina of the pineal eye, showing the sense-cells cut across. Stained with Ehrlich's hæmatoxylin and eosin. (Sphenodon I.) $\times 1660$.

Fig. 16.—Portion of a vertical section of the retina of the pineal eye, showing the outer nucleated ends of the radial supporting fibres and a ganglion-cell. Stained with Ehrlich's hæmatoxylin and eosin. (Sphenodon I.) $\times 1660$.

PLATE 23.

Fig. 17.—Portion of a vertical section of the retina of the pineal eye, showing the outer nucleated ends of the radial supporting fibres and a ganglion-cell. Stained with Ehrlich's hæmatoxylin and eosin. (Sphenodon I.) $\times 1660$.

Fig. 18.—Portion of a vertical section of the retina of the pineal eye, showing the outer nucleated ends of the radial supporting fibres and a large nucleated pigment-cell which has apparently just forced its way in through the internal capsule and external limiting membrane of the eye. Stained with Ehrlich's hæmatoxylin and eosin. (Sphenodon I.) $\times 1660$.

Fig. 19.—Portion of a vertical section of the retina of the pineal eye, showing the outer nucleated ends of the radial supporting fibres and a pigment-cell lying in the internal capsule of the eye. Stained with Ehrlich's hæmatoxylin and eosin. (Sphenodon I.) $\times 1660$.

- Fig. 20.—Part of section through the external capsule of the pineal eye and the tissues between it and the internal capsule; showing a branch of the anterior pineal artery and a number of wandering cells containing pigment-granules. Stained with Ehrlich's hæmatoxylin and eosin. (Sphenodon I.) $\times 1660$.
- Fig. 21.—Part of section of the tissue between the external and internal capsules of the pineal eye, showing pigment-cells containing varying amounts of pigment. Stained with Ehrlich's hæmatoxylin and eosin. (Sphenodon I.) $\times 1660$.
- Fig. 22.—Vertical section through front part of wall of pineal eye, showing developing lens. Stained with Ehrlich's hæmatoxylin and Orange G. (Embryo 37*a*. Stage O-P.) $\times 518$.
- Fig. 23.—Vertical section through front part of wall of pineal eye, showing developing lens. Stained with Ehrlich's hæmatoxylin and picro-indigo-carmin. (Embryo 51*a*. Stage P-Q.) $\times 518$.
- Fig. 24.—Vertical section of developing lens of pineal eye, showing (on the right) mitosis in the marginal zone. Stained with Ehrlich's hæmatoxylin and Orange G. (Embryo 142. Stage R.) $\times 518$.

PLATE 24.

- Fig. 25.—Vertical section of developing lens of pineal eye, showing in the interior a spherical mass of mucus with contained nuclei. Stained with Ehrlich's hæmatoxylin and Orange G. (Embryo 159. Stage R.) $\times 518$.
- Fig. 26.—Vertical section of developing pineal eye. Pigment is just appearing in the retina and the lens has begun to exude drops of mucus into the cavity of the eye. The differentiation of the lens into marginal and central portions is very clearly shown. Stained with borax carmine and picro-indigo-carmin. (Embryo 141. Stage R.) $\times 333$.
- Fig. 27.—Vertical section through adult lens of pineal eye, showing the large central mucus-mass, with nucleus, etc., and the almost complete separation from the retina. Stained with Ehrlich's hæmatoxylin. (Sphenodon A.) $\times 480$.
- Fig. 28.—Vertical section through adult lens and vitreous body of pineal eye, showing secretion of mucus by the lens, etc. Stained with Ehrlich's hæmatoxylin and picro-indigo-carmin. (Sphenodon I.) $\times 480$.

PLATE 25.

- Fig. 29.*—Part of sagittal section through the roof of the brain at Stage L, showing the development of the primary parietal vesicle. Stained with borax carmine. (Embryo 50.) $\times 220$.

* In figs. 29-31 the anterior end of the section lies to the left; fig. 29 is taken from the same section as fig. 4 of my earlier work (DENDY, 1899, *b*), but at a slightly different focus.

- Fig. 30.—Part of sagittal section through the roof of the brain at about Stage O, showing the developing pineal sac and eye with their cavities still in open communication with one another, etc. Stained with Ehrlich's hæmatoxylin and picro-indigo-carmin. (Embryo 32*a*.) ×220.
- Fig. 31.—Part of sagittal section through the roof of the brain at about Stage N–O, showing the developing pineal eye and sac separated from one another. Stained with Ehrlich's hæmatoxylin and picro-indigo-carmin. (Embryo 24*a*.) ×220.
- Fig. 32.—Vertical longitudinal section through the developing pineal organs at about Stage O–P, showing the nerve of the pineal eye, etc. Stained with Ehrlich's hæmatoxylin and Orange G (combined from several sections). (Embryo 37*a*.) ×75.
- Fig. 33.—Part of another section from the same series as fig. 32, but a little to the right of the section represented in that figure, and through the opening of the pineal sac, which may be taken as approximately in the middle line. Stained with Ehrlich's hæmatoxylin and Orange G. ×127.
- Fig. 34.—Part of longitudinal vertical section through the developing pineal organs at about Stage Q, showing the nerve of the pineal eye, etc. Stained with Ehrlich's hæmatoxylin and Orange G. (Embryo 52*a*.) ×127.
- Fig. 35.—Part of another section from the same series as fig. 34, but a little to the right of the section represented in that figure, and through the opening of the pineal sac, which may be taken as approximately in the middle line. Stained with Ehrlich's hæmatoxylin and Orange G. (Embryo 52*a*.) ×127.

PLATE 26.

All the figures on this plate are from a series of transverse sections of the head of Embryo 39*a*, Stage P, stained with Ehrlich's hæmatoxylin and Orange G. They show the course of the nerve of the pineal eye, from the eye to the brain, always on the left side of the middle line, right and left sides being reversed in the figures. (Compare figs. 32 to 35.)

- Fig. 36.—Section through the junction of the nerve with the retina of the pineal eye. ×220.
- Fig. 37.—Section showing the nerve lying free between the pineal eye and the roof of the brain. ×220.
- Fig. 38.—Section showing the nerve lying just above the roof of the brain, in the interval between the pineal eye and pineal sac. ×220.
- Fig. 39.—Section showing the nerve closely attached to the roof of the brain beneath the apex of the pineal sac. ×220.
- Fig. 40.—Section showing the nerve just entering the thickening of the brain-roof which will form the left habenular ganglion. ×127.

Fig. 41.—Section through the superior commissure, just in front of the opening of the pineal sac. $\times 127$.

Fig. 42.—Section through the opening of the pineal sac. $\times 127$.

PLATE 27.

Fig. 43.—Part of transverse section through the pineal region of Embryo 162 (Stage R), stained with Ehrlich's hæmatoxylin and Orange G; to show especially the position of the nerve of the pineal eye to the left of the middle line (apparent right owing to reversal). Note also the sub-commissural organ and its connection with the lower part of the pineal sac (recessus infra-pinealis), and the backward extensions of the dorsal sac. $\times 75$.

Fig. 44.—Longitudinal vertical section of the entire brain of Embryo II (Stage S), a little to the left of the median plane, showing especially the lateral diverticula of the fore- and mid-brain. Stained with Ehrlich's hæmatoxylin and Orange G. $\times 19$.

Fig. 45.—Part of an approximately median section of the same series as fig. 44, showing the relation of the pineal organs and associated parts of the brain. Stained with Ehrlich's hæmatoxylin and Orange G. $\times 50$.

Fig. 46.—Part of another section of the same series, more enlarged, showing the superior and posterior commissures, tractus pinealis, sub-commissural organ, etc. Stained with Ehrlich's hæmatoxylin and Orange G. $\times 127$.

PLATE 28.

Figs. 47–52.—Selections from a series of transverse sections of *Sphenodon* VI, to show the course of the more anterior portion of the nerve of the pineal eye and the anterior pineal artery, etc., in the adult (working backwards). In fig. 47 the nerve is still in the capsule of the eye. In figs. 50 and 51 it has left the capsule and has broken up into separate strands. In fig. 52 the strands have united again and the nerve is just coming into contact with the apex of the pineal sac, while the paraphysis is seen beneath it (the further course of the nerve and artery are shown in text-figs. 13–16 taken from the same series of sections). $\times 50$.

Fig. 53.—Transverse section of the nerve of the pineal eye and its connective-tissue sheath. From the same series of sections as figs. 47–52. Stained with borax carmine and picro-indigo-carmine. $\times 414$.

Fig. 54.—Transverse section through the habenular ganglia, showing nerve-fibres entering the upwardly prolonged left habenular ganglion from the wall of the dorsal sac. (*Sphenodon* VI, same series of sections as preceding figures.) $\times 50$

Fig. 55.—Transverse section through the superior commissure and habenular ganglia and posterior edge of dorsal sac. (Sphenodon VI, same series of sections as preceding figures.) $\times 50$.

PLATE 29.

Fig. 56.—Transverse section through the infra-pineal recess and junction of the tractus pinealis with the brain, showing the anterior end of the sub-commissural organ, Meynert's bundles, etc. (Sphenodon VI, same series of sections as preceding figures.) $\times 50$.

Fig. 57.—Transverse section through the lower part of the tractus pinealis, median habenular ganglion, etc. (Sphenodon VI, same series of sections as preceding figures and between the sections represented in figs. 55 and 56, but more highly magnified.) Note the cavity in the tractus pinealis with an "ependymal groove" in its floor. $\times 127$.

Fig. 58.—Longitudinal vertical section through the lower extremity of the pineal sac, showing the place where the nerve of the pineal eye loses its nuclei and breaks up. (Sphenodon V.) $\times 50$.

Fig. 59.—Another section from the same series, but rather more to the right, showing a strand of the nerve of the pineal eye entering the wall of the dorsal sac. $\times 50$.

Fig. 60.—Another section from the same series, but still more to the right, showing the tractus pinealis leaving the pineal sac. $\times 50$.

Fig. 61.—Another section from the same series, again a little more to the right but showing the left habenular ganglion below and a bundle of nerve-fibres entering it from the wall of the dorsal sac. $\times 50$.

Fig. 62.—Combined drawing from several sections of the same series as the preceding, through the posterior and superior commissures, infra-pineal recess, lower extremity of tractus pinealis, and sub-commissural organ. $\times 50$.

PLATE 30.

Fig. 63.—Part of longitudinal vertical section through wall of dorsal sac, nerve of pineal eye and wall of pineal sac, to show histological details. (Sphenodon V.) $\times 518$.

Fig. 64.—Part of another section from the same series, to show histological details. Note especially the branch joining the nerve of the pineal eye from the wall of the pineal sac. $\times 518$.

Fig. 65.—Part of another section from the same series, showing histological details in the wall of the pineal sac near its lower extremity. $\times 518$.

Fig. 66.—Part of another section from the same series, showing histological structure of the wall in a fold near the middle of the pineal sac. $\times 518$.

- Fig. 67.—Part of another section from the same series, showing histological structure of the inner part of the wall of the pineal sac in a projecting fold near its lower extremity. Note especially the sense-cells and ganglion-cells. $\times 720$.
- Fig. 68.—Part of another section from the same series, showing histological structure of the outer part of the wall near the middle of the pineal sac. Note the radial supporting fibres and ganglion-cells. $\times 720$.
- Fig. 69.—Group of large brownish-yellow leucocytes (?) from the cavity of the pineal sac. (Sphenodon V.) $\times 1000$.
- Fig. 70.—Two leucocytes from a lymph space in the connective tissue above the pineal sac. (Sphenodon V.) $\times 1000$.
- Fig. 71.—Two leucocytes from blood-vessel in wall of pineal sac. (Sphenodon V.) $\times 1000$.

PLATE 31.

- Fig. 72.—Histological structure of the choroid plexus of the dorsal sac and of the paraphysis, as seen in vertical longitudinal section of Sphenodon V. $\times 220$.
- Fig. 73.—Epithelium covering the choroid plexus of the dorsal sac, surface view. (Sphenodon V.) $\times 1000$.
- Fig. 74.—Vertical longitudinal section through the paraphysis and the choroid plexus of the dorsal sac. (Sphenodon V.) The lining epithelium of the paraphysis is represented by the thick black lines. Combined drawing from several sections. $\times 50$.
- Fig. 75.—Histological structure of the paraphysis as shown in a transverse section of Sphenodon VI. Note especially the paraphysial knobs. $\times 220$.
- Fig. 76.—Part of a tangential section through the lower limb of the paraphysis, showing the network of blood-vessels lying between the paraphysial diverticula. From a transverse section of Sphenodon VI. $\times 220$.
- Fig. 77.—Epithelial lining of the paraphysis, from the same section as fig. 73. (Sphenodon V.) $\times 1000$.
- Fig. 78.—Part of network of cells from the lumen of the paraphysis, showing amitotic division of the nuclei. (Sphenodon V.) $\times 1000$.

XII.—EXPLANATION OF LETTERING ON PLATES AND TEXT-FIGURES.

| | | | |
|-------------------------------|---|----------------------|---|
| <i>A. Cav.</i> , | Accessory cavity in pineal eye. | <i>C. P. N.</i> , | Cellular network attached to epithelium of choroid plexus. |
| <i>a. ch. a.</i> , | Arteria choroidea anterior. | <i>Cr. C.</i> , | Crura cerebri. |
| <i>A. Ch. V.</i> , | Anterior choroidal vessels. | <i>C. S.</i> , | Commissura superior. |
| <i>a. c. p.</i> , | Arteria cerebialis posterior. | <i>c. s. ?</i> | Centrosome ? |
| <i>a. c. s.</i> , | Arteria cerebialis superior. | <i>c. s. p. n.</i> , | Connective tissue sheath of left pineal nerve. |
| <i>a. p. a.</i> , | Arteria pinealis anterior. | <i>c. t. f.</i> , | Connective tissue fibre. |
| <i>a. p. p.</i> , | Arteria pinealis posterior. | <i>C. T. P.</i> , | Cavity in tractus pinealis. |
| <i>a. p. p¹.</i> , | Branch of arteria pinealis posterior. | <i>C. V.</i> , | Commissura ventralis. |
| <i>a. s.</i> , | Arteria saccularis. | <i>c. vit.</i> , | Vitreous body of pineal eye. |
| <i>a. th.</i> , | Arteria thalamica. | <i>Der.</i> , | Dermis. |
| <i>a. th. s.</i> , | Arteria thalamica superior. | <i>D.K.</i> , | Nerve-cells of "Dachkern." |
| <i>b. m.</i> , | Basement membrane. | <i>d. m. i.</i> , | Inner layer of dura mater. |
| <i>b. n. p. e.</i> , | Branch of left pineal nerve. | <i>D. S.</i> , | Dorsal sac. |
| <i>b. p. c.</i> , | Large branched pigment-cell. | <i>e. c. p.</i> , | Epithelium of choroid plexus. |
| <i>B. V.</i> , | Blood-vessel. | <i>Epdl.</i> , | Epidermis. |
| <i>C. Ab.</i> , | Commissura aberrans (or its position in embryo). | <i>ep. w. d.</i> , | Lining epithelium of wall of dorsal sac. |
| <i>cap.</i> , | Cap covering end of sense-cell of pineal eye. | <i>F. M.</i> , | Foramen of Monro. |
| <i>C. D.</i> , | Commissura dorsalis. | <i>FR.</i> , | Frontal bone. |
| <i>c. e.</i> , | Capsula externa of pineal eye. | <i>f. ret.</i> , | Fibres of vitreous reticulum attached to sense-cells of retina. |
| <i>Cer.</i> , | Cerebellum. | <i>g. c.</i> , | Ganglion-cells. |
| <i>C. H.</i> , | Cerebral hemisphere. | <i>G. H.</i> , | Habenular ganglion. |
| <i>c. i.</i> , | Capsula interna of pineal eye. | <i>G. H. L.</i> , | Left habenular ganglion. |
| <i>c. l. p.</i> , | Central lumen of paraphysis. | <i>G. H. M.</i> , | Median habenular ganglion. |
| <i>c. l. r.</i> , | Line of cleavage between lens and retina of pineal eye. | <i>G. H. R.</i> , | Right habenular ganglion. |
| <i>C. P.</i> , | Commissura posterior. | <i>hæm.</i> , | Hæmatids. |
| <i>c. p. A.</i> , | Choroid plexus of lateral and third ventricles (= plexus hemisphærium). | <i>Inf.</i> , | Infundibulum. |
| <i>c. p. B.</i> , | Choroid plexus of dorsal sac. | <i>Iter.</i> , | Iter a tertio ad quartum ventriculum. |
| <i>c. p. C.</i> , | Choroid plexus of fourth ventricle. | <i>leuc.</i> , | Leucocyte. |
| | | <i>l. l. e.</i> , | Lens of lateral eye. |

| | | | |
|----------------------|---|----------------------|---|
| <i>l. n. f. e.</i> , | Layer of nerve-fibres of pineal eye. | <i>O. Ch. and</i> | } Optic chiasma. |
| | | <i>o. ch.</i> , | |
| <i>l. n. f. s.</i> | Layer of nerve-fibres of pineal sac. | <i>O. L.</i> , | Optic lobe. |
| | | <i>Olf. L.</i> , | Olfactory lobe. |
| <i>l. p. e.</i> , | Lens of pineal eye. | <i>Olf. S.</i> , | Olfactory stalk. |
| <i>l. s. n.</i> , | Lamina supraneuroporica. | <i>o. n.</i> , | Optic nerve. |
| <i>L. T.</i> , | Lamina terminalis. | <i>O. P.</i> , | Opening of paraphysis in embryo. |
| <i>l. v.</i> , | Lateral ventricle of cerebral hemisphere. | <i>O. P'.</i> , | Secondary opening of paraphysis into dorsal sac in adult. |
| <i>Man.</i> , | Mandible. | <i>O. P. S.</i> , | Opening of pineal sac into brain-cavity, or its position after closure. |
| <i>M. B.</i> , | Mid-brain. | <i>O. Th.</i> , | Optic thalamus. |
| <i>m. b.</i> , | Meynert's bundle. | <i>op. V.</i> , | Optocœl. |
| <i>Med.</i> , | Medulla oblongata. | <i>PA.</i> , | Parietal bone. |
| <i>Mes. R.</i> , | Mesocœlic recess. | <i>Par.</i> , | Paraphysis. |
| <i>m. f.</i> , | Mitotic figure. | <i>Par. D.</i> , | Diverticula of paraphysis. |
| <i>m. l. e.</i> , | Membrana limitans externa of retina of pineal eye. | <i>Par. Ep.</i> , | Epithelium of paraphysis. |
| <i>m. l. i.</i> , | Membrana limitans interna of retina of pineal eye or of wall of pineal sac. | <i>Par. K.</i> , | Paraphysial knobs. |
| <i>mu.</i> , | Mucus exuding from middle of inner surface of lens of pineal eye. | <i>Par. N.</i> , | Cellular network in paraphysial tubules. |
| <i>mu. m.</i> , | Mucus-masses in the interior of the lens of pineal eye. | <i>p. d. s.</i> , | Pigmented diverticulum of pineal sac. |
| <i>m. z. l.</i> , | Marginal zone of lens of pineal eye. | <i>P. E.</i> , | Pineal eye. |
| <i>ne.</i> , | Neopallium. | <i>Pig.</i> , | Pigment. |
| <i>n. f. r.</i> , | Nerve-fibres in retina. | <i>Pig. C.</i> , | Pigment-cell. |
| <i>n. g. c.</i> , | Nucleus of ganglion-cell. | <i>Pig. Ep.</i> , | Pigment epithelium of lateral eye. |
| <i>No.</i> , | Notochord. | <i>Pit.</i> , | Pituitary body. |
| <i>n. p.</i> , | Nerve-process of sense-cell. | <i>p. m.</i> , | Pia mater. |
| <i>n. p. e.</i> , | Nerve of pineal eye. | <i>P. P.</i> , | Parietal plug. |
| <i>N. Pig.</i> , | Nucleus of pigment-cell. | <i>Pros.</i> , | Prosencephalon. |
| <i>n. p. n.</i> , | Nuclei in pineal nerve. | <i>P. S.</i> , | Pineal sac. |
| <i>n. r. f.</i> , | Nucleus of radial fibre. | <i>p. s. c.</i> , | Process of sense-cell projecting into cavity of pineal eye. |
| <i>N. Rot.</i> , | Nucleus rotundus. | <i>p. t. b.</i> , | Paraterminal body. |
| <i>n. s. c.</i> , | Nucleus of sense-cell. | <i>r. a. p. a.</i> , | Branch of anterior pineal artery. |
| <i>nu.</i> , | Nucleus. | | |

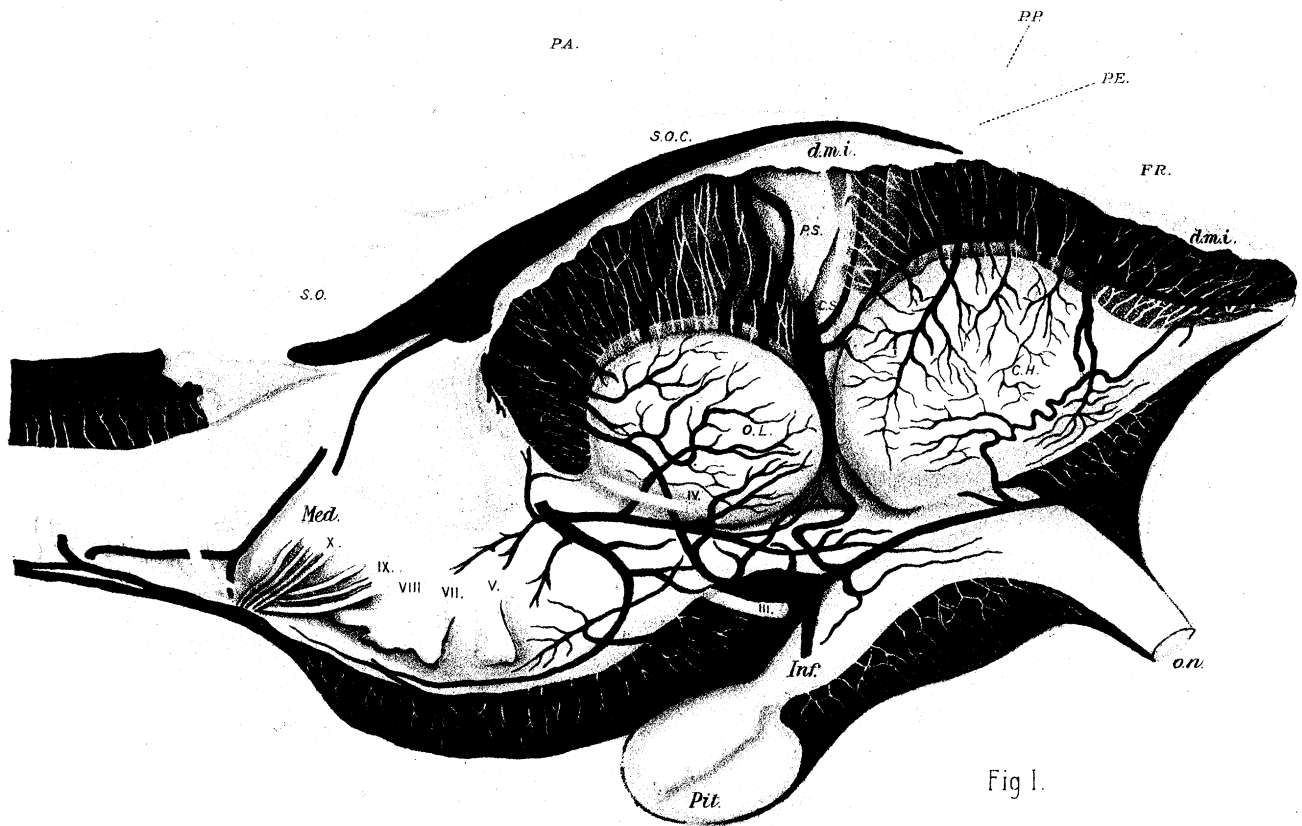


Fig. 1.

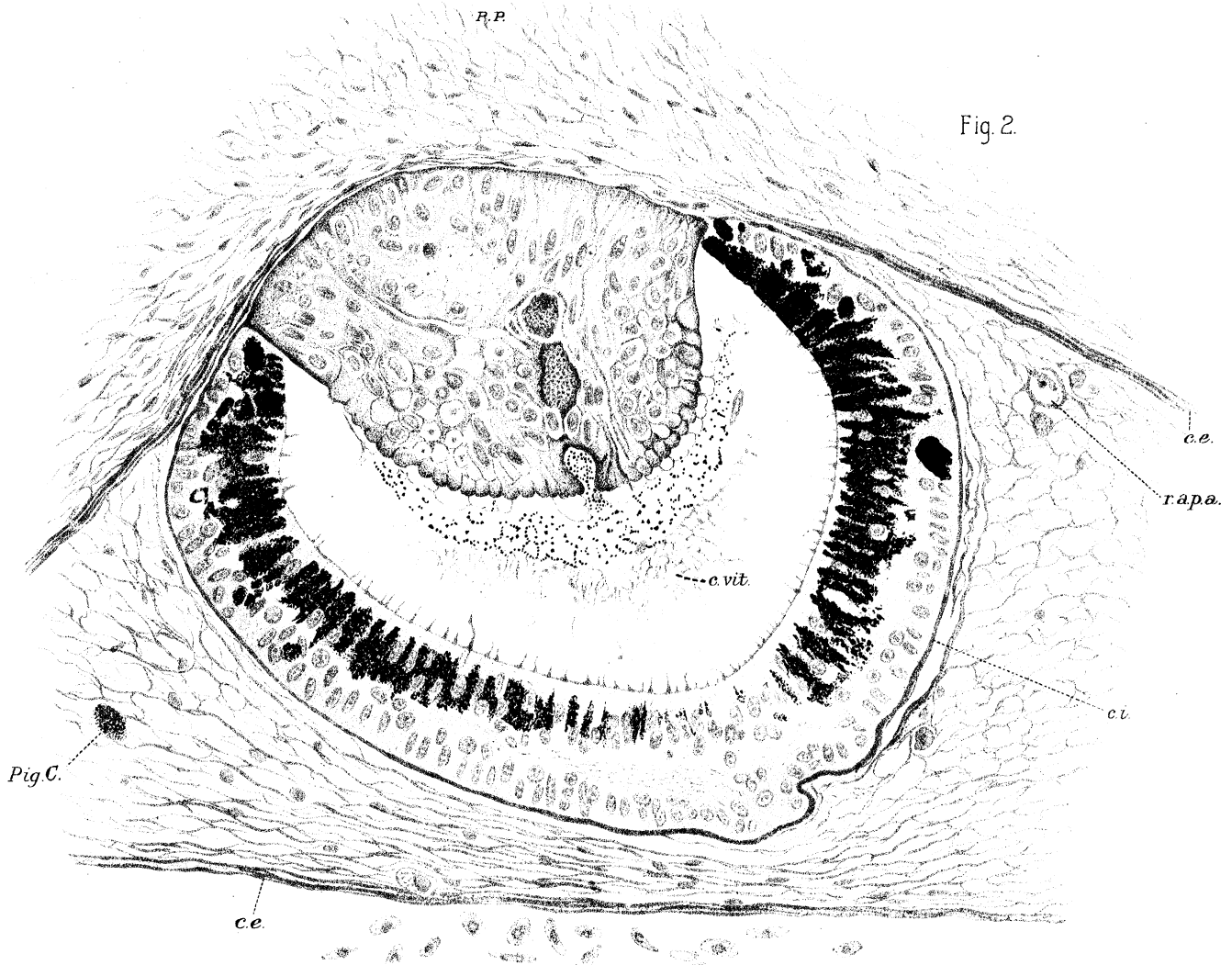


Fig. 2.

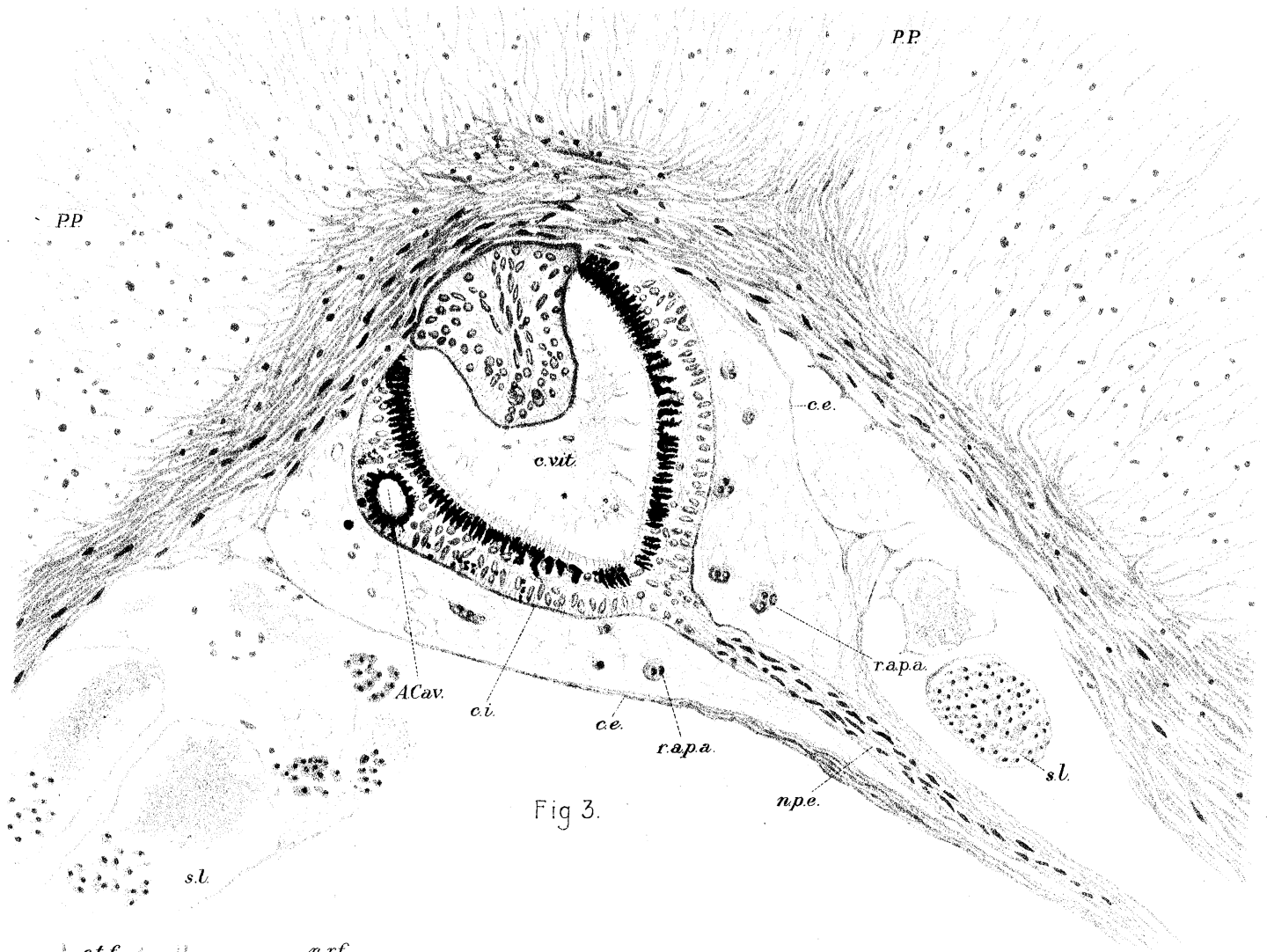


Fig 3.

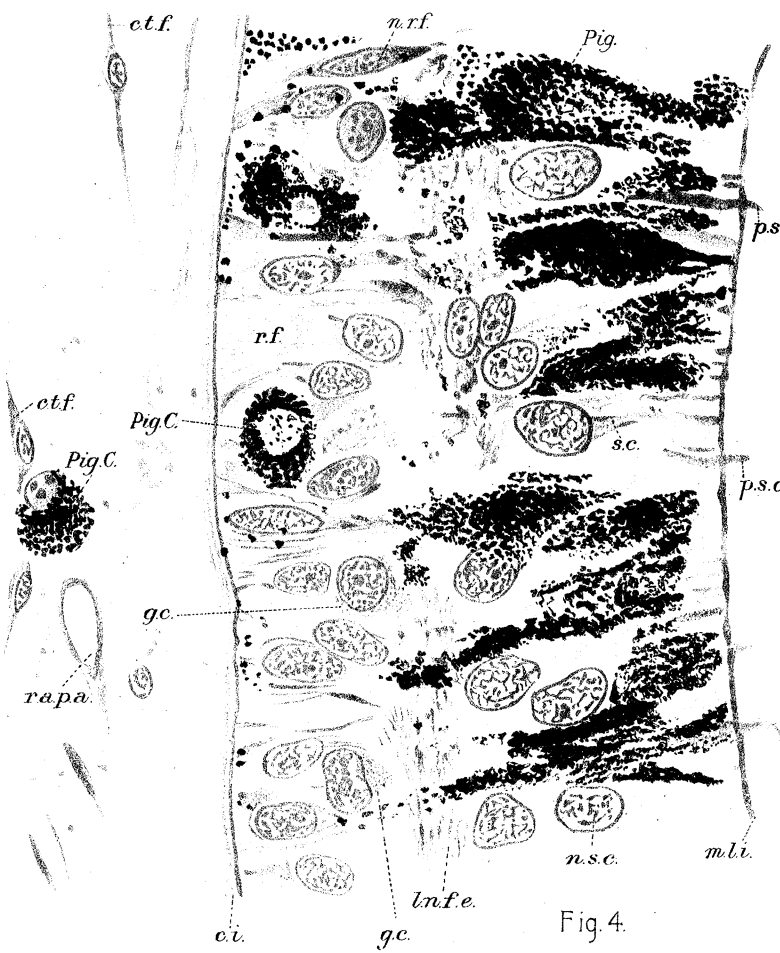


Fig 4.

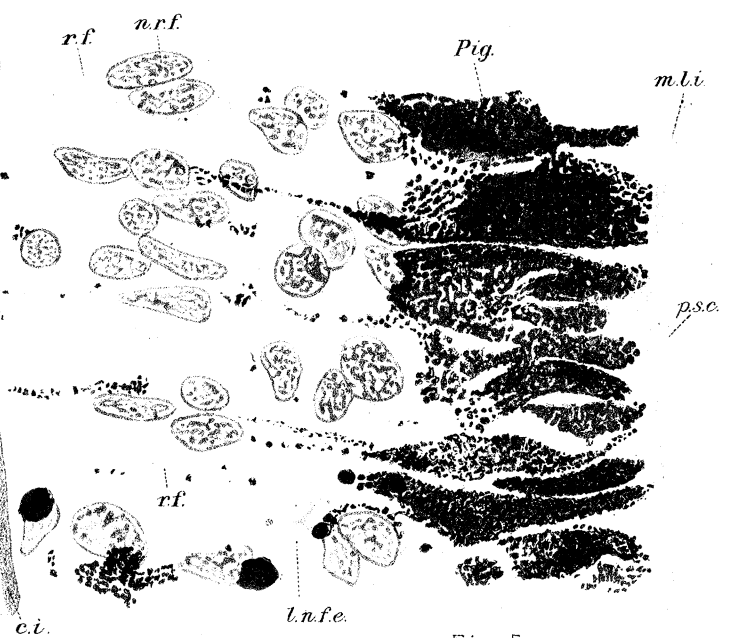
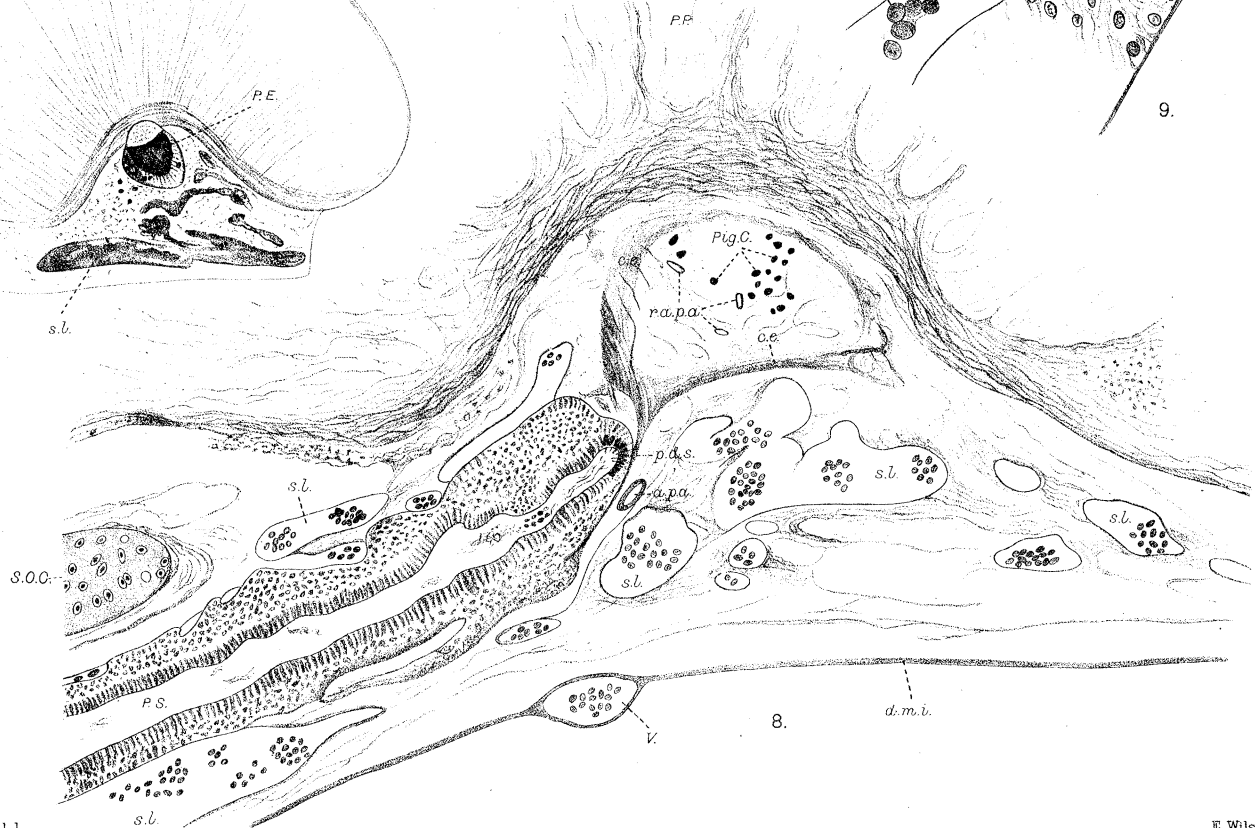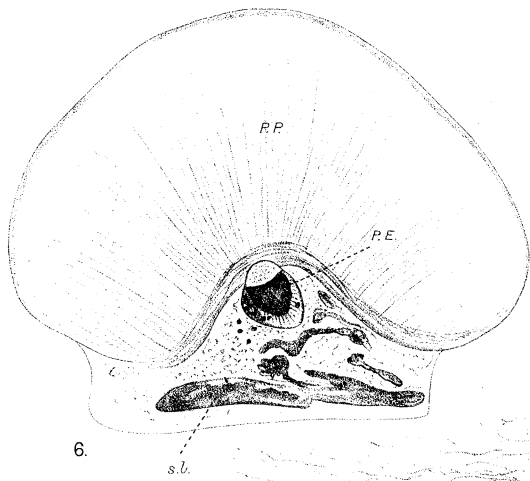
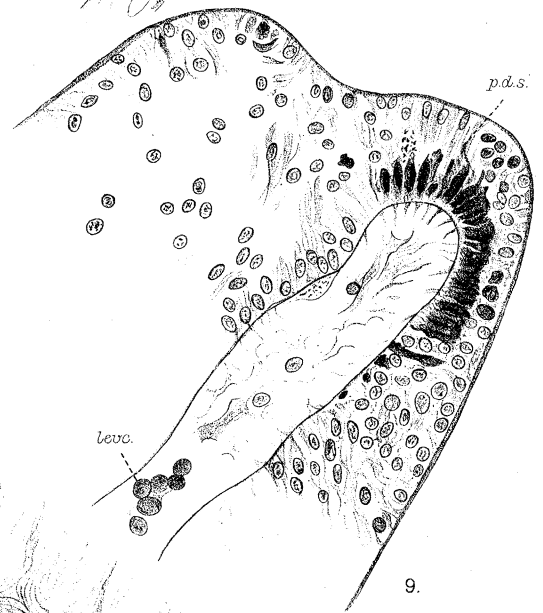
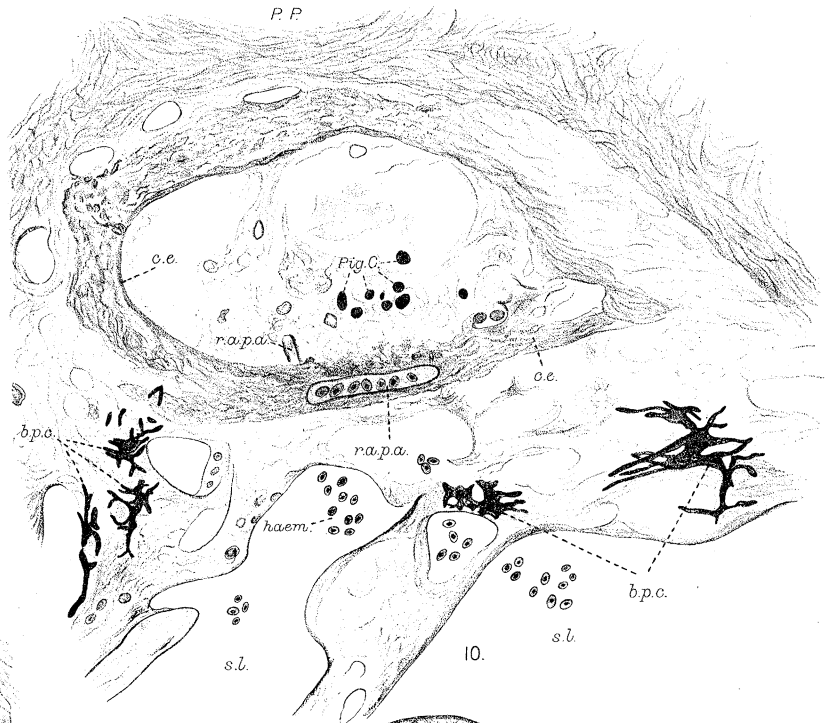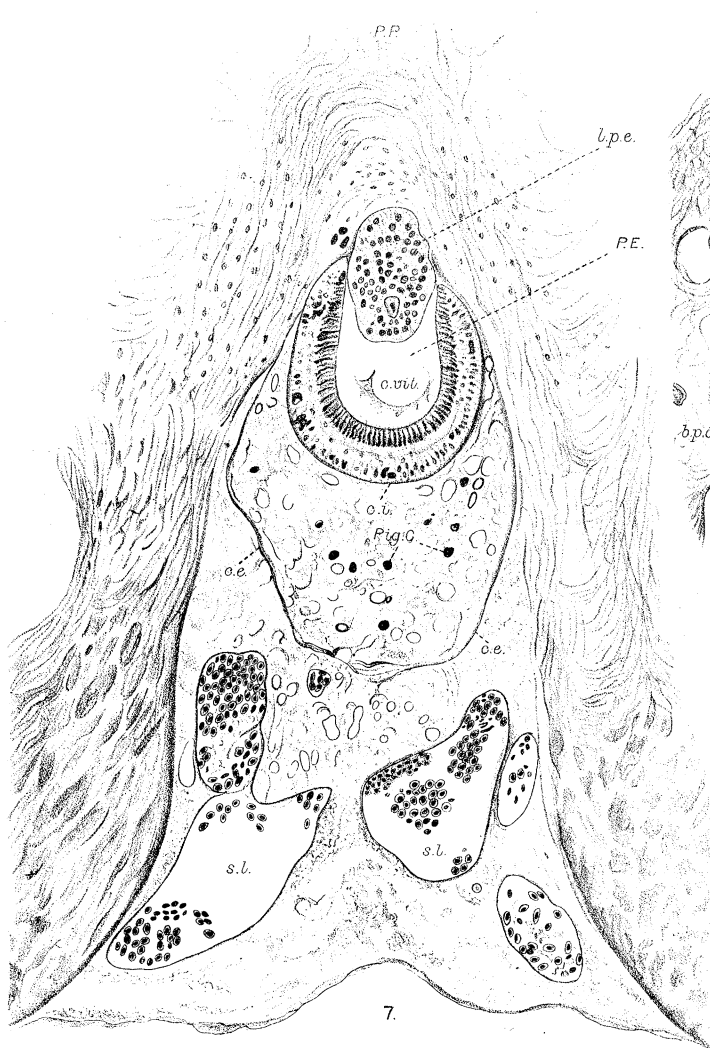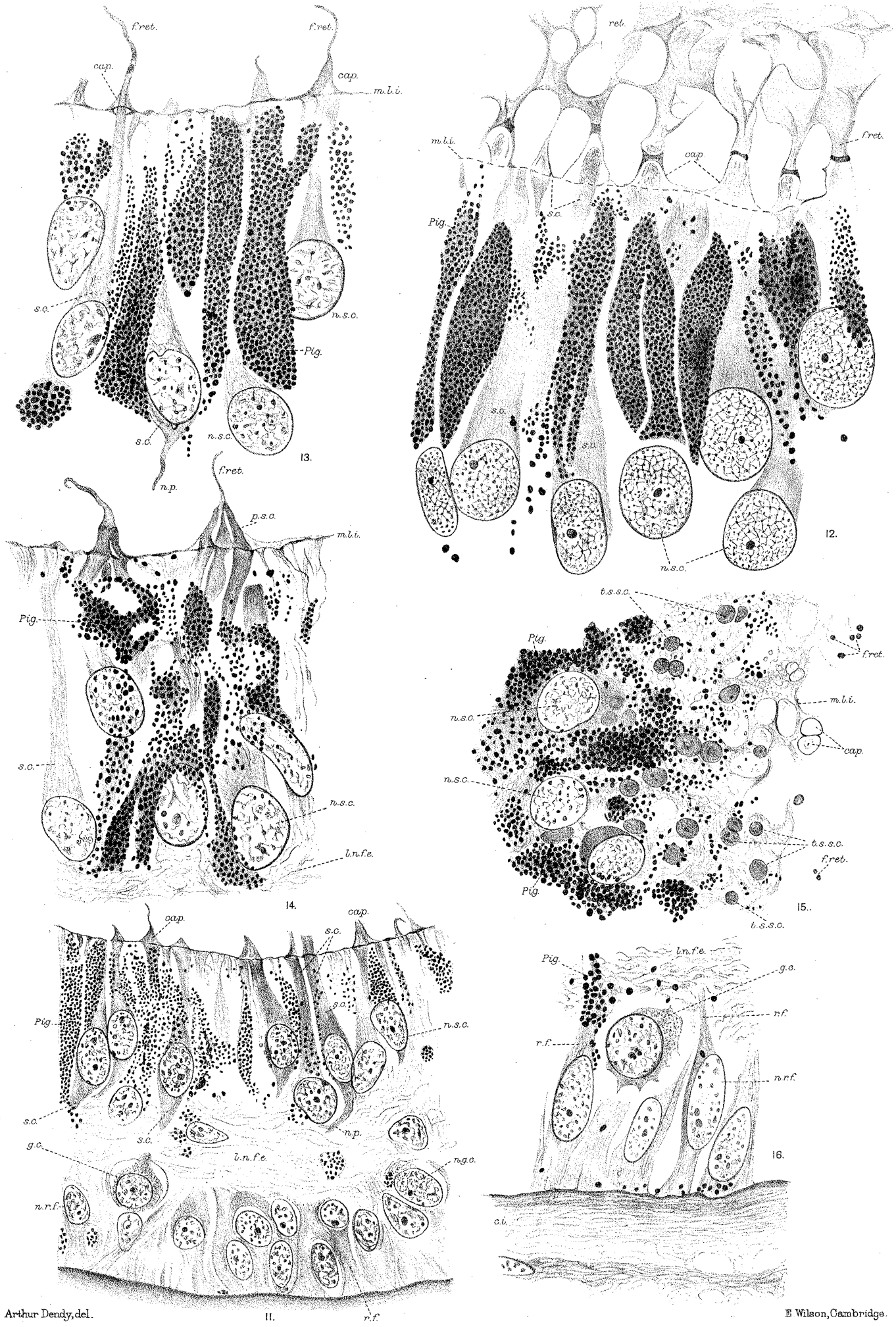
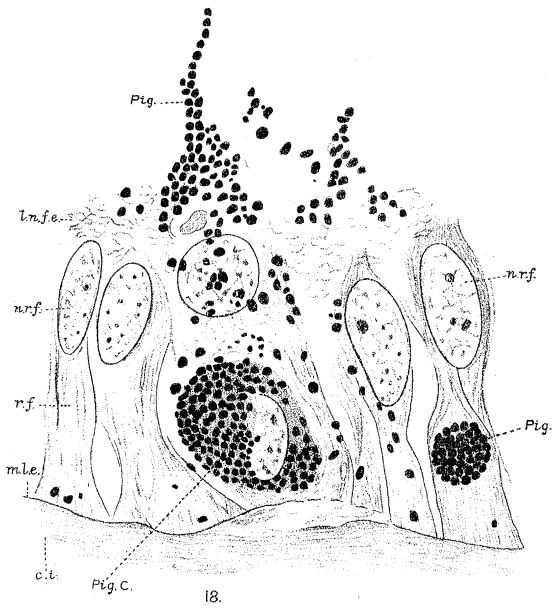


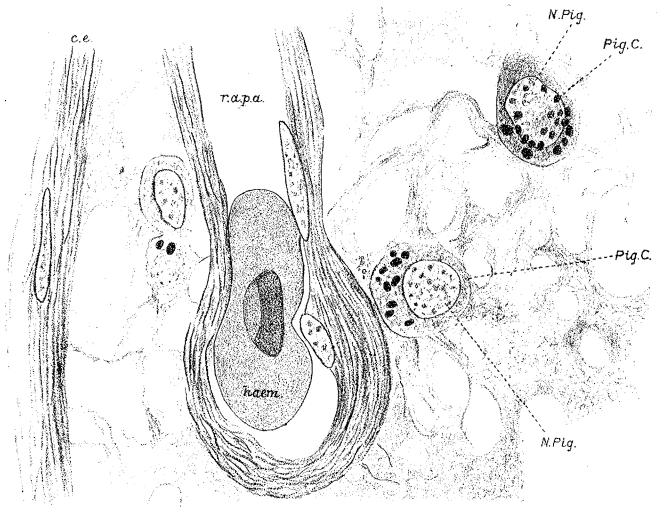
Fig. 5.



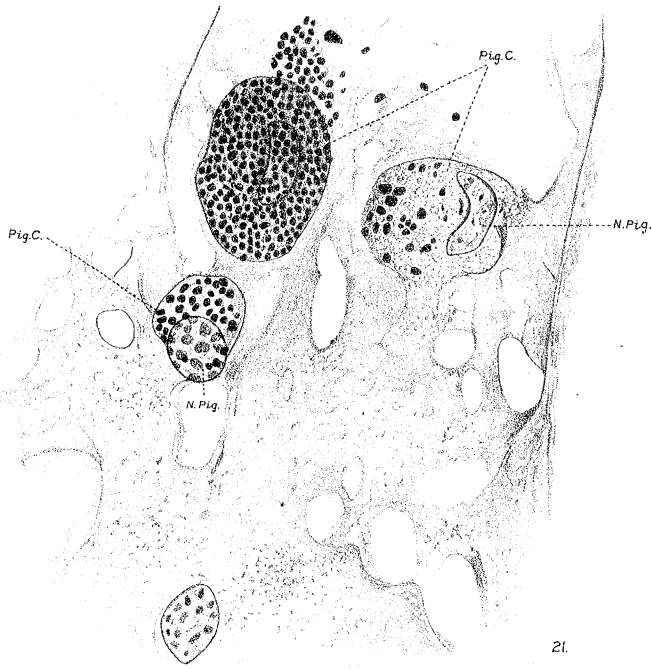




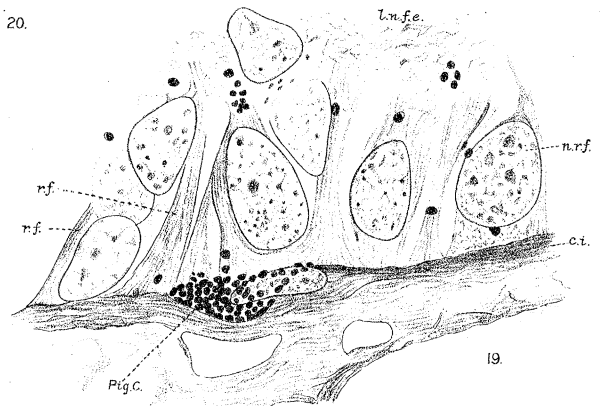
18.



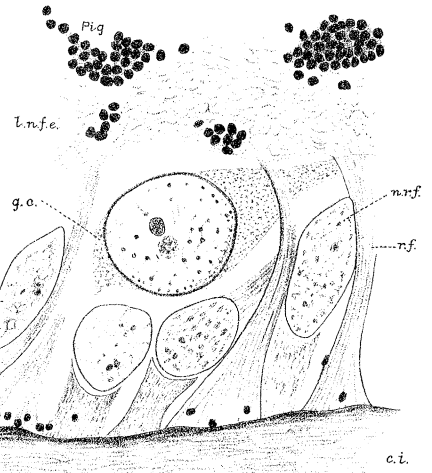
20.



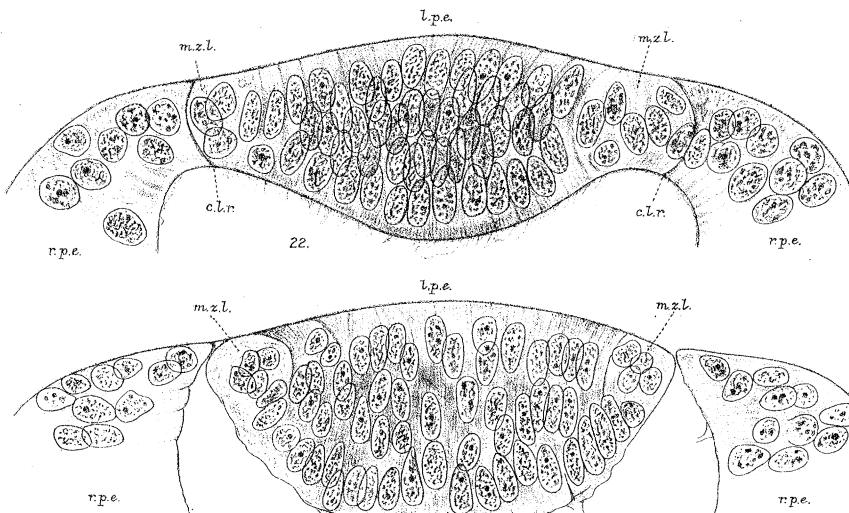
21.



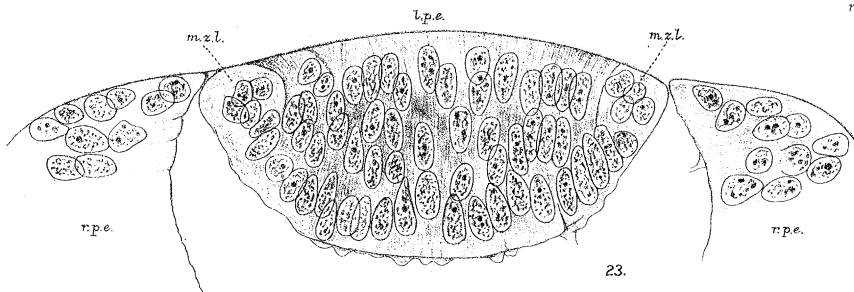
19.



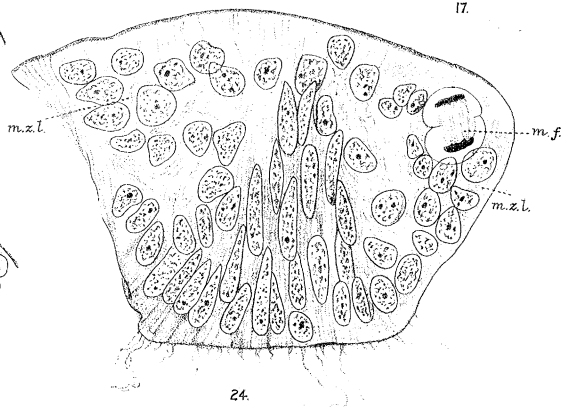
17.



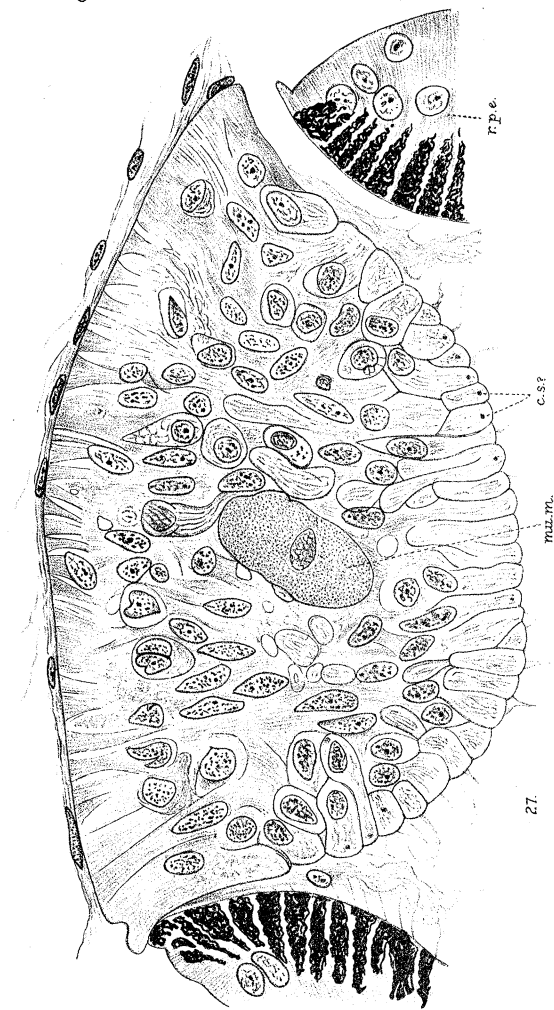
22.



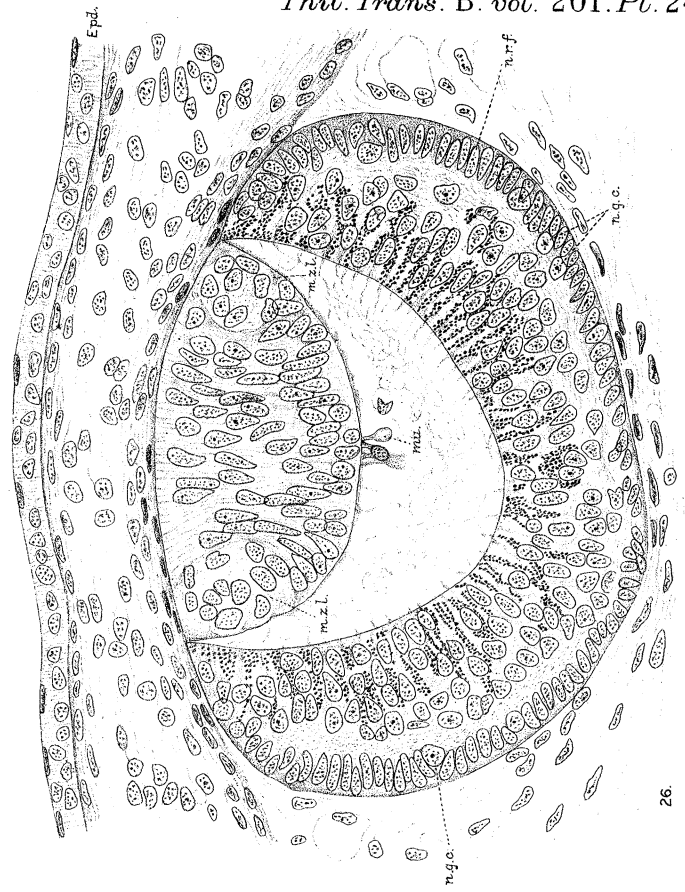
23.



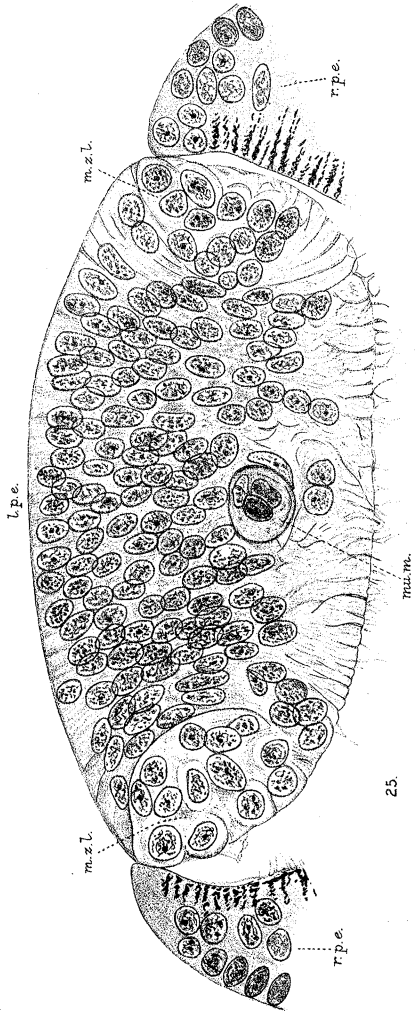
24.



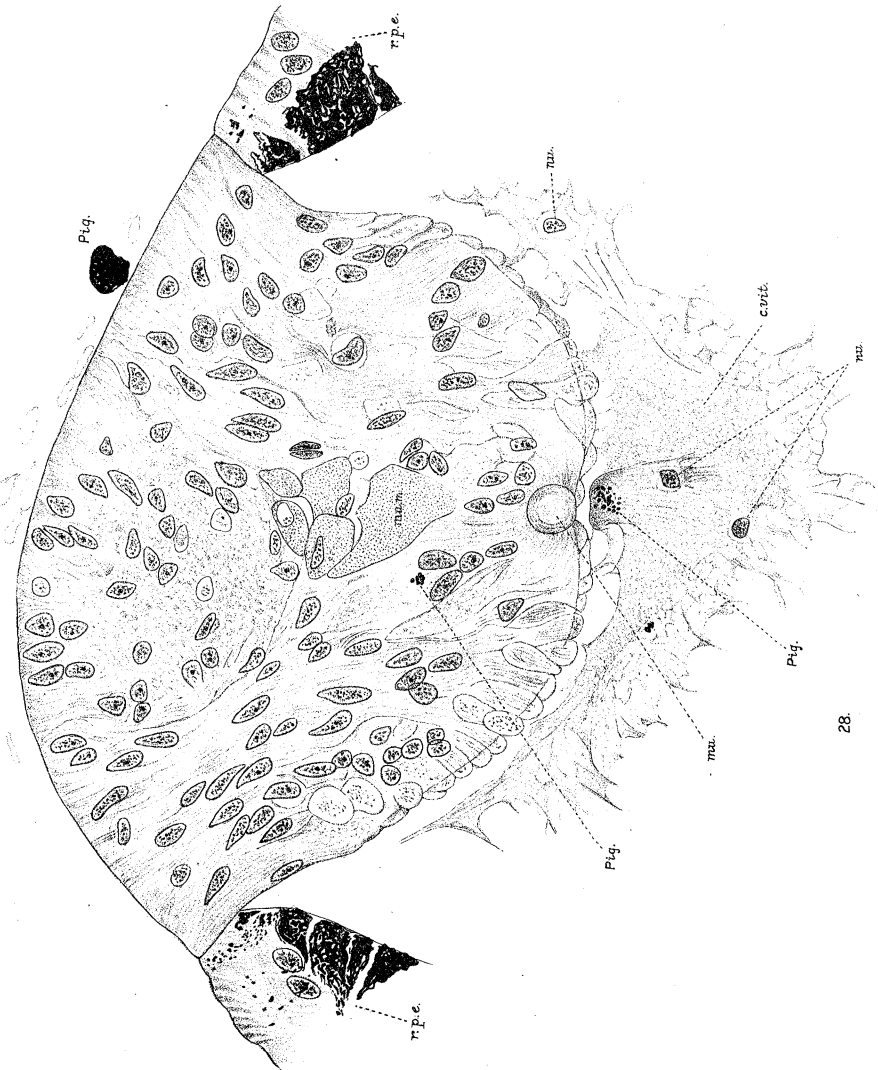
27



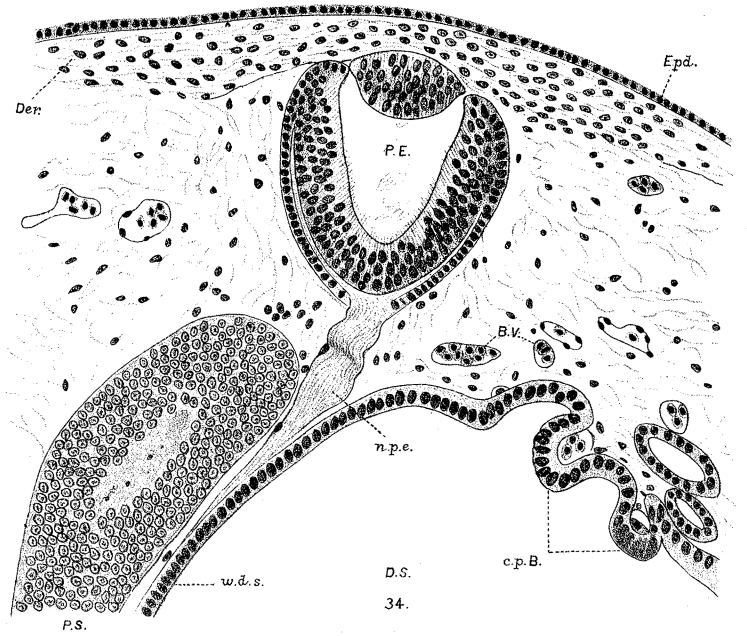
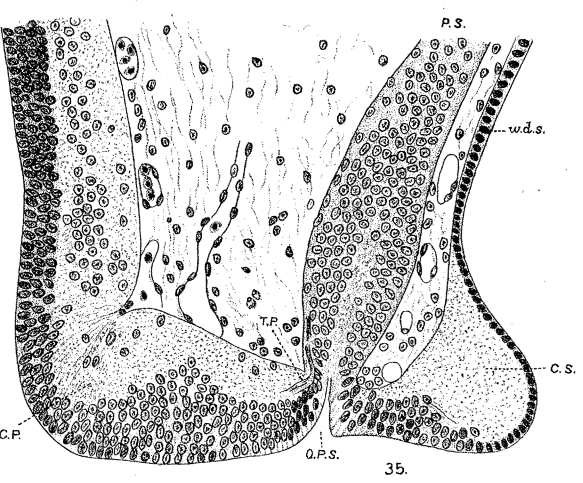
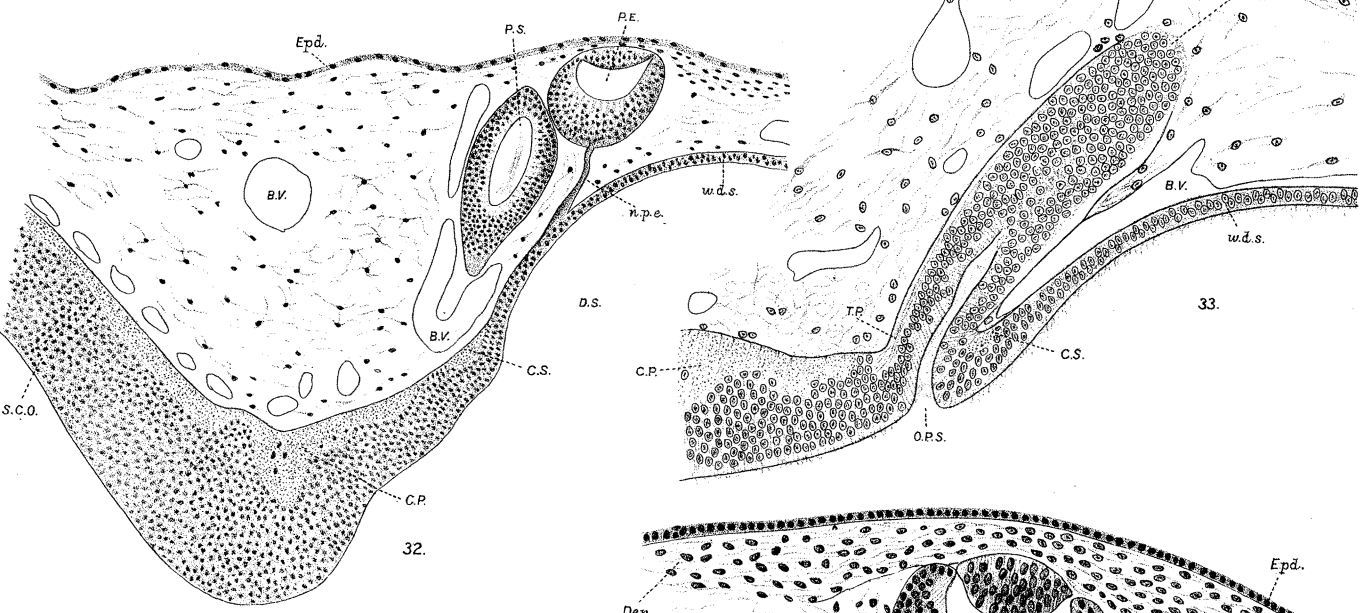
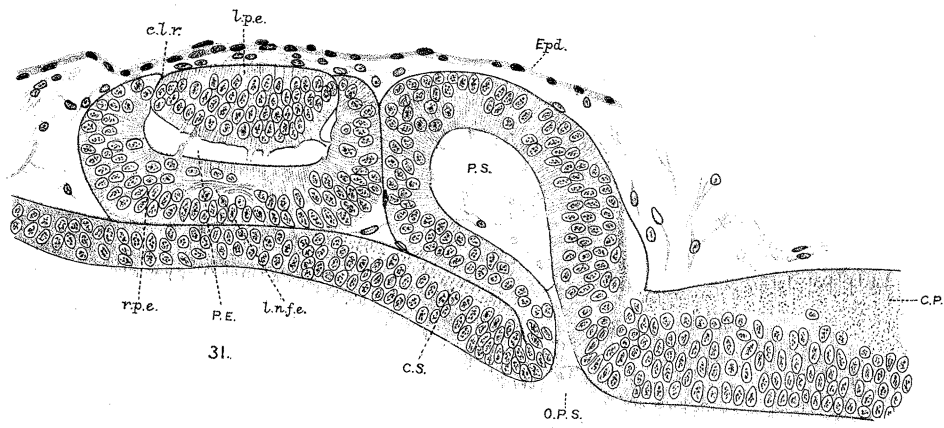
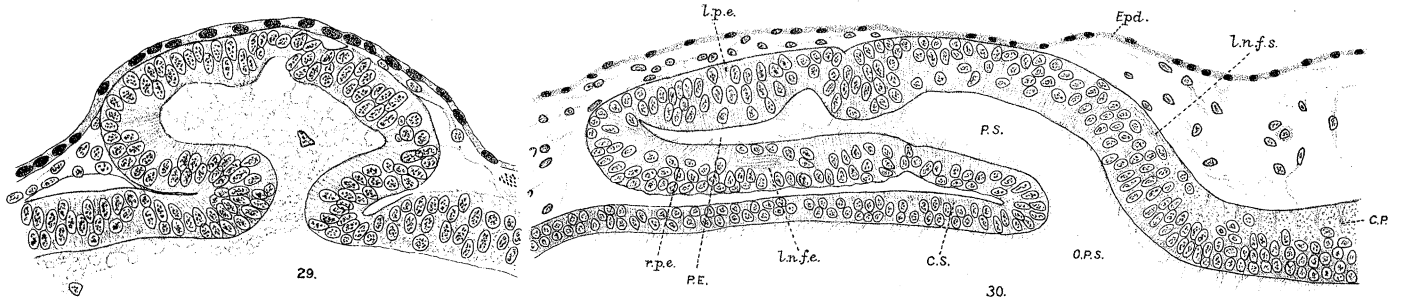
26

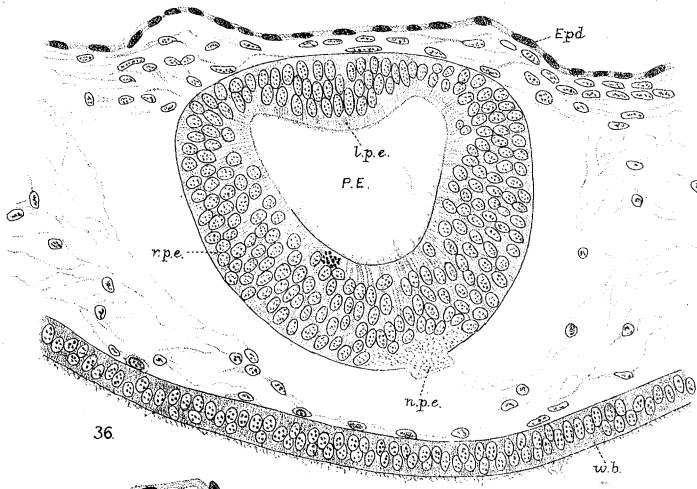


25

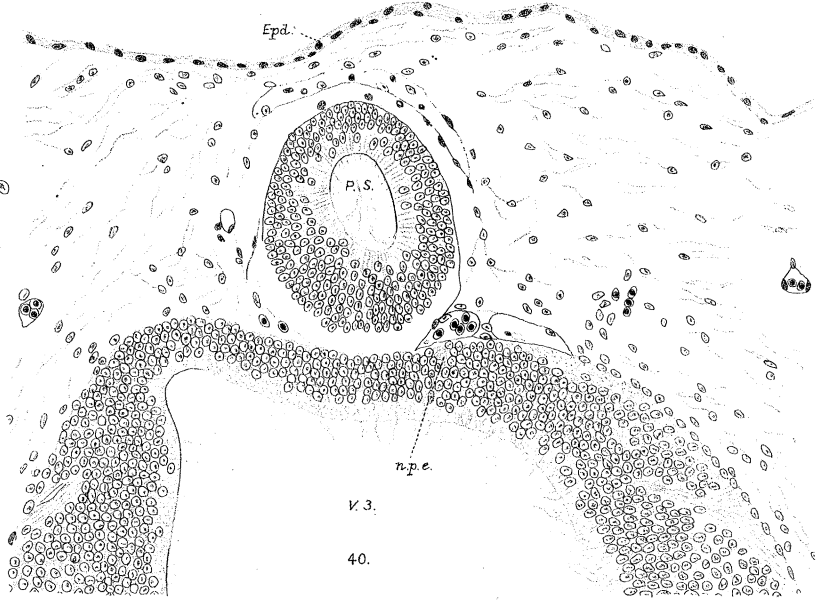

28

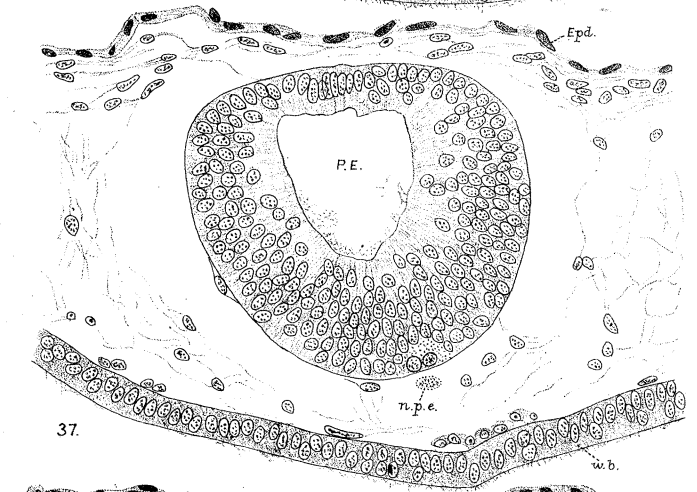




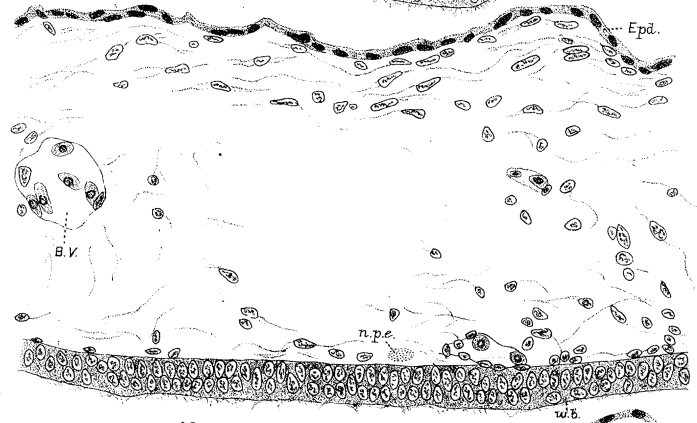
36



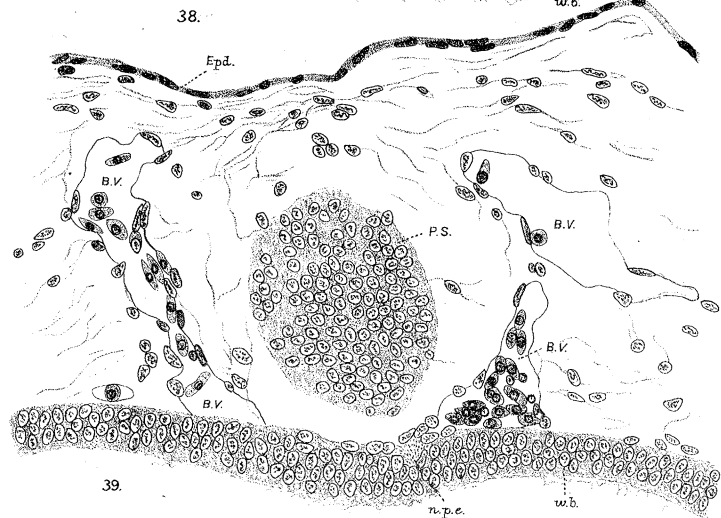
40.



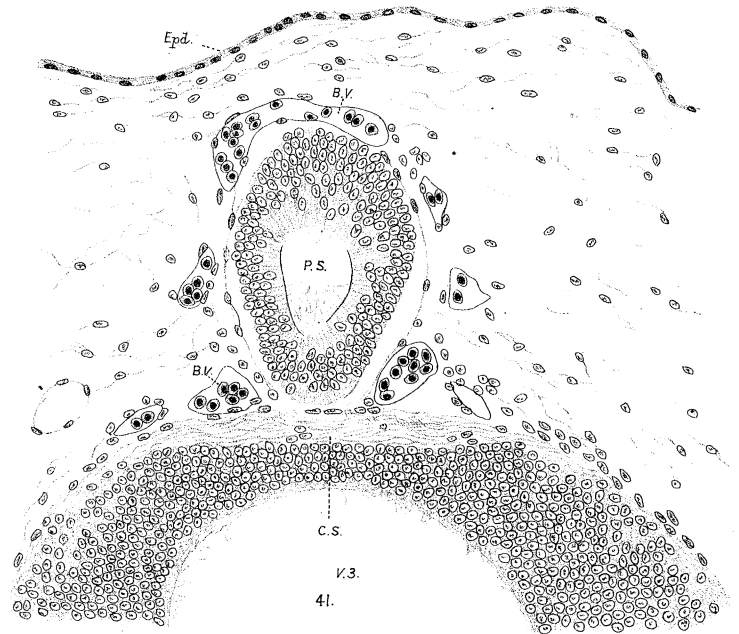
37.



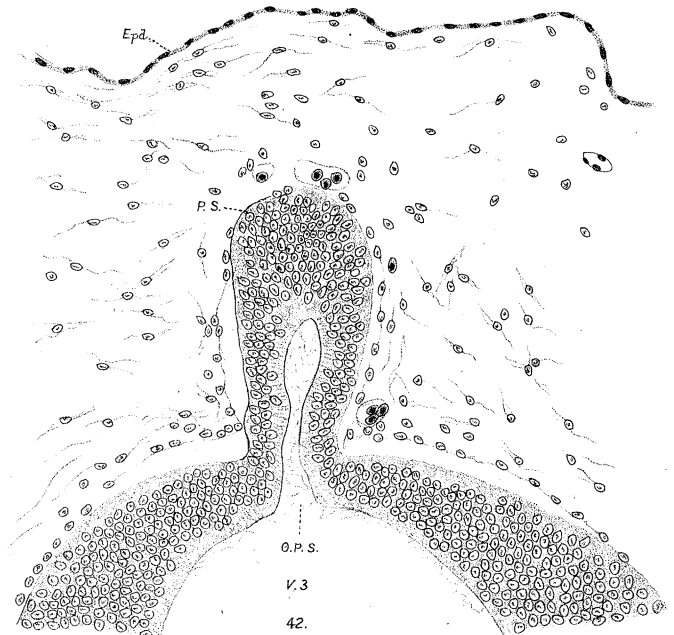
38.



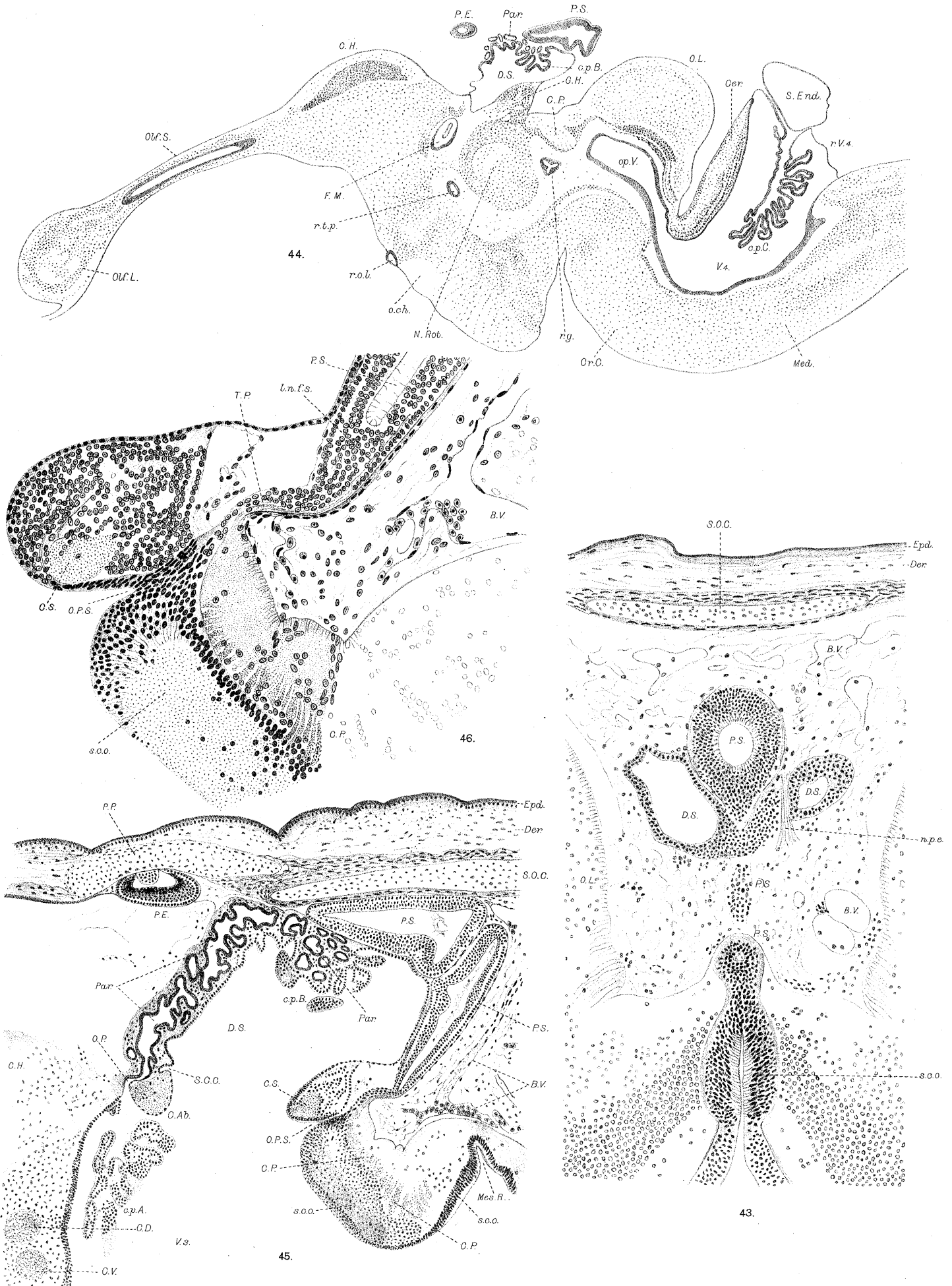
39.

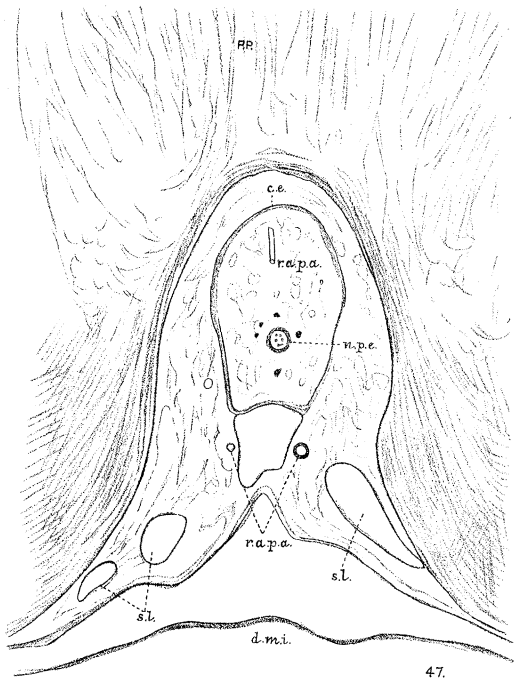


41.

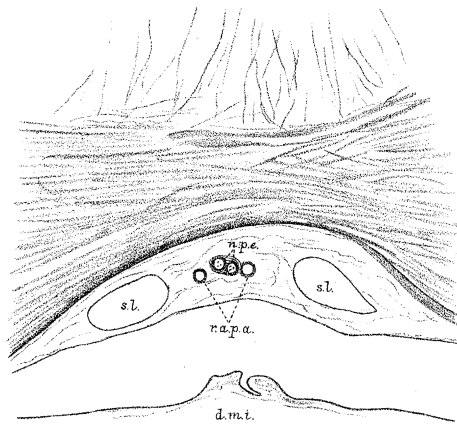


42.

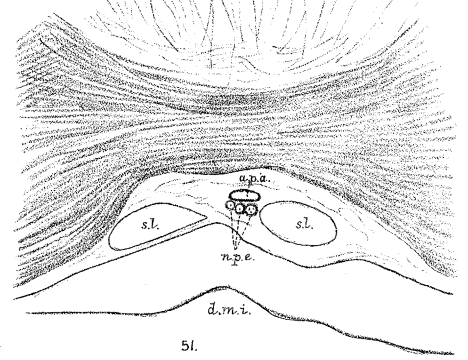




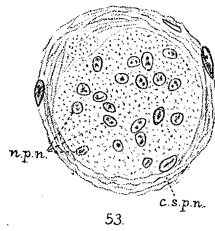
47.



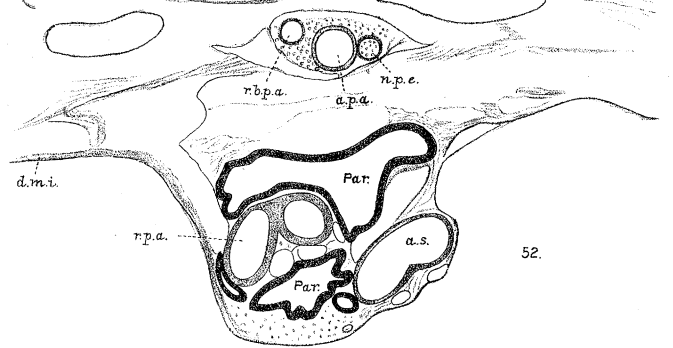
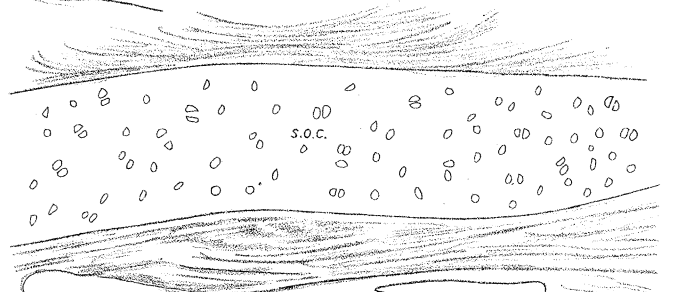
50.



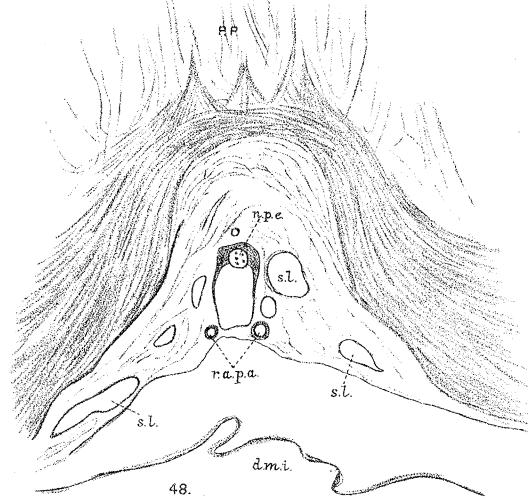
51.



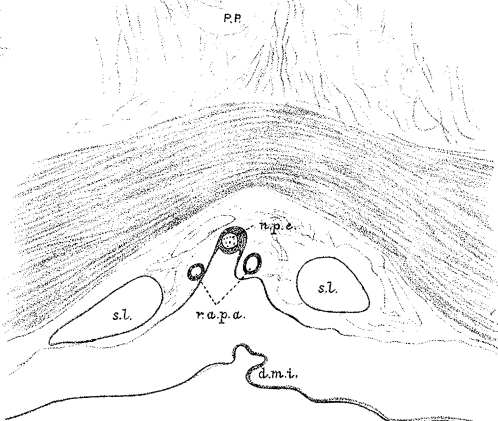
53.



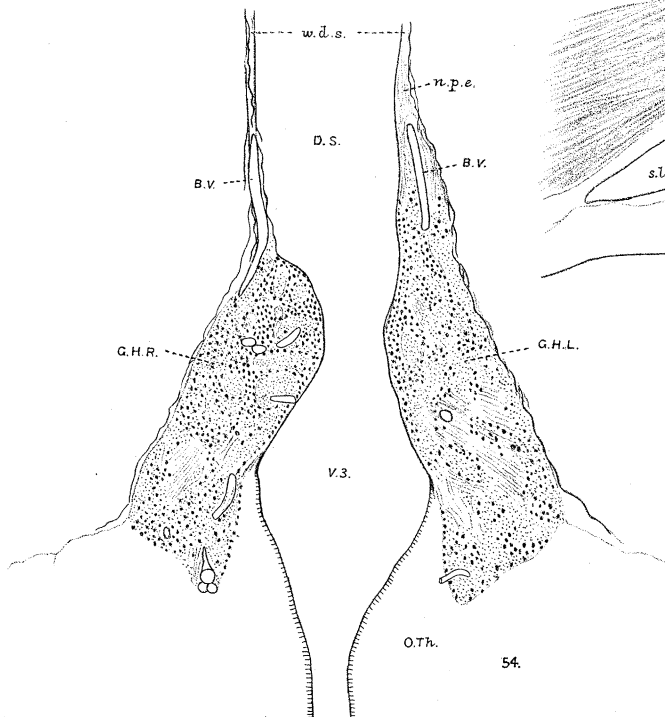
52.



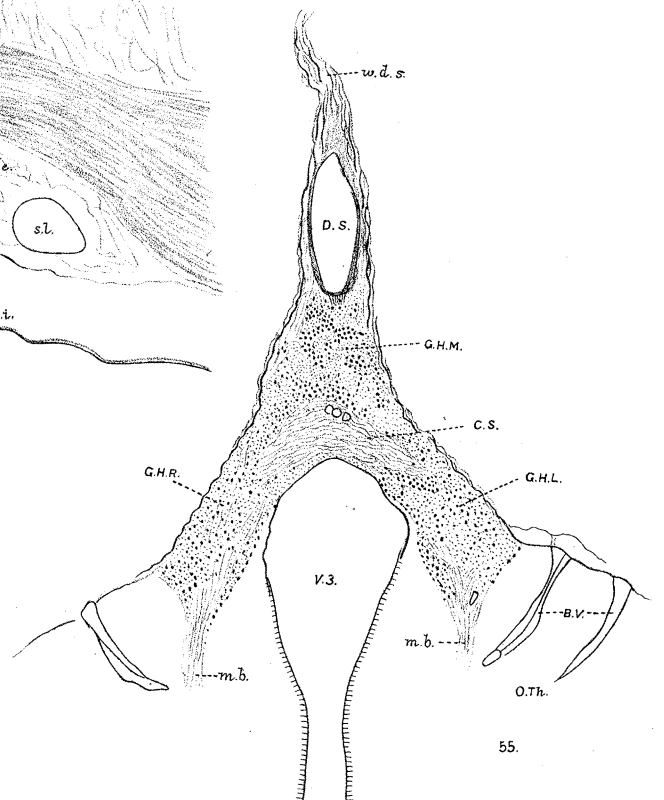
48.



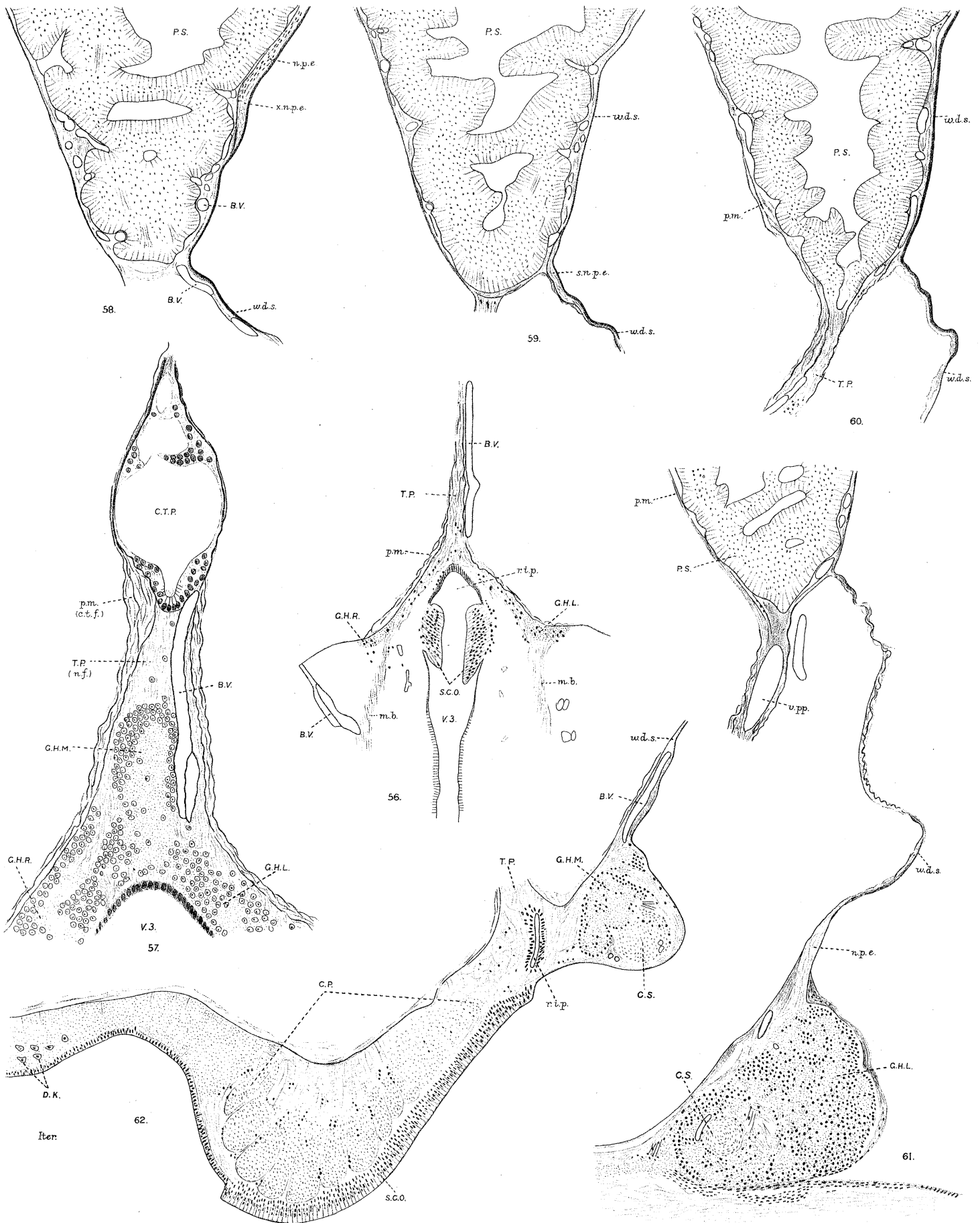
49.

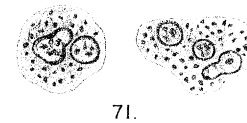
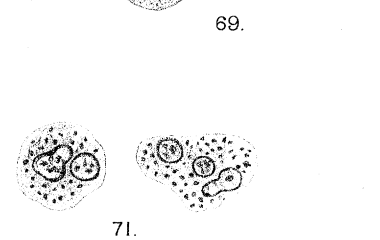
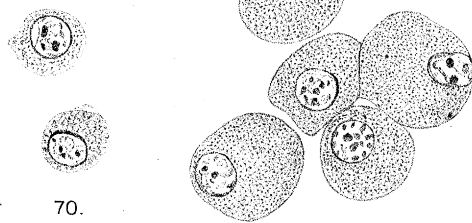
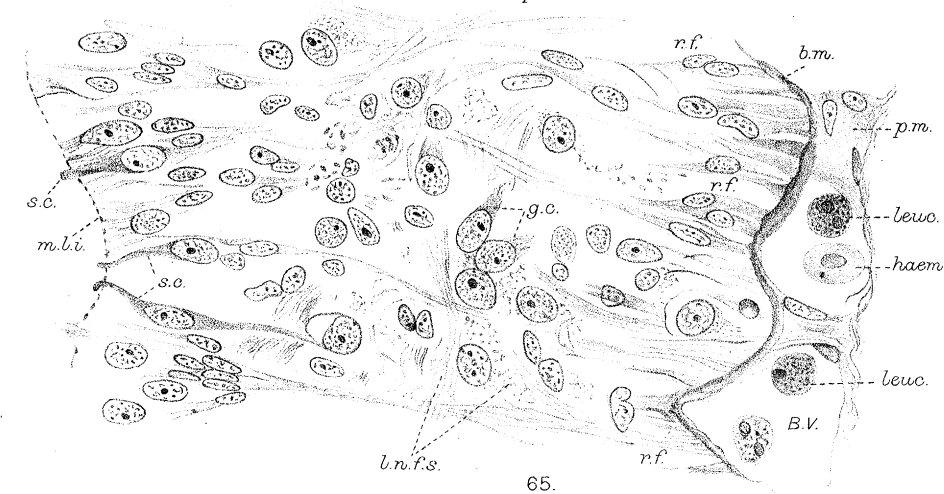
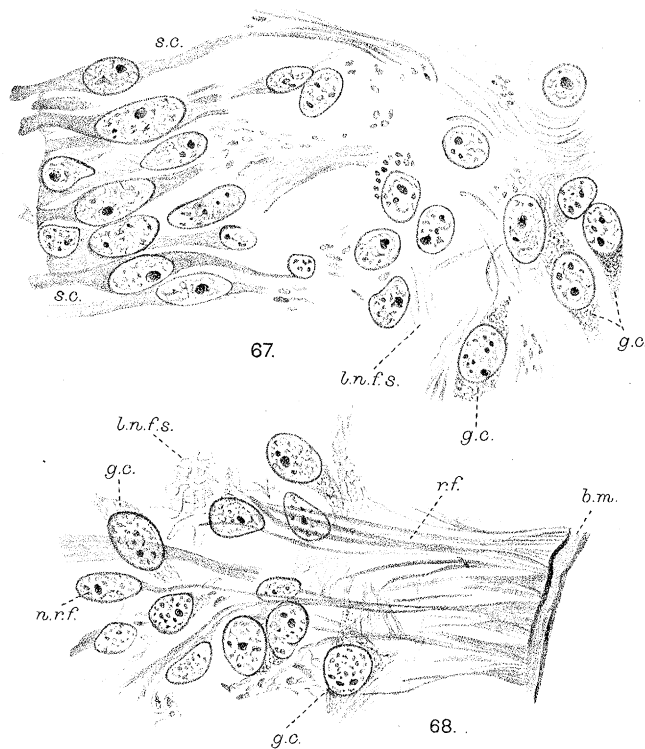
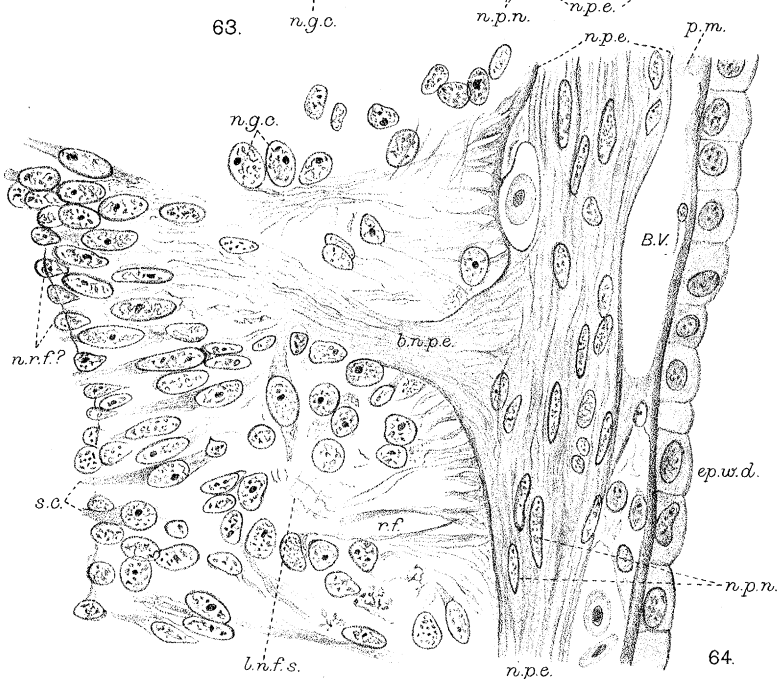
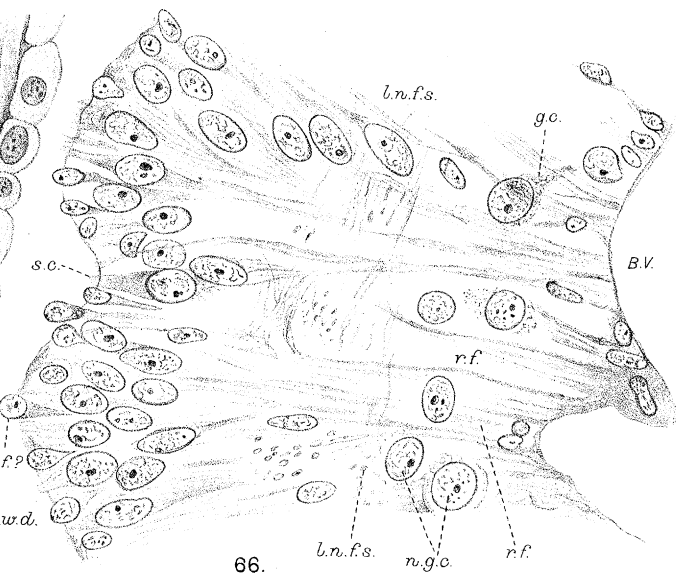
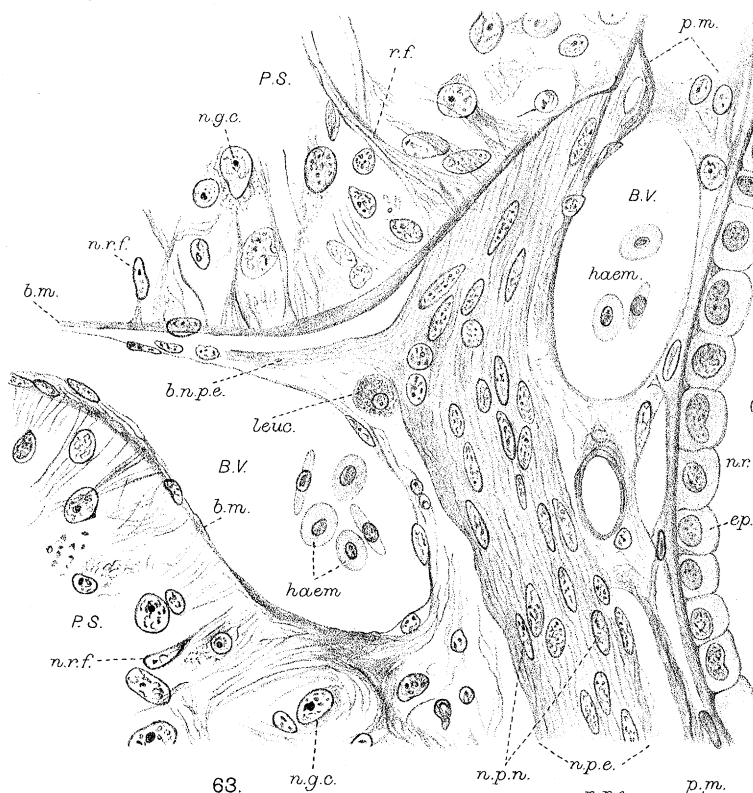


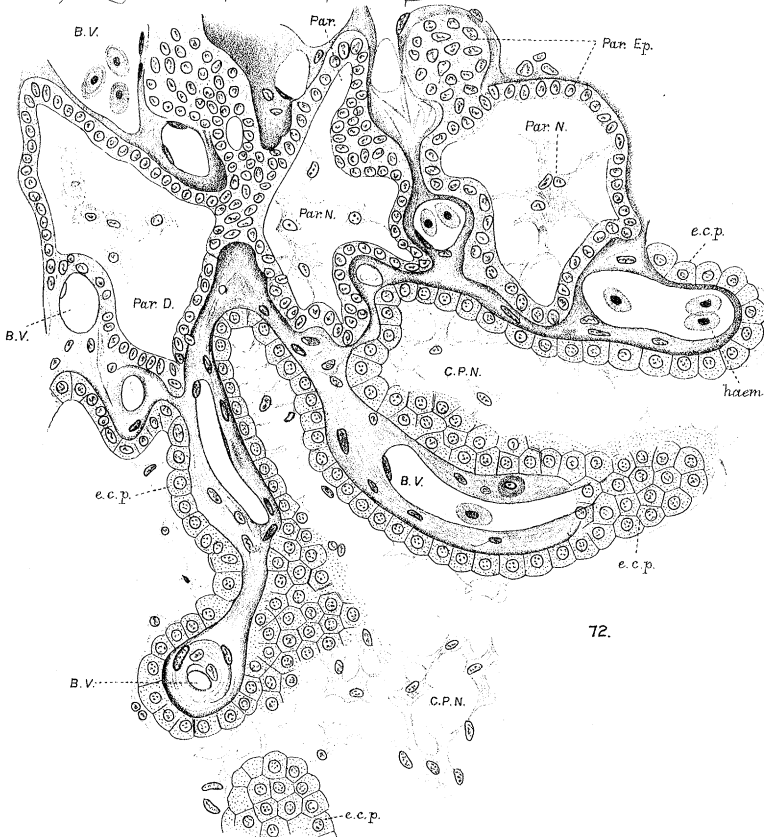
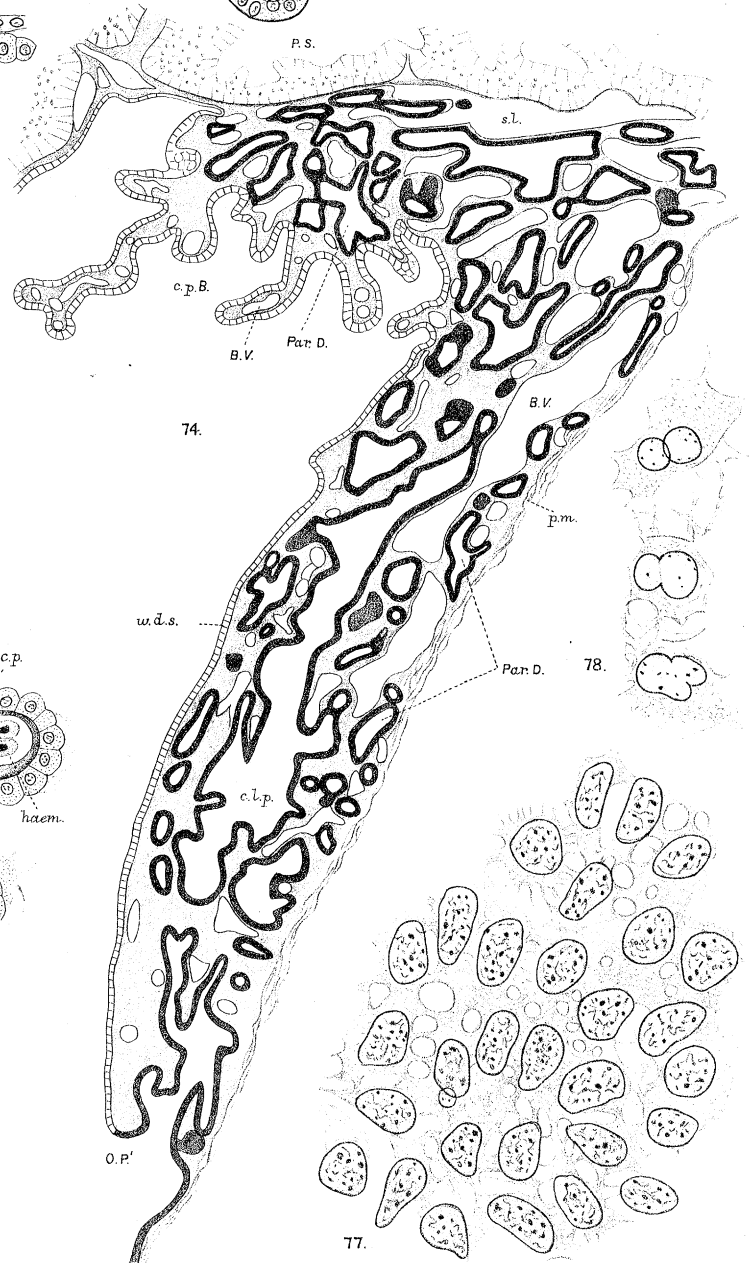
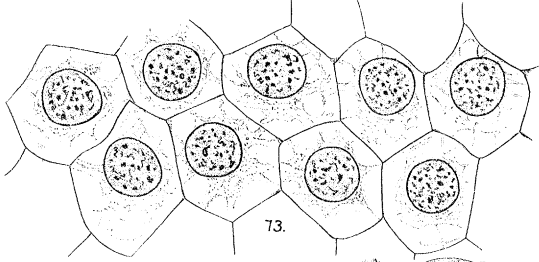
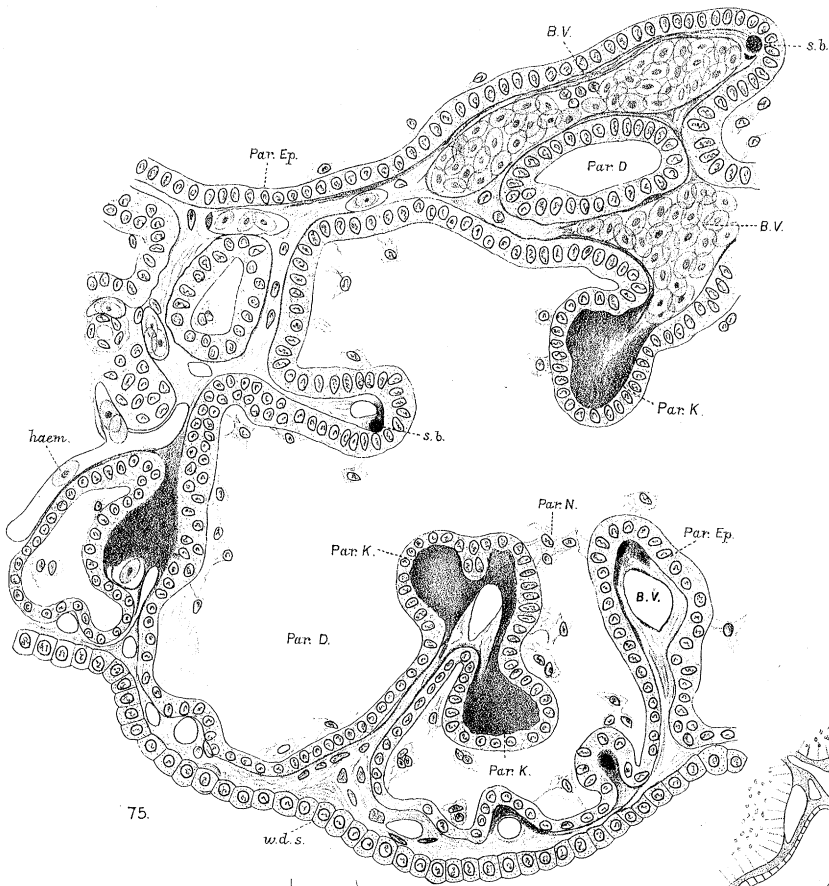
54.



55.







| | | | |
|---------------------|---|----------------------|--|
| <i>r. b. p. a.</i> | Recurrent branch of anterior pineal artery. | <i>s. c. o.</i> , | Sub-commissural organ. |
| | | <i>S. End.</i> , | Saccus endolymphaticus. |
| <i>ret.</i> , | Reticulum in cavity of pineal eye. | <i>s. l.</i> , | Sinus longitudinalis and its irregular branches. |
| <i>R. f.</i> | Reissner's fibre. | <i>s. n. p. e.</i> , | Strand of left pineal nerve. |
| <i>r. f.</i> , | Radial fibres. | <i>S. O.</i> , | Supra-occipital bone. |
| <i>r. g.</i> , | Recessus geniculi. | <i>S. O. C.</i> , | Supra-occipital cartilage. |
| <i>r. i. p.</i> | Recessus infra-pinealis. | <i>str.</i> , | Corpus striatum. |
| <i>r. o.</i> , | Recessus opticus. | <i>Th.</i> , | Thalamencephalon. |
| <i>r. o. l.</i> , | Recessus opticus lateralis. | <i>T. P.</i> , | Tractus pinealis (and right pineal nerve). |
| <i>r. p.</i> , | Paraphysial branch of artery. | | |
| <i>r. p. a.</i> , | Anastomosing paraphysial artery. | <i>t. s. s. c.</i> , | Transverse sections of sense-cells of retina. |
| <i>r. p. e.</i> , | Retina of pineal eye. | <i>V.</i> , | Vein. |
| <i>r. t. p.</i> , | Recessus thalami prænuclearis. | <i>V. 3.</i> | Third Ventricle. |
| | | <i>V. 4.</i> | Fourth Ventricle. |
| <i>R. V. 4.</i> | Roof of fourth ventricle. | <i>v. ch. a.</i> , | Vena choroidea anterior. |
| <i>s. b.</i> , | Spherical deeply staining body beneath the paraphysial epithelium (? commencement of paraphysial knob). | <i>v. ch. p.</i> , | Vena choroidea posterior. |
| | | <i>v. c. p.</i> , | Vena cephalica posterior. |
| | | <i>Ve.</i> , | Velum transversum. |
| | | <i>v. pp.</i> , | Vena parapinealis. |
| <i>s. c.</i> , | Sense-cells. | <i>w. b.</i> , | Wall of brain. |
| <i>S. C. C.</i> , | Supra-commissural canal. | <i>w. d. s.</i> , | Wall of dorsal sac. |
| <i>s. c. c.</i> and | } Recess of dorsal sac overlying commissura aberrans. | <i>x. n. p. e.</i> , | Lower limit of nucleus-bearing portion of nerve of pineal eye. |
| <i>s. c. c.'</i> , | | | |

XIII.—POSTSCRIPT.

Since this memoir was read before the Royal Society another very important paper on the pineal organs of certain Lacertilia, by Dr. M. NOWIKOFF, has appeared.* I have already had occasion to refer to this author's earlier work on the subject (1907), but his more recent memoir is much more complete and enables us to make a very interesting comparison between the pineal organs of *Sphenodon* as described above and those of *Lacerta* and *Anguis*, the chief types examined by NOWIKOFF. In many respects our results are in close agreement, but there are some very important differences which can hardly be attributed to errors of observation on either side.

According to NOWIKOFF the earliest appearance of the pineal or parietal organs in *Lacerta agilis* is in the form of two thickenings of the roof of the thalamencephalon placed one behind the other in the middle line. The anterior thickening forms the pineal eye and the posterior the pineal sac ("epiphysis"). These two organs thus appear to be quite independent of one another in origin. No such early stage has hitherto been observed. Later on the two thickenings become involved in a common evagination of the

* "Untersuchungen über den Bau, die Entwicklung und die Bedeutung des Parietalauges von Sauriern" ('Zeitschrift für wissenschaftliche Zoologie,' Bd. 96, Heft 1, August 2, 1910).

brain-roof, which presently constricts into two parts, the pineal eye and pineal sac*. These interesting observations serve to reconcile the contrary views as to the origin of the pineal organs put forward by previous writers.

In *Lacerta vivipara* the fibres of which the nerve of the pineal eye is composed grow out from ganglion-cells in the retina of the eye while the latter is still lying upon the brain-roof; these fibres join the habenular commissure, which also makes its appearance at about this time. These observations agree with the conclusions at which I have arrived from the study of *Sphenodon*. According to NOWIKOFF however, the point of junction of the nerve with the commissure lies somewhat to the *right* of the middle line, and the fibres, on entering the commissure, turn to the right and pass to the right habenular ganglion. This conclusion is confirmed by observations on the adult *Lacerta agilis* and *Anguis fragilis*. Referring to my earlier work on *Sphenodon*, NOWIKOFF very naturally remarks that a more exact study of this type is necessary in order to decide the question whether the pineal eye is really innervated from different sides of the brain in different reptiles. This more exact study has now been made and, as shown in the present memoir, the results thereof strongly confirm my earlier observations. I think I have now shown beyond question that in *Sphenodon* the pineal eye is an organ of the left side and that its nerve is connected with the left habenular ganglion.

A detailed study of the pineal sac ("epiphysis") and its innervation, however, has led NOWIKOFF to abandon his former view that the pineal sac and pineal eye are serially homologous with one another and both of paired origin, and to adopt the view which I have always maintained, that the pineal eye and pineal sac are members of one and the same pair which have undergone a secondary dislocation into the middle line. We are also in agreement in regarding them as serially homologous with the lateral eyes.

We are thus forced to the extremely important conclusion that, whereas in *Sphenodon* the pineal eye is the left-hand member and the pineal sac the right-hand member of the original pair, in the Lacertilia, so far as these have been examined, the pineal sac is the left-hand member and the pineal eye the right-hand. This remarkable difference certainly serves to emphasise the distinction between the Rhynchocephala and Lacertilia, and even suggests that the common reptilian ancestors of these two groups may have possessed both right and left pineal eyes. Possibly the two eyes lay side by side in the large parietal foramen of some of the extinct reptiles.

As regards the histological structure of the pineal eye, there is evidently a very close agreement between *Sphenodon* on the one hand and *Lacerta* and *Anguis* on the other. The structure of the retina itself is probably almost identical in the three cases. NOWIKOFF, however, still maintains the view that the pigment is lodged actually within the supporting cells. He also still holds that the fibres which occur in the vitreous body are in part derived from processes of the visual cells which are of the nature of fused cilia, a conclusion which he believes to be supported by the occurrence of basal granules in the visual cells. Similar processes are believed to be derived from the lens-cells, which also are said to exhibit basal granules. The cellular elements of the vitreous body he derives, in part at any rate, from intrusive connective-tissue cells which are supposed to migrate through the retina exactly as I have maintained for the wandering pigment-cells in *Sphenodon*.

NOWIKOFF also suggests that both lens and retina may take part in the secretion of the liquid portion of the vitreous body, and figures supposed glandular cells in the lens of *Anguis fragilis* arranged in a group around a small cavity which resembles, except for the absence of pigment, the accessory cavities which I have described in the *retina* of *Sphenodon*. Both structures probably belong to the category of the so-called accessory parietal organs, as also do the evaginations of the distal end of the pineal sac which may occur both in *Sphenodon* and in the Lacertilia.

NOWIKOFF has thus arrived at a conclusion with regard to the glandular nature of the lens in Lacertilia similar to that which I have reached from the study of *Sphenodon*. The histological observations upon

* Fig. 29 of the present memoir, drawn before NOWIKOFF'S work was published, seems to indicate that a similar constriction takes place in *Sphenodon*.

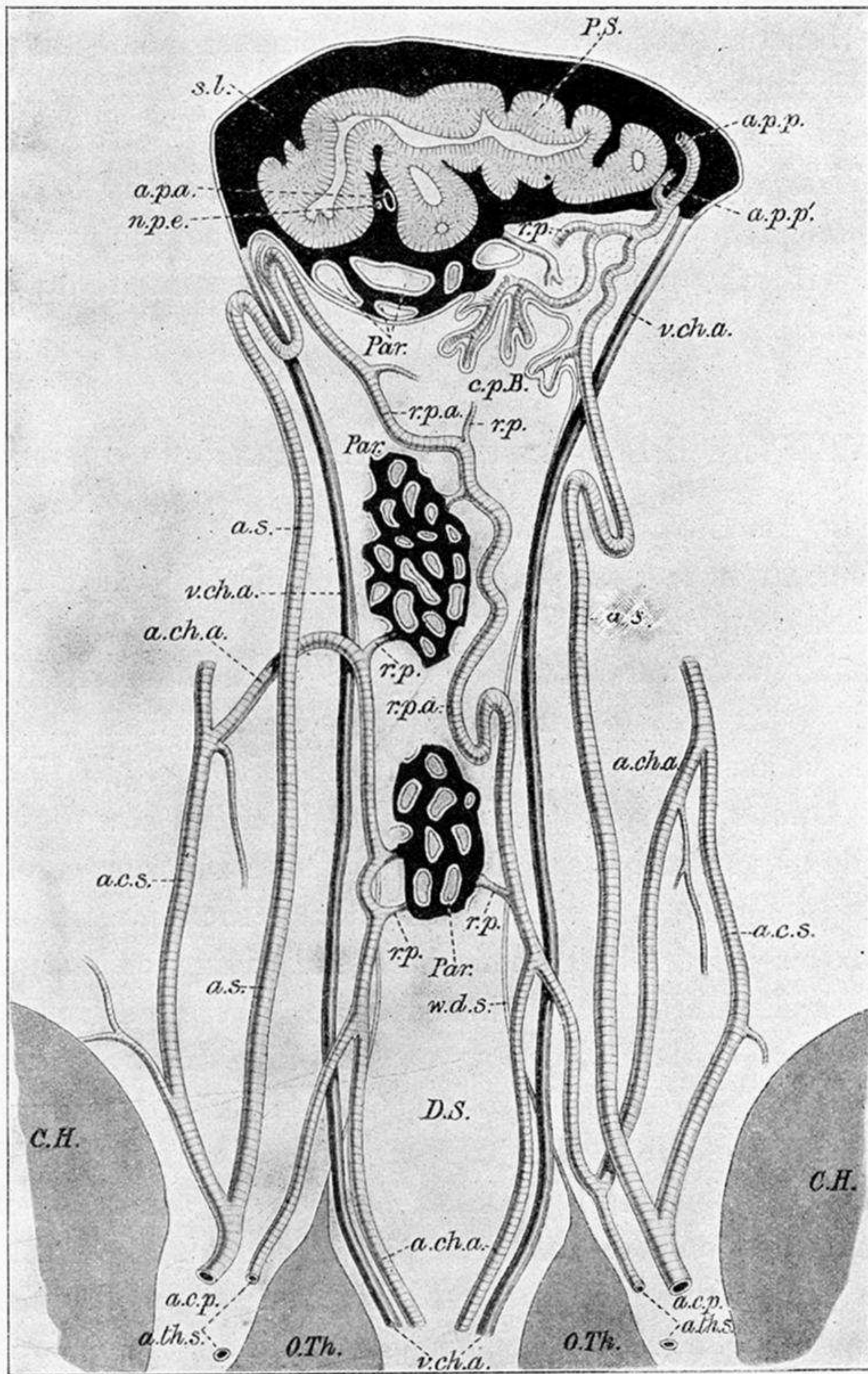
which our conclusions are based, however, differ considerably in the two cases, and NOWIKOFF has not been able to demonstrate the process of secretion as I have done in Sphenodon.

NOWIKOFF maintains that transverse sections of the nerve of the pineal eye show that it consists of a small number (in *Lacerta agilis* about 14—15) of *medullated* nerve-fibres enclosed in a perineurium of connective tissue. In Sphenodon I have found no indication of medullated fibres in the nerve of the pineal eye. The number said to occur in *Lacerta* seems far too small if the fibres in question really come from the eye. I certainly think it more likely that all the fibres coming from the eye are non-medullated, as in Sphenodon.

The histological structure of the pineal sac in Lacertilia, as in Sphenodon, appears to be very similar to that of the retina of the pineal eye, as already pointed out by earlier writers. According to NOWIKOFF, however, the wall of the pineal sac contains no ganglion-cells (as it does in Sphenodon), although in *Lacerta agilis* the nervous layer is present in places. In this species most of the nerve-fibres from the pineal sac go to the posterior commissure, but some to the habenular commissure. The relations of the nerve of the pineal sac are therefore very similar to those of the nerve of the pineal sac in Sphenodon and the nerve of the pineal eye in *Geotria* (DENDY, 1907, *a*).

I am unable to follow NOWIKOFF in his comparison of the pineal and lateral eyes of Vertebrates with the eyes of *Salpa*, but considerations of space forbid the discussion of this question.

As regards the functional capacity of the pineal eye in those Lacertilia in which it is still well developed, NOWIKOFF is in close agreement with the views expressed in the present memoir with regard to Sphenodon. He thinks that it is capable of appreciating variations in the intensity of the illumination, and that it may be of use in warning small and unprotected lizards, when they are sleeping in the sun with their lateral eyes closed, of the approach of flying enemies. This may also be the case with Sphenodon, which, however, can hardly be regarded as a small and unprotected animal.—*September 22nd*, 1910.

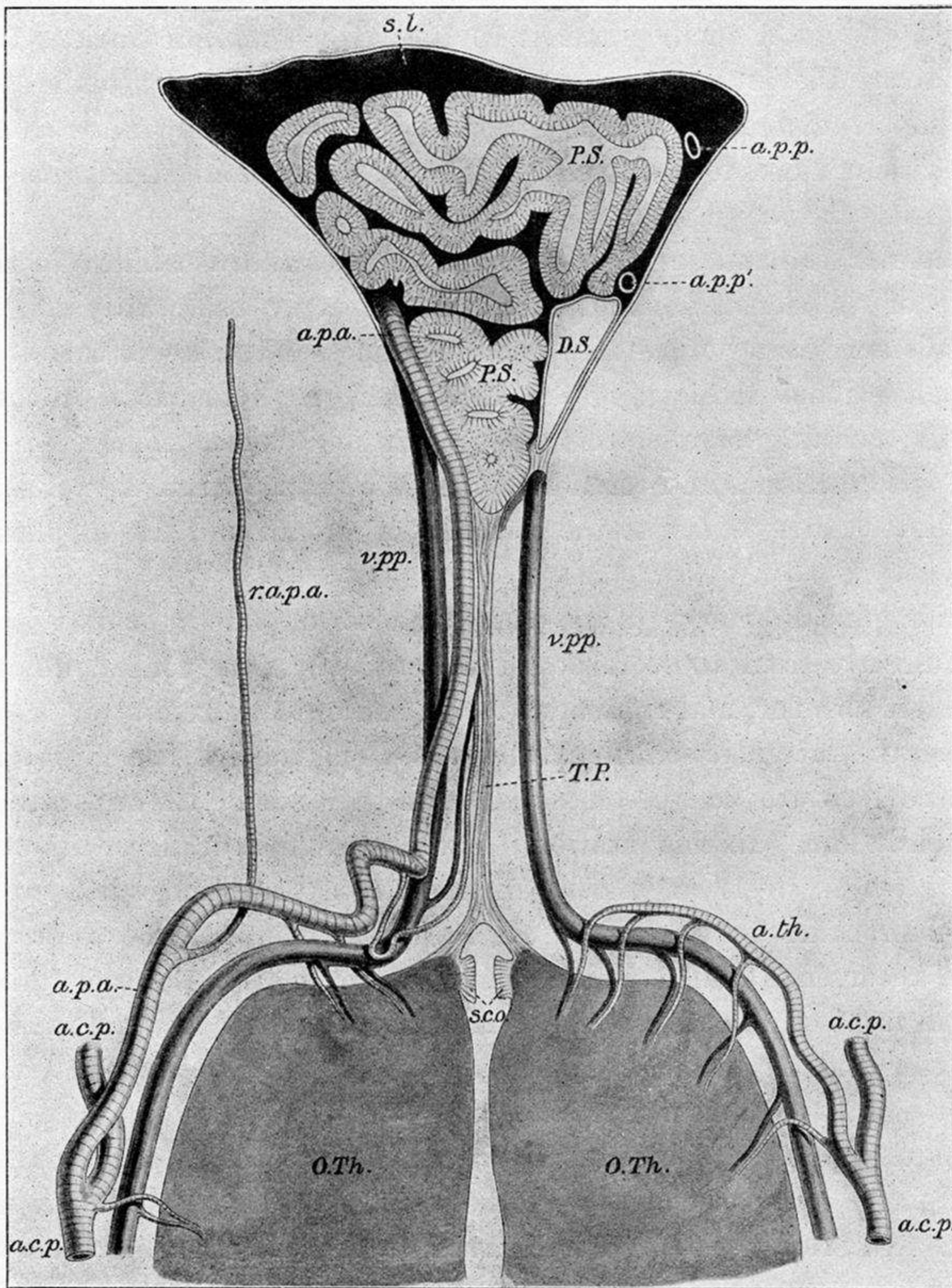


17.

TEXT-FIG. 17.—Diagram of the more Anterior Blood-vessels of the Pineal Complex of Sphenodon VI, projected onto a transverse section.

(For explanation of lettering see pp. 327–329.)


For simplicity the choroid plexus is represented on the right side only.



18.

TEXT-FIG. 18.—Diagram of the more Posterior Blood-vessels of the Pineal Complex of Sphenodon VI, projected onto a transverse section.

(For explanation of lettering see pp. 327-329.)



TEXT-FIG. 20.—Transverse Section through the Posterior Commissure and Sub-Commissural Organ of Sphenodon VI. (From a photograph.)
(For explanation of lettering see pp. 327–329.)

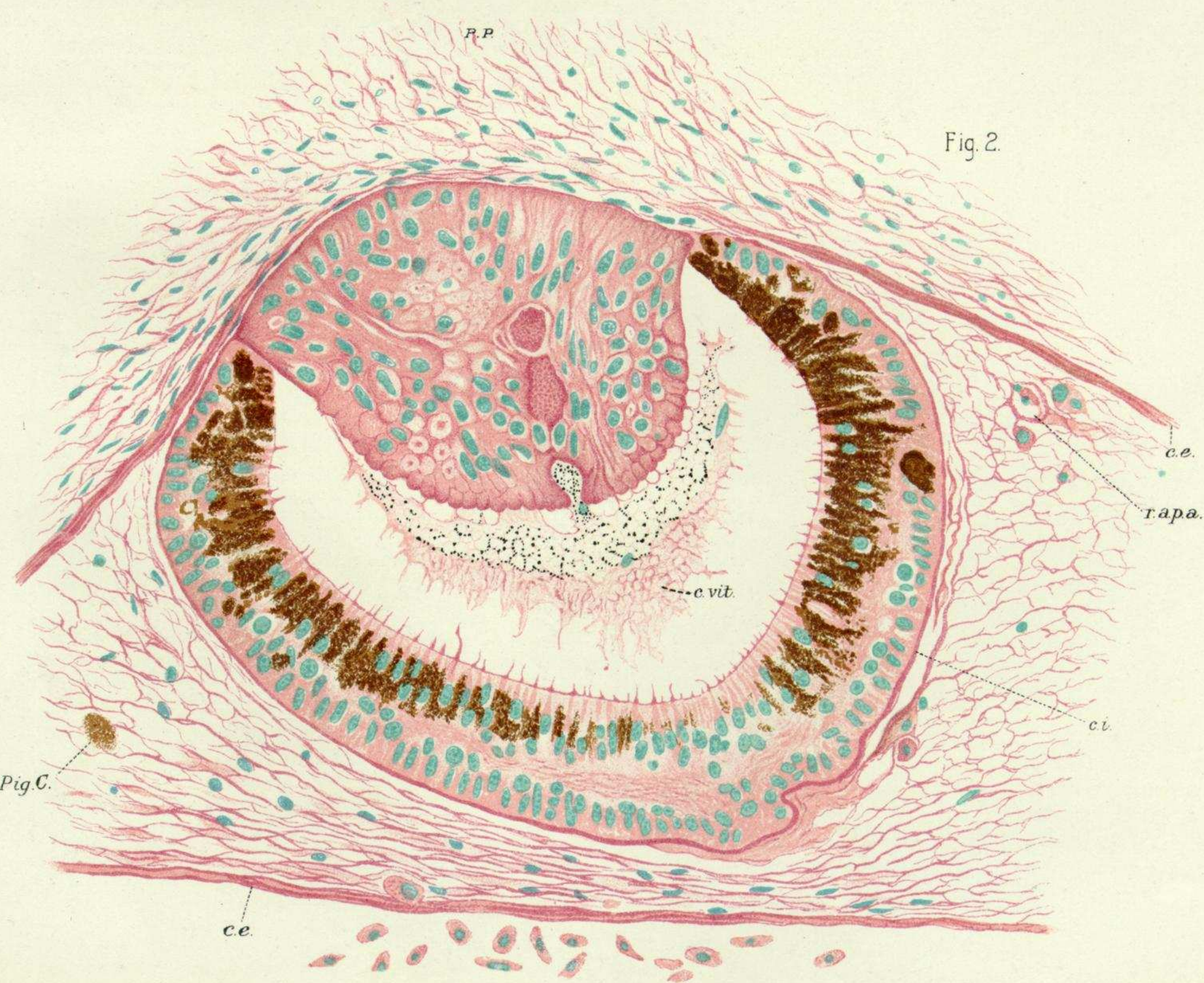
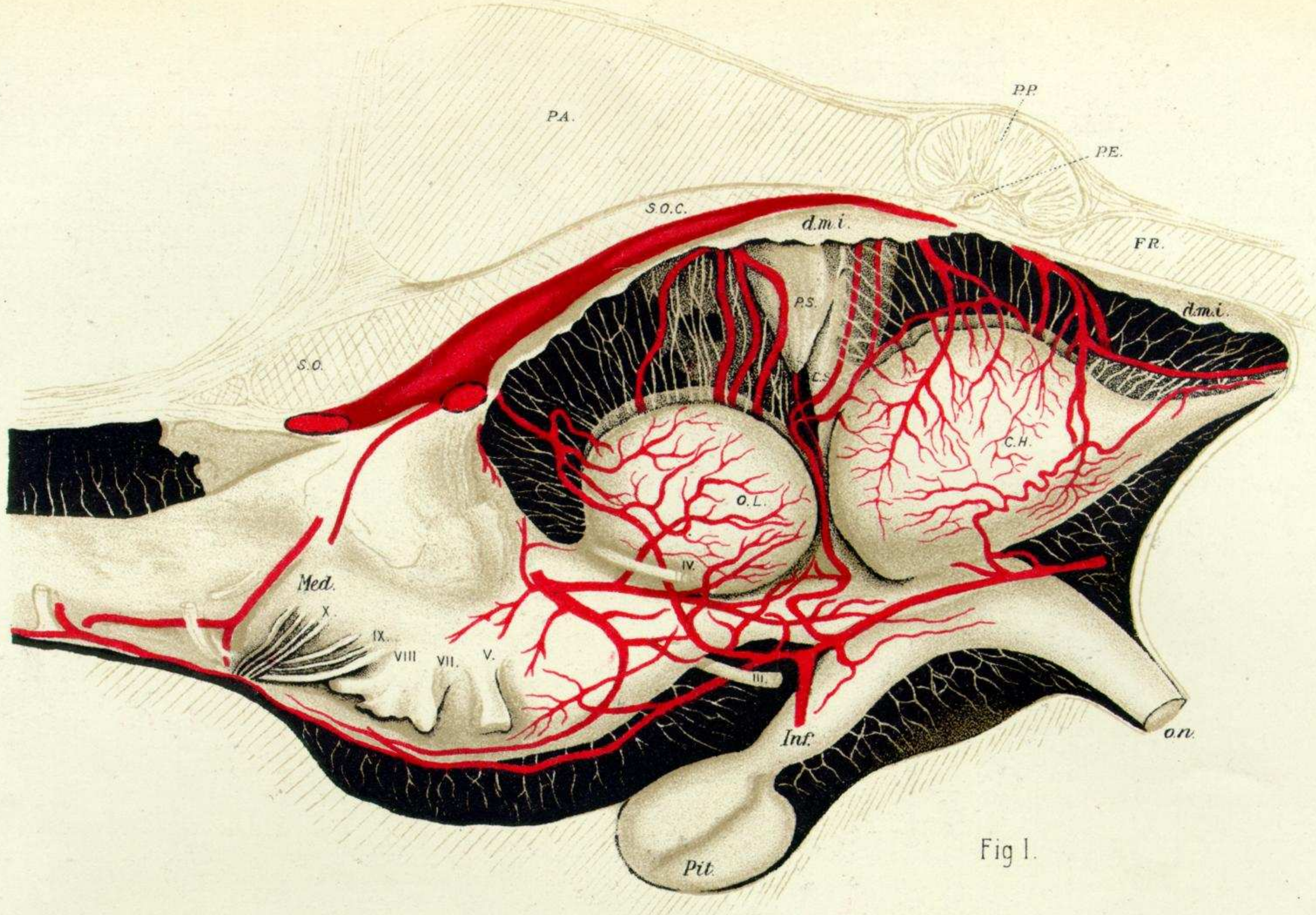


PLATE 19.

Fig. 1.—The brain, lying in the cranial cavity, the cranial wall having been removed from the right side; showing the delicate threads of connective tissue which stretch across the large sub-dural space, the natural position of the pineal complex, and the blood-vessels (for explanation of the blood-vessels, which are coloured red, see DENDY [1909, a]). (Sphenodon V.) × 6.

Fig. 2.—A nearly sagittal section through the pineal eye. Stained with Ehrlich's haematoxylin and eosin; showing especially the formation of the vitreous body by secretion from the lens. (Sphenodon I.)

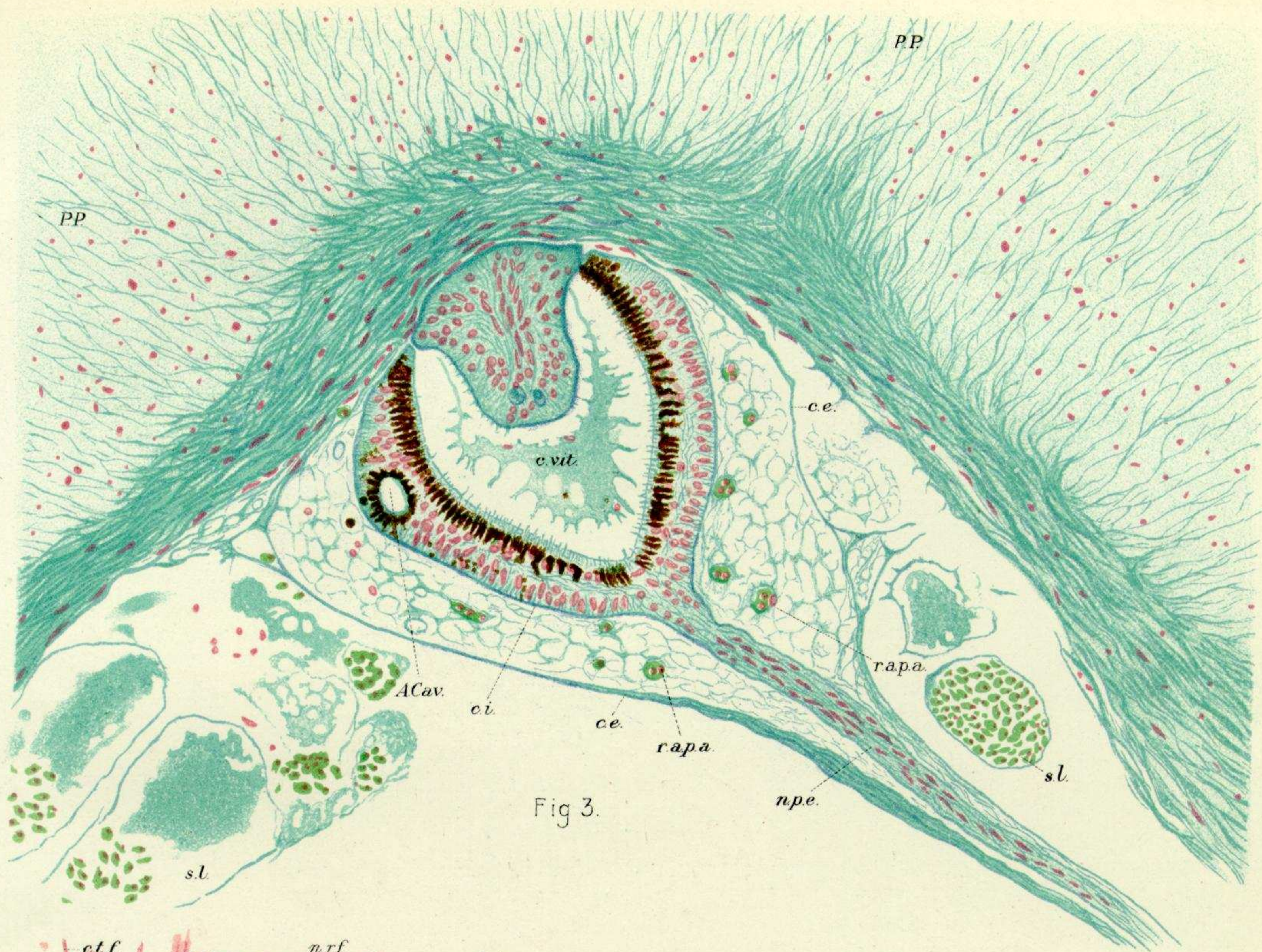


Fig. 3.

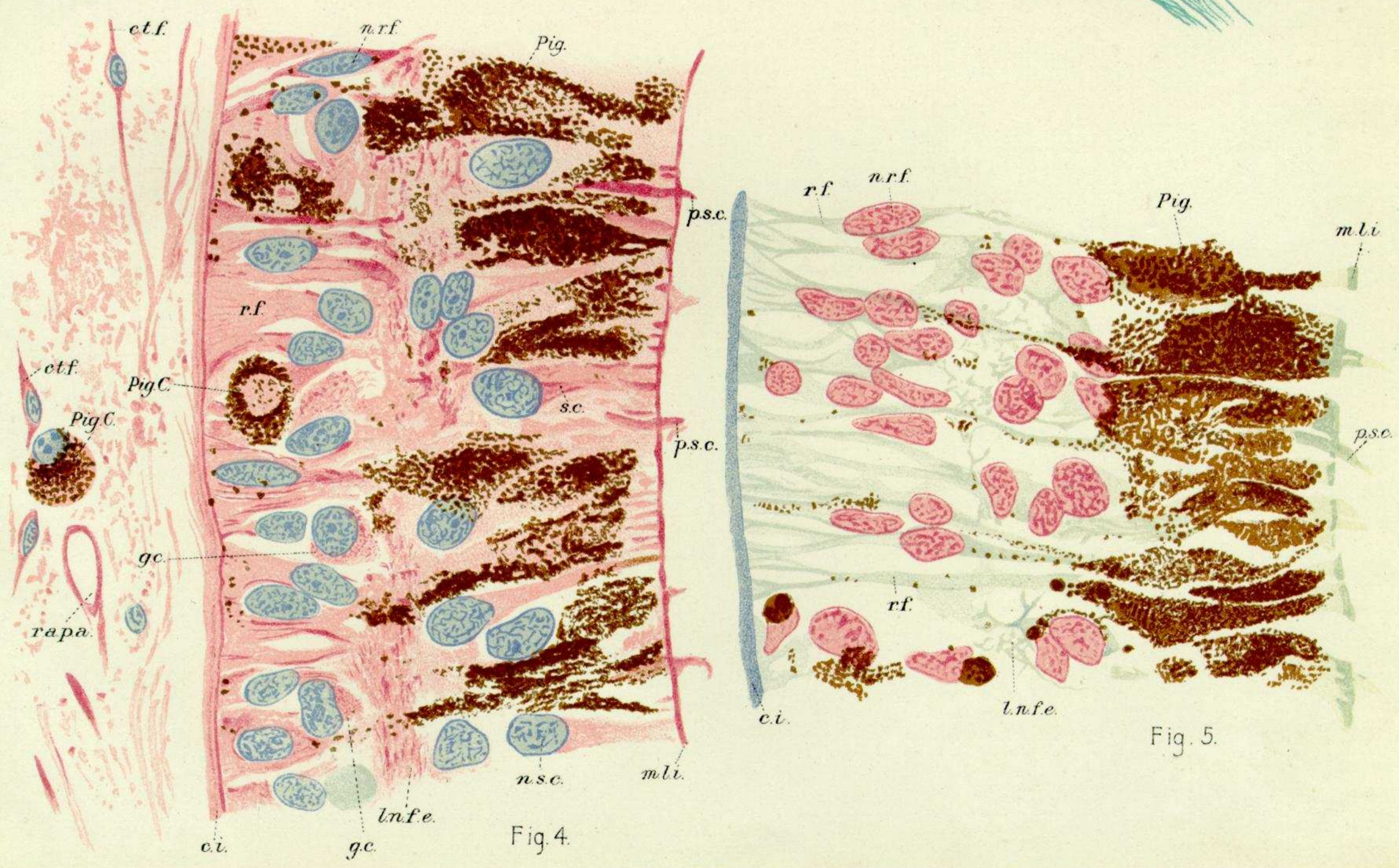


Fig. 4.

Fig. 5.

PLATE 20.

- Fig. 3.—Sagittal section of the pineal eye and nerve, capsule of the eye, parietal plug, etc. Stained with borax carmine and picro-indigo-carmin. (Sphenodon V.)
- Fig. 4.—Section of the retina of the pineal eye. Stained with Ehrlich's haematoxylin and eosin. (Sphenodon I.)
- Fig. 5.—Section of the retina of the pineal eye. Stained with borax carmine and picro-indigo-carmin. (Sphenodon V.)

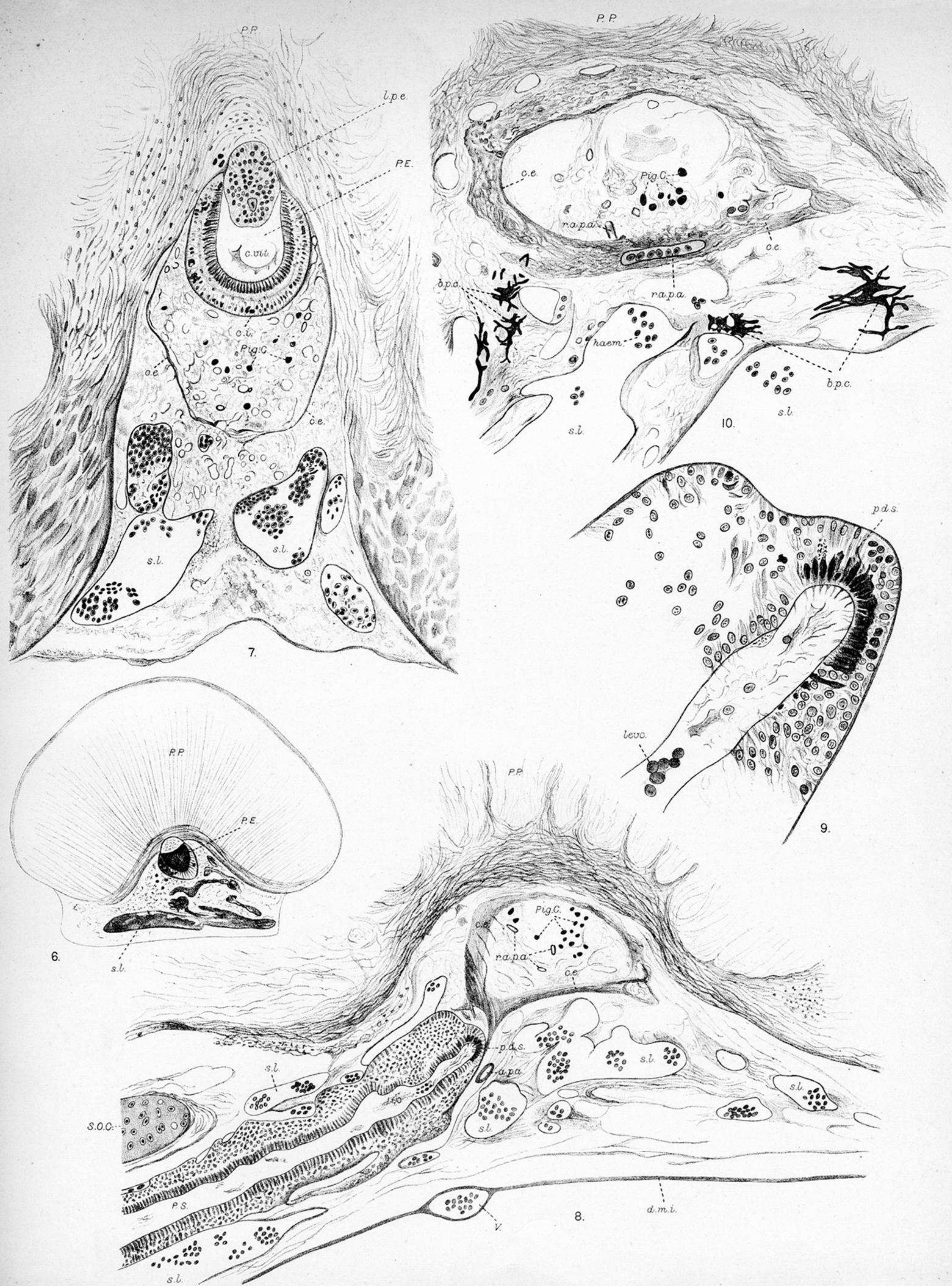


PLATE 21.

Fig. 6.—Optical sagittal section of the parietal plug and pineal eye viewed in cedar oil as a transparent object after removal from the parietal foramen, without staining. (Sphenodon V.)

Fig. 7.—Transverse section through the pineal eye, lying in its capsule beneath the parietal plug. (Sphenodon VI.) $\times 75$.

Fig. 8.—Nearly sagittal section through the tip of the pineal sac and the capsule of the pineal eye, lying beneath the parietal plug; showing the pigmented diverticulum of the pineal sac, etc. (Sphenodon II.) $\times 50$.

Fig. 9.—The portion of the same section containing the pigmented evagination of the pineal sac, more highly magnified. $\times 220$.

Fig. 10.—Part of another section of the same series showing the small pigment-cells inside and the large branched pigment-cells outside the capsule of the pineal eye. $\times 102$.

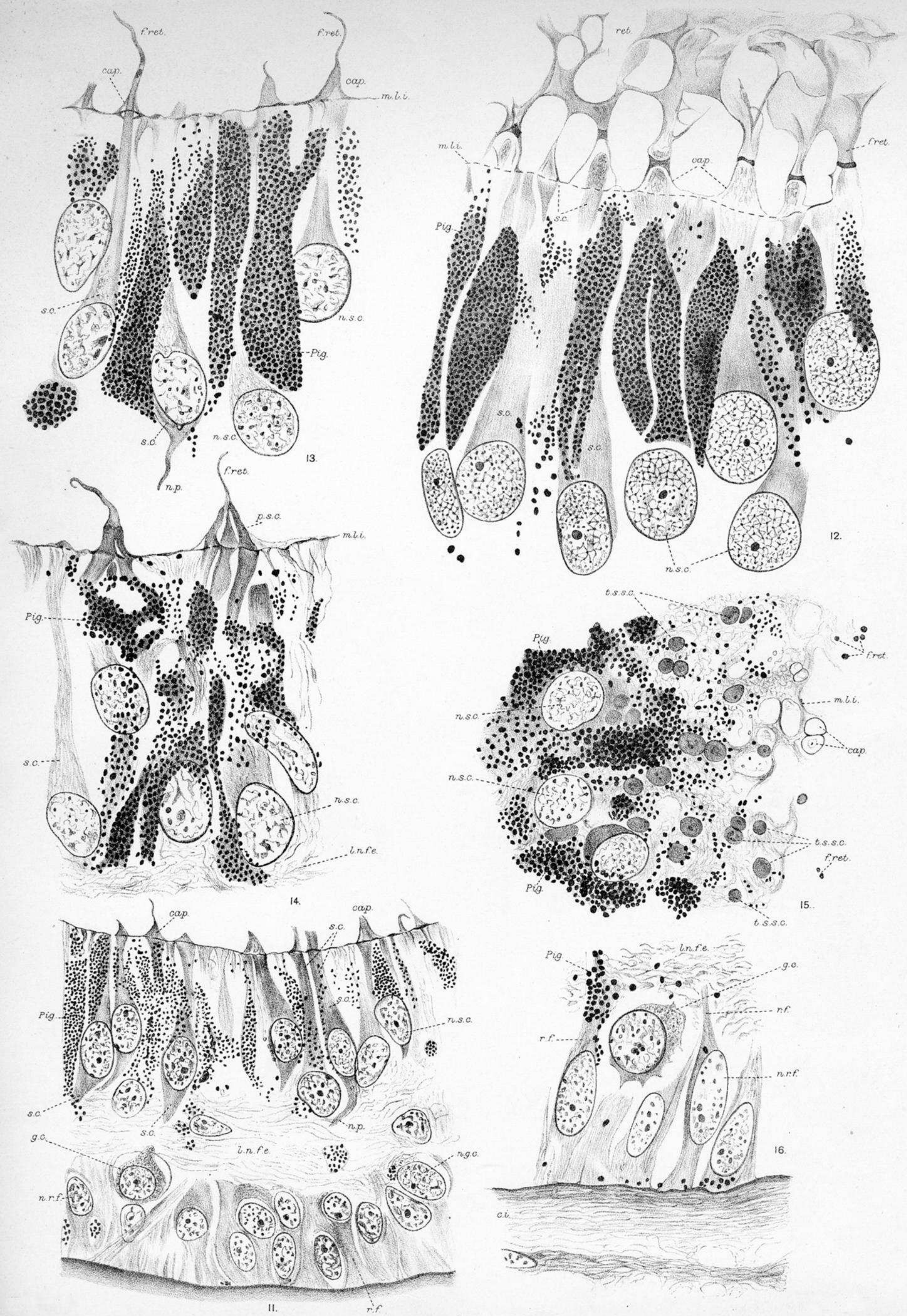


PLATE 22.

Fig. 11.—Portion of a vertical section of the retina of the pineal eye; stained with Ehrlich's hæmatoxylin and picro-indigo-carmin, to show especially the sense-cells in a place (near the optic axis) where there is comparatively little pigment. (Sphenodon I.) $\times 1000$.

Fig. 12.—Portion of a vertical section of the retina of the pineal eye, to show especially the sense-cells and the caps which cover their projecting ends, and the connection of the caps with the vitreous reticulum. Stained with Ehrlich's hæmatoxylin only. (Sphenodon A.) $\times 1660$.

Fig. 13.—Portion of a vertical section of the retina of the pineal eye, showing especially the sense-cells with their projecting ends and caps. Stained with Ehrlich's hæmatoxylin and picro-indigo-carmin. (Sphenodon I.) $\times 1660$.

Fig. 14.—Portion of a vertical section of the retina of the pineal eye, showing grouping of the sense-cells. Stained with Ehrlich's hæmatoxylin and eosin. (Sphenodon I.) $\times 1660$.

Fig. 15.—Tangential section of inner part of retina of the pineal eye, showing the sense-cells cut across. Stained with Ehrlich's hæmatoxylin and eosin. (Sphenodon I.) $\times 1660$.

Fig. 16.—Portion of a vertical section of the retina of the pineal eye, showing the outer nucleated ends of the radial supporting fibres and a ganglion-cell. Stained with Ehrlich's hæmatoxylin and eosin. (Sphenodon I.) $\times 1660$.

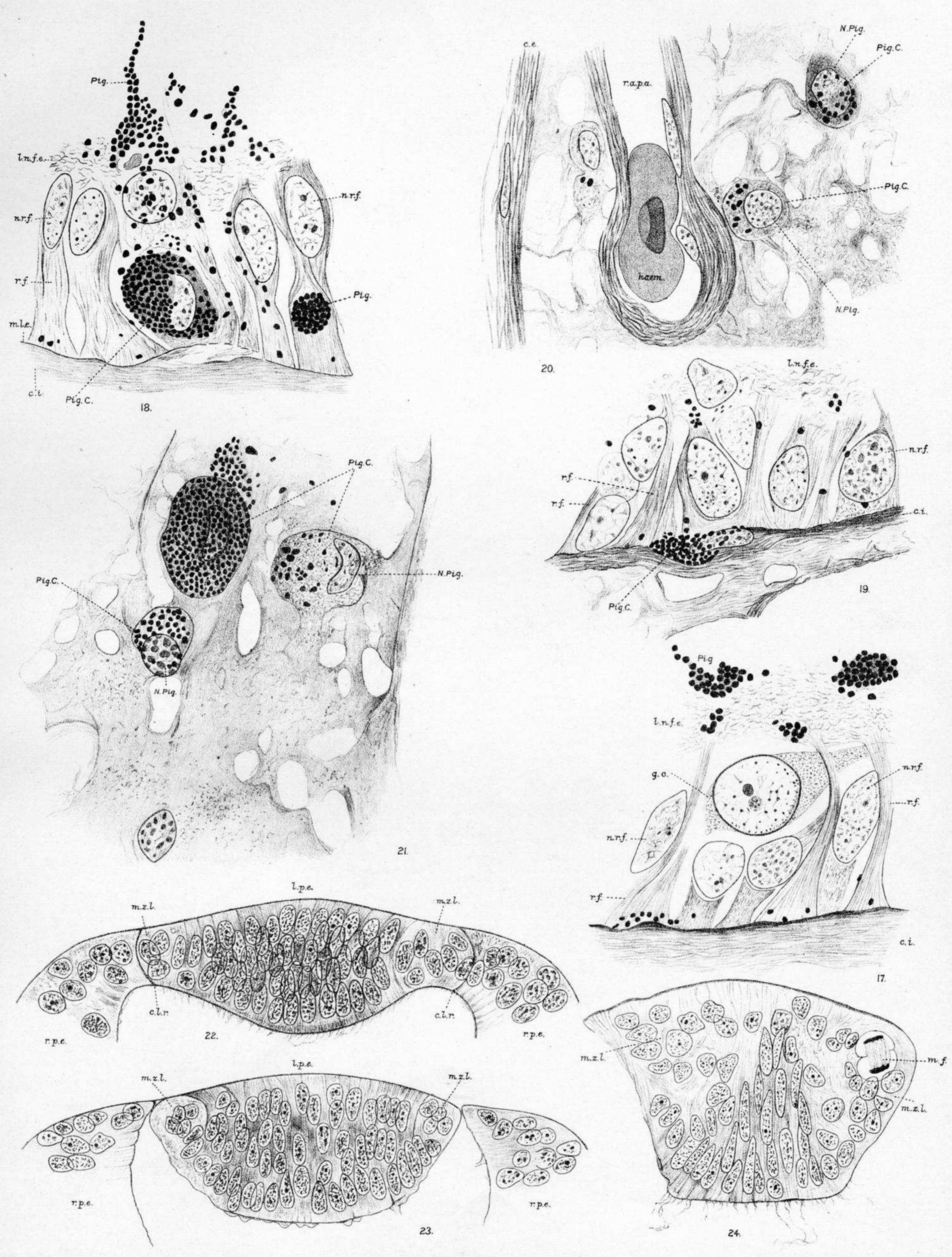


PLATE 23.

- Fig. 17.—Portion of a vertical section of the retina of the pineal eye, showing the outer nucleated ends of the radial supporting fibres and a ganglion-cell. Stained with Ehrlich's hæmatoxylin and eosin. (*Sphenodon I.*) $\times 1660$.
- Fig. 18.—Portion of a vertical section of the retina of the pineal eye, showing the outer nucleated ends of the radial supporting fibres and a large nucleated pigment-cell which has apparently just forced its way in through the internal capsule and external limiting membrane of the eye. Stained with Ehrlich's hæmatoxylin and eosin. (*Sphenodon I.*) $\times 1660$.
- Fig. 19.—Portion of a vertical section of the retina of the pineal eye, showing the outer nucleated ends of the radial supporting fibres and a pigment-cell lying in the internal capsule of the eye. Stained with Ehrlich's hæmatoxylin and eosin. (*Sphenodon I.*) $\times 1660$.
- Fig. 20.—Part of section through the external capsule of the pineal eye and the tissues between it and the internal capsule; showing a branch of the anterior pineal artery and a number of wandering cells containing pigment-granules. Stained with Ehrlich's hæmatoxylin and eosin. (*Sphenodon I.*) $\times 1660$.
- Fig. 21.—Part of section of the tissue between the external and internal capsules of the pineal eye, showing pigment-cells containing varying amounts of pigment. Stained with Ehrlich's hæmatoxylin and eosin. (*Sphenodon I.*) $\times 1660$.
- Fig. 22.—Vertical section through front part of wall of pineal eye, showing developing lens. Stained with Ehrlich's hæmatoxylin and Orange G. (Embryo 37*a.* Stage O-P.) $\times 518$.
- Fig. 23.—Vertical section through front part of wall of pineal eye, showing developing lens. Stained with Ehrlich's hæmatoxylin and picro-indigo-carmin. (Embryo 51*a.* Stage P-Q.) $\times 518$.
- Fig. 24.—Vertical section of developing lens of pineal eye, showing (on the right) mitosis in the marginal zone. Stained with Ehrlich's hæmatoxylin and Orange G. (Embryo 142. Stage R.) $\times 518$.

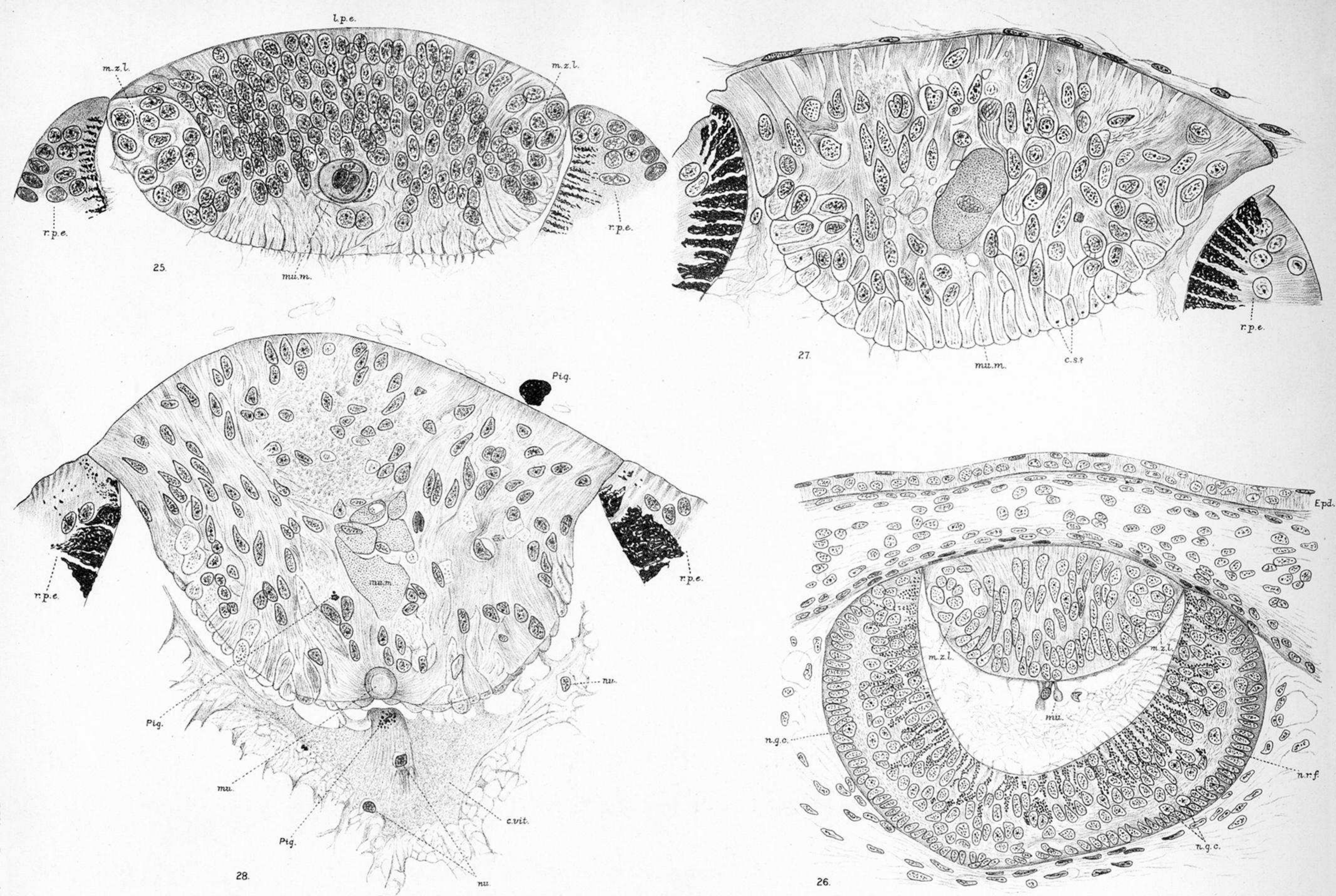

PLATE 24.

Fig. 25.—Vertical section of developing lens of pineal eye, showing in the interior a spherical mass of mucus with contained nuclei. Stained with Ehrlich's hæmatoxylin and Orange G. (Embryo 159. Stage R.) $\times 518$.

Fig. 26.—Vertical section of developing pineal eye. Pigment is just appearing in the retina and the lens has begun to exude drops of mucus into the cavity of the eye. The differentiation of the lens into marginal and central portions is very clearly shown. Stained with borax carmine and picro-indigo-carmin. (Embryo 141. Stage R.) $\times 333$.

Fig. 27.—Vertical section through adult lens of pineal eye, showing the large central mucus-mass, with nucleus, etc., and the almost complete separation from the retina. Stained with Ehrlich's hæmatoxylin. (Sphenodon A.) $\times 480$.

Fig. 28.—Vertical section through adult lens and vitreous body of pineal eye, showing secretion of mucus by the lens, etc. Stained with Ehrlich's hæmatoxylin and picro-indigo-carmin. (Sphenodon I.) $\times 480$.

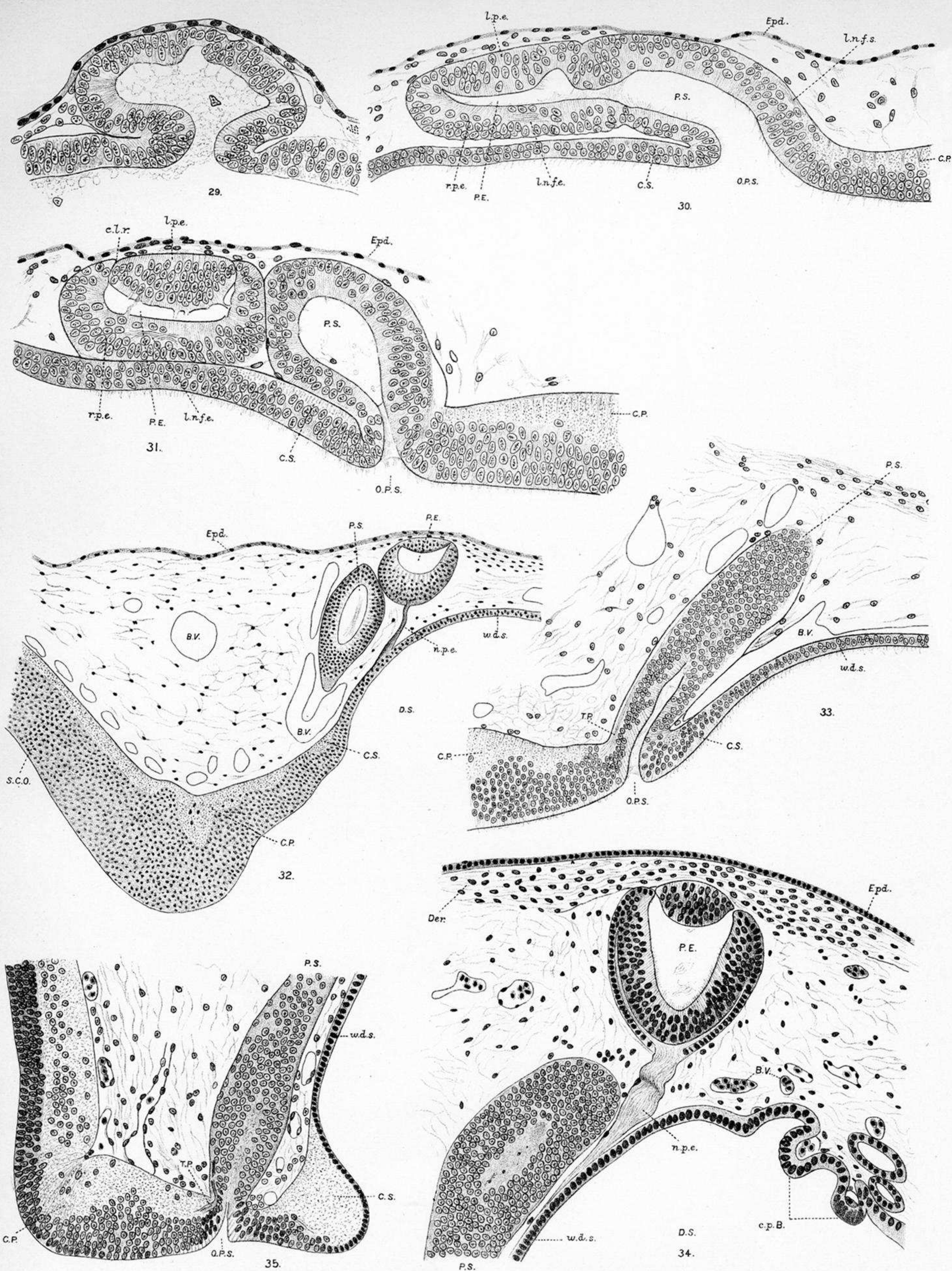


PLATE 25.

Fig. 29.*—Part of sagittal section through the roof of the brain at Stage L, showing the development of the primary parietal vesicle. Stained with borax carmine. (Embryo 50.) $\times 220$.

Fig. 30.—Part of sagittal section through the roof of the brain at about Stage O, showing the developing pineal sac and eye with their cavities still in open communication with one another, etc. Stained with Ehrlich's hæmatoxylin and picro-indigo-carmin. (Embryo 32*a*.) $\times 220$.

Fig. 31.—Part of sagittal section through the roof of the brain at about Stage N-O, showing the developing pineal eye and sac separated from one another. Stained with Ehrlich's hæmatoxylin and picro-indigo-carmin. (Embryo 24*a*.) $\times 220$.

Fig. 32.—Vertical longitudinal section through the developing pineal organs at about Stage O-P, showing the nerve of the pineal eye, etc. Stained with Ehrlich's hæmatoxylin and Orange G (combined from several sections). (Embryo 37*a*.) $\times 75$.

Fig. 33.—Part of another section from the same series as fig. 32, but a little to the right of the section represented in that figure, and through the opening of the pineal sac, which may be taken as approximately in the middle line. Stained with Ehrlich's hæmatoxylin and Orange G. $\times 127$.

Fig. 34.—Part of longitudinal vertical section through the developing pineal organs at about Stage Q, showing the nerve of the pineal eye, etc. Stained with Ehrlich's hæmatoxylin and Orange G. (Embryo 52*a*.) $\times 127$.

Fig. 35.—Part of another section from the same series as fig. 34, but a little to the right of the section represented in that figure, and through the opening of the pineal sac, which may be taken as approximately in the middle line. Stained with Ehrlich's hæmatoxylin and Orange G. (Embryo 52*a*.) $\times 127$.

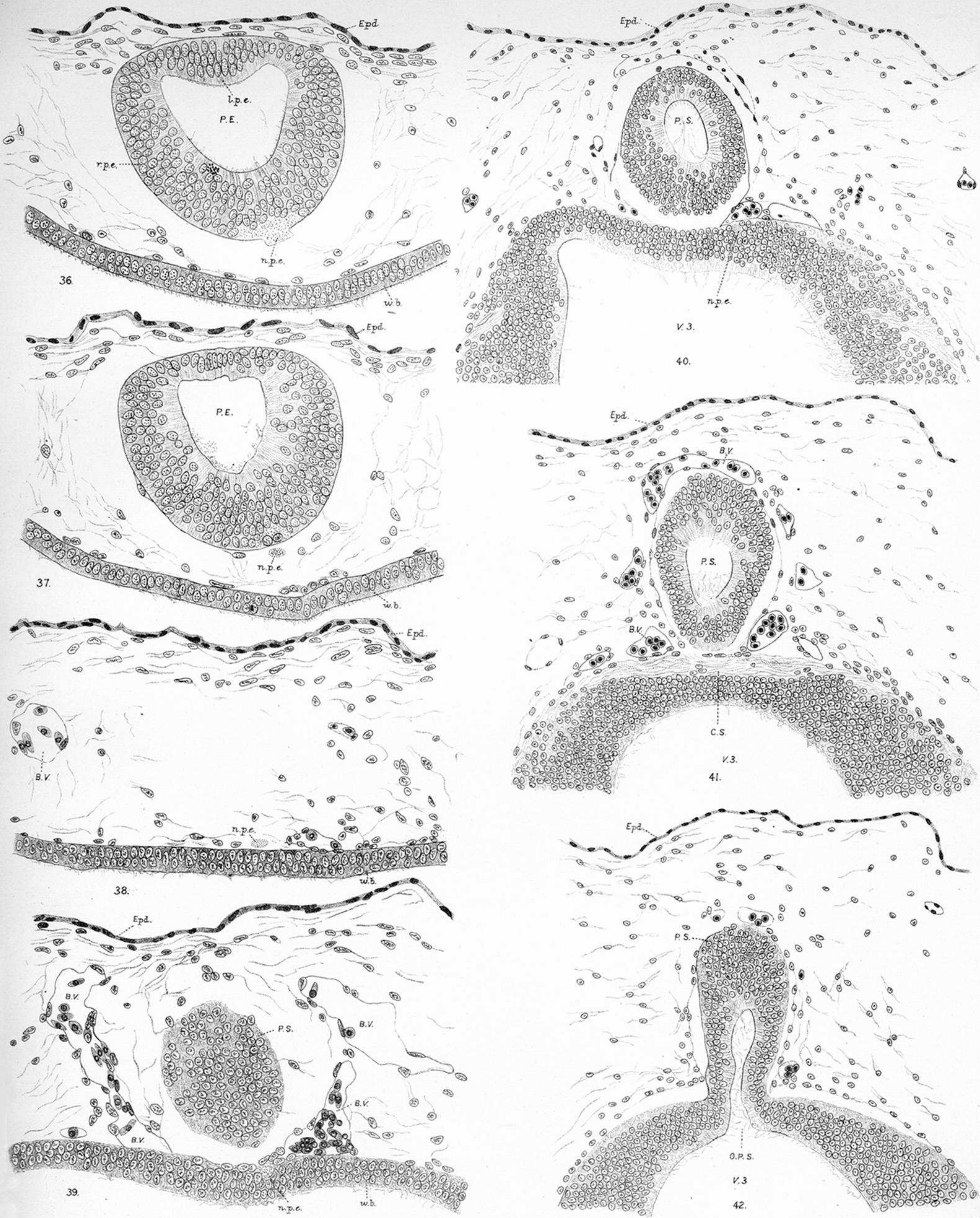


PLATE 26.

All the figures on this plate are from a series of transverse sections of the head of Embryo 39a, Stage P, stained with Ehrlich's hæmatoxylin and Orange G. They show the course of the nerve of the pineal eye, from the eye to the brain, always on the left side of the middle line, right and left sides being reversed in the figures. (Compare figs. 32 to 35.)

Fig. 36.—Section through the junction of the nerve with the retina of the pineal eye. $\times 220$.

Fig. 37.—Section showing the nerve lying free between the pineal eye and the roof of the brain. $\times 220$.

Fig. 38.—Section showing the nerve lying just above the roof of the brain, in the interval between the pineal eye and pineal sac. $\times 220$.

Fig. 39.—Section showing the nerve closely attached to the roof of the brain beneath the apex of the pineal sac. $\times 220$.

Fig. 40.—Section showing the nerve just entering the thickening of the brain-roof which will form the left habenular ganglion. $\times 127$.

Fig. 41.—Section through the superior commissure, just in front of the opening of the pineal sac. $\times 127$.

Fig. 42.—Section through the opening of the pineal sac. $\times 127$.

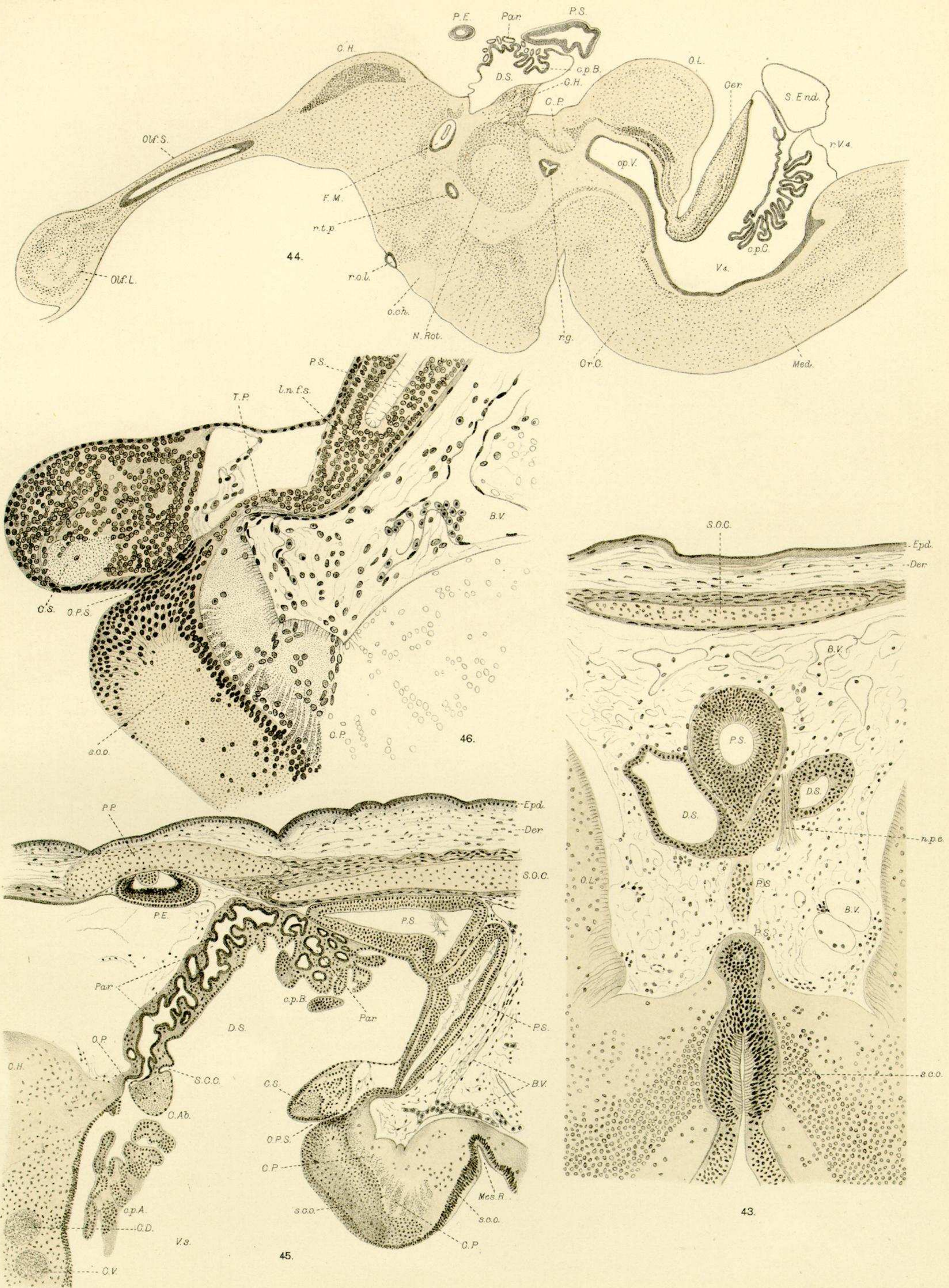


PLATE 27.

Fig. 43.—Part of transverse section through the pineal region of Embryo 162 (Stage R), stained with Ehrlich's hæmatoxylin and Orange G; to show especially the position of the nerve of the pineal eye to the left of the middle line (apparent right owing to reversal). Note also the sub-commissural organ and its connection with the lower part of the pineal sac (recessus infra-pinealis), and the backward extensions of the dorsal sac. $\times 75$.

Fig. 44.—Longitudinal vertical section of the entire brain of Embryo II (Stage S), a little to the left of the median plane, showing especially the lateral diverticula of the fore- and mid-brain. Stained with Ehrlich's hæmatoxylin and Orange G. $\times 19$.

Fig. 45.—Part of an approximately median section of the same series as fig. 44, showing the relation of the pineal organs and associated parts of the brain. Stained with Ehrlich's hæmatoxylin and Orange G. $\times 50$.

Fig. 46.—Part of another section of the same series, more enlarged, showing the superior and posterior commissures, tractus pinealis, sub-commissural organ, etc. Stained with Ehrlich's hæmatoxylin and Orange G. $\times 127$.

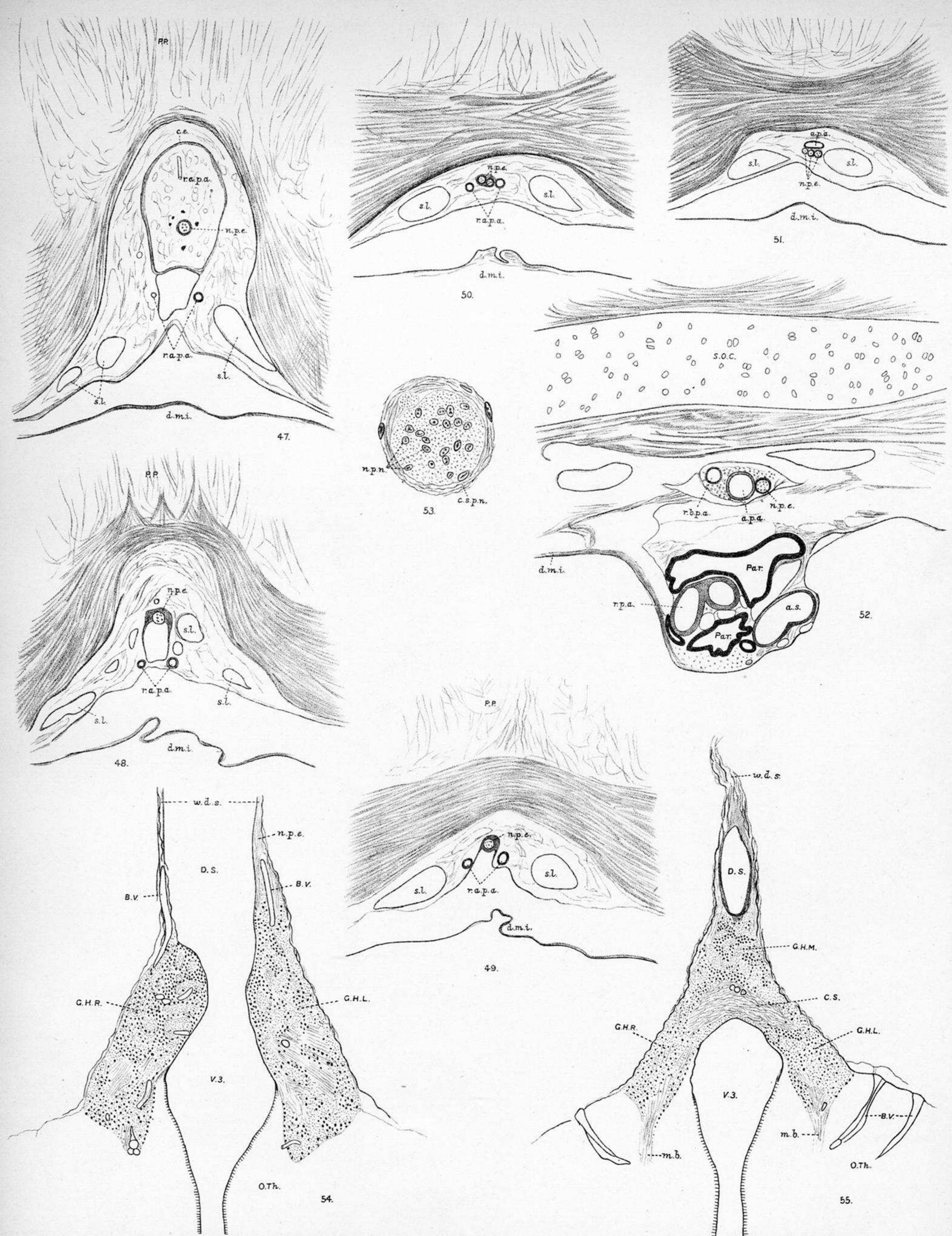


PLATE 28.

Figs. 47-52.—Selections from a series of transverse sections of *Sphenodon* VI, to show the course of the more anterior portion of the nerve of the pineal eye and the anterior pineal artery, etc., in the adult (working backwards). In fig. 47 the nerve is still in the capsule of the eye. In figs. 50 and 51 it has left the capsule and has broken up into separate strands. In fig. 52 the strands have united again and the nerve is just coming into contact with the apex of the pineal sac, while the paraphysis is seen beneath it (the further course of the nerve and artery are shown in text-figs. 13-16 taken from the same series of sections). $\times 50$.

Fig. 53.—Transverse section of the nerve of the pineal eye and its connective-tissue sheath. From the same series of sections as figs. 47-52. Stained with borax carmine and picro-indigo-carmin. $\times 414$.

Fig. 54.—Transverse section through the habenular ganglia, showing nerve-fibres entering the upwardly prolonged left habenular ganglion from the wall of the dorsal sac. (*Sphenodon* VI, same series of sections as preceding figures.) $\times 50$

Fig. 55.—Transverse section through the superior commissure and habenular ganglia and posterior edge of dorsal sac. (*Sphenodon* VI, same series of sections as preceding figures.) $\times 50$.

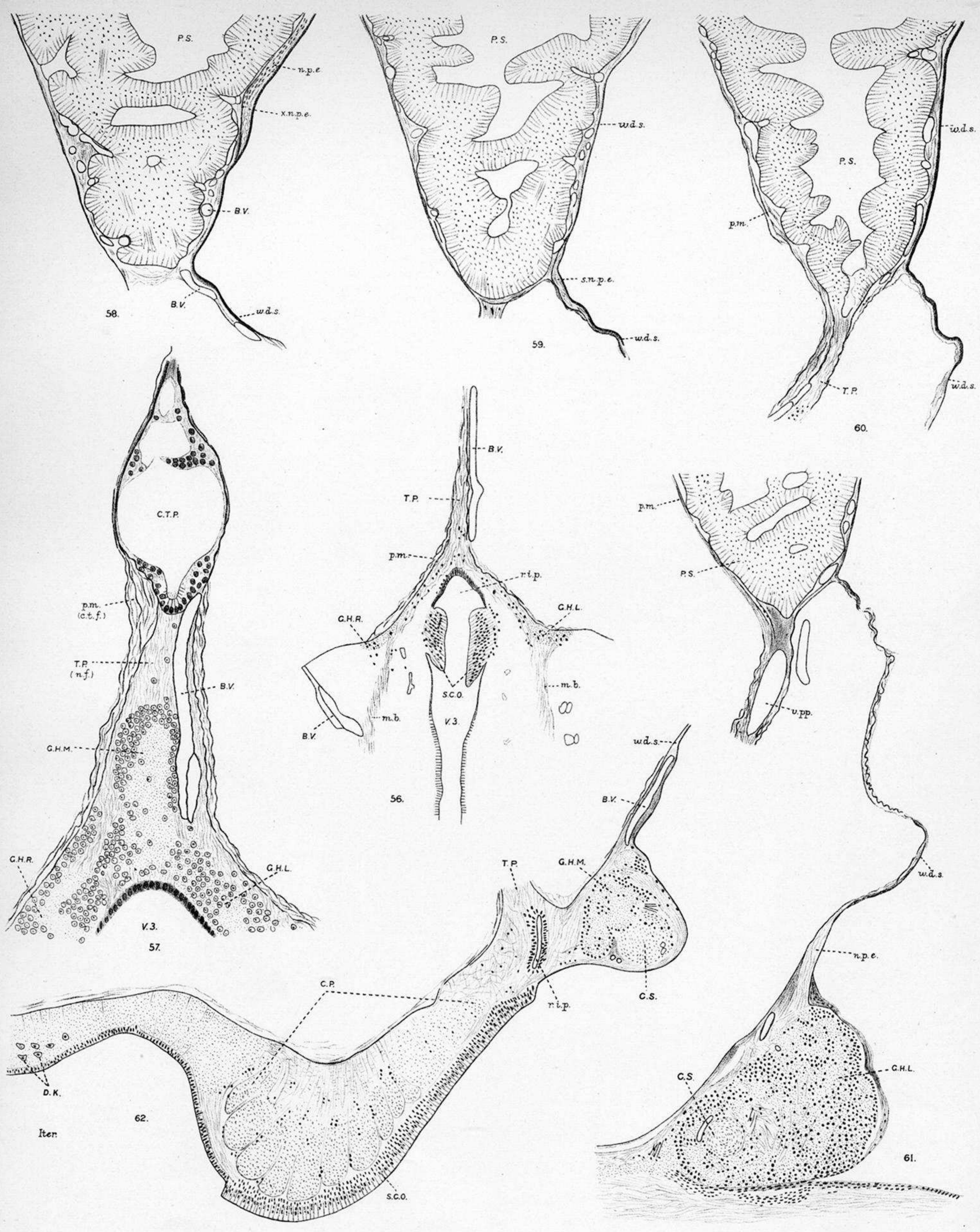


PLATE 29.

- Fig. 56.—Transverse section through the infra-pineal recess and junction of the tractus pinealis with the brain, showing the anterior end of the sub-commissural organ, Meynert's bundles, etc. (Sphenodon VI, same series of sections as preceding figures.) $\times 50$.
- Fig. 57.—Transverse section through the lower part of the tractus pinealis, median habenular ganglion, etc. (Sphenodon VI, same series of sections as preceding figures and between the sections represented in figs. 55 and 56, but more highly magnified.) Note the cavity in the tractus pinealis with an "ependymal groove" in its floor. $\times 127$.
- Fig. 58.—Longitudinal vertical section through the lower extremity of the pineal sac, showing the place where the nerve of the pineal eye loses its nuclei and breaks up. (Sphenodon V.) $\times 50$.
- Fig. 59.—Another section from the same series, but rather more to the right, showing a strand of the nerve of the pineal eye entering the wall of the dorsal sac. $\times 50$.
- Fig. 60.—Another section from the same series, but still more to the right, showing the tractus pinealis leaving the pineal sac. $\times 50$.
- Fig. 61.—Another section from the same series, again a little more to the right but showing the left habenular ganglion below and a bundle of nerve-fibres entering it from the wall of the dorsal sac. $\times 50$.
- Fig. 62.—Combined drawing from several sections of the same series as the preceding, through the posterior and superior commissures, infra-pineal recess, lower extremity of tractus pinealis, and sub-commissural organ. $\times 50$.

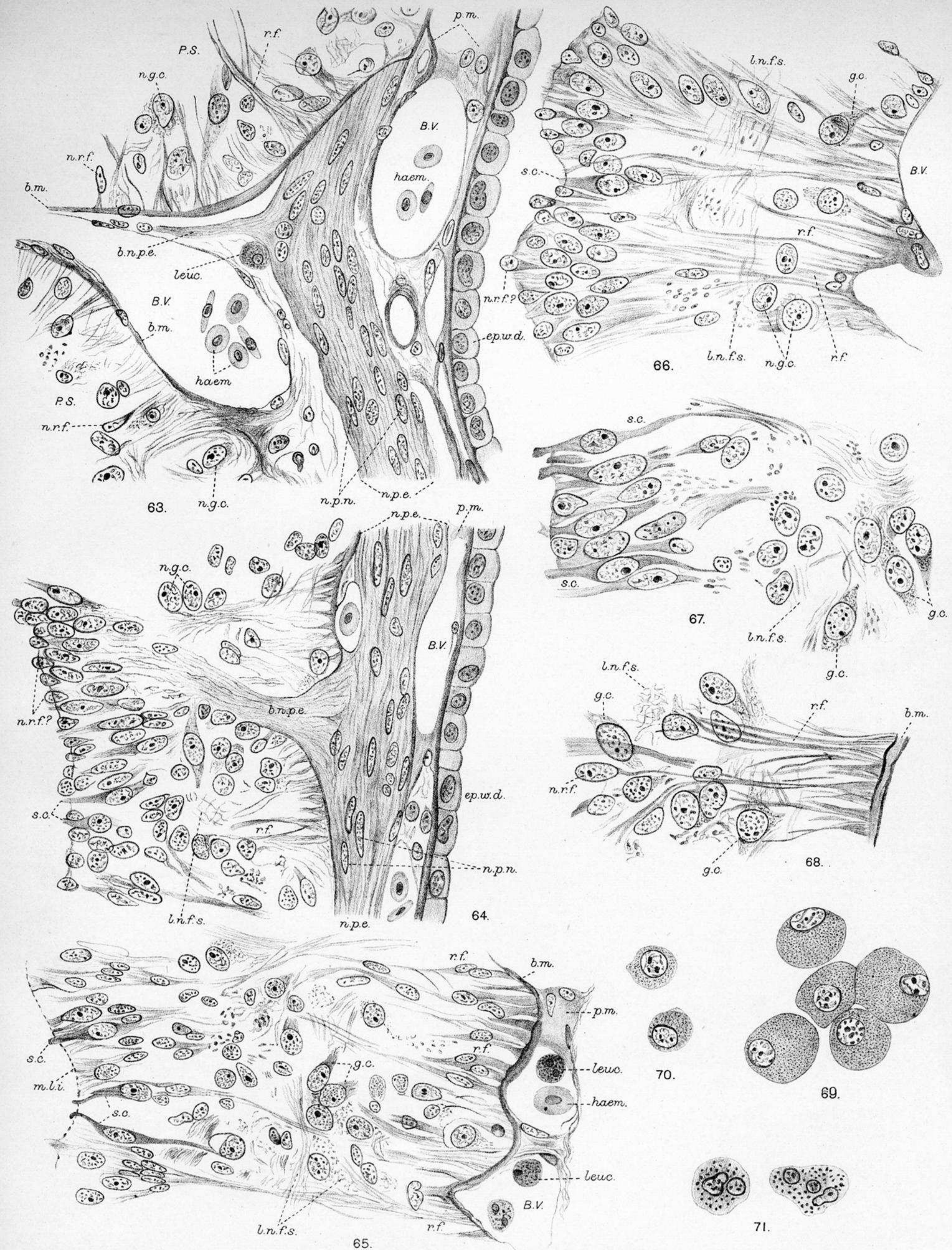


PLATE 30.

Fig. 63.—Part of longitudinal vertical section through wall of dorsal sac, nerve of pineal eye and wall of pineal sac, to show histological details. (*Sphenodon V.*) $\times 518$.

Fig. 64.—Part of another section from the same series, to show histological details. Note especially the branch joining the nerve of the pineal eye from the wall of the pineal sac. $\times 518$.

Fig. 65.—Part of another section from the same series, showing histological details in the wall of the pineal sac near its lower extremity. $\times 518$.

Fig. 66.—Part of another section from the same series, showing histological structure of the wall in a fold near the middle of the pineal sac. $\times 518$.

Fig. 67.—Part of another section from the same series, showing histological structure of the inner part of the wall of the pineal sac in a projecting fold near its lower extremity. Note especially the sense-cells and ganglion-cells. $\times 720$.

Fig. 68.—Part of another section from the same series, showing histological structure of the outer part of the wall near the middle of the pineal sac. Note the radial supporting fibres and ganglion-cells. $\times 720$.

Fig. 69.—Group of large brownish-yellow leucocytes (?) from the cavity of the pineal sac. (*Sphenodon V.*) $\times 1000$.

Fig. 70.—Two leucocytes from a lymph space in the connective tissue above the pineal sac. (*Sphenodon V.*) $\times 1000$.

Fig. 71.—Two leucocytes from blood-vessel in wall of pineal sac. (*Sphenodon V.*) $\times 1000$.

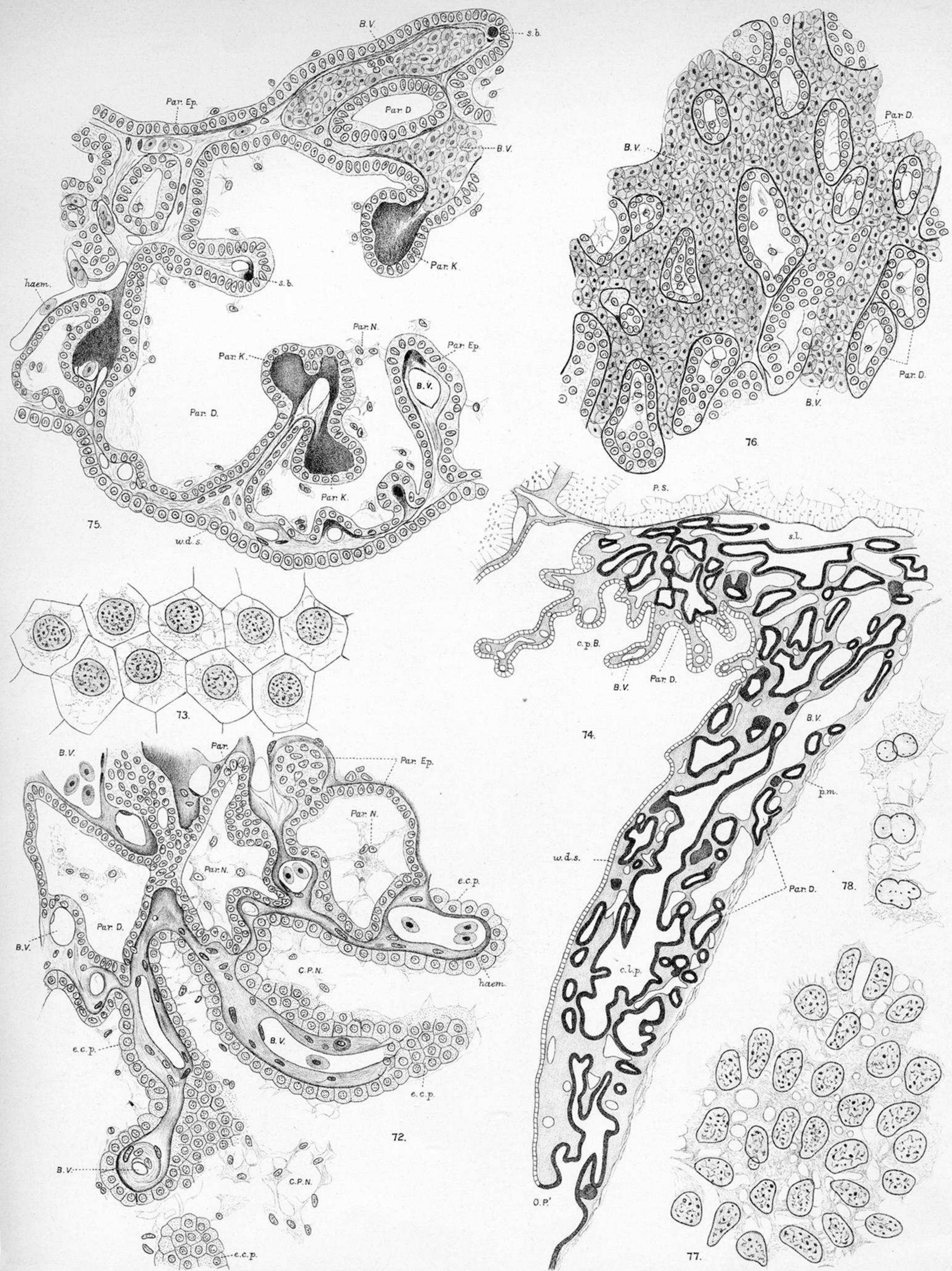


PLATE 31.

Fig. 72.—Histological structure of the choroid plexus of the dorsal sac and of the paraphysis, as seen in vertical longitudinal section of *Sphenodon* V. $\times 220$.

Fig. 73.—Epithelium covering the choroid plexus of the dorsal sac, surface view. (*Sphenodon* V.) $\times 1000$.

Fig. 74.—Vertical longitudinal section through the paraphysis and the choroid plexus of the dorsal sac. (*Sphenodon* V.) The lining epithelium of the paraphysis is represented by the thick black lines. Combined drawing from several sections. $\times 50$.

Fig. 75.—Histological structure of the paraphysis as shown in a transverse section of *Sphenodon* VI. Note especially the paraphysial knobs. $\times 220$.

Fig. 76.—Part of a tangential section through the lower limb of the paraphysis, showing the network of blood-vessels lying between the paraphysial diverticula. From a transverse section of *Sphenodon* VI. $\times 220$.

Fig. 77.—Epithelial lining of the paraphysis, from the same section as fig. 73. (*Sphenodon* V.) $\times 1000$.

Fig. 78.—Part of network of cells from the lumen of the paraphysis, showing amitotic division of the nuclei. (*Sphenodon* V.) $\times 1000$.