

Differences in root canal system configuration in human permanent teeth within different age groups

J. N. R. Martins¹ , R. Ordinola-Zapata² , D. Marques³, H. Francisco⁴ & J. Caramês⁴

¹Endodontics Department, Faculdade de Medicina Dentária, Instituto de Implantologia, Universidade de Lisboa, Lisboa, Portugal; ²Bender Division of Endodontics, Albert Einstein Medical Center, Philadelphia, PA, USA; ³Anatomy and Physiology Department; and ⁴Oral Surgery Department, Faculdade de Medicina Dentária, LIBPhys-FCT UID/FIS/04559/2013, Instituto de Implantologia, Universidade de Lisboa, Lisboa, Portugal

Abstract

Martins JNR, Ordinola-Zapata R, Marques D, Francisco H, Caramês J. Differences in root canal system configuration in human permanent teeth within different age groups. *International Endodontic Journal*.

Aim To analyse the differences in root canal system configuration in patients belonging to different age groups using cone beam computed tomography (CBCT) technology.

Methodology CBCT examinations from a pre-existing database were accessed. Patients were divided according to age groups: '≤20 years', '21–40 years', '41–60 years' and '≥61 years'. Each group included tooth data regarding their root canal system configurations according to the Vertucci classification and its supplementary configurations. Cohen kappa coefficient of agreement was calculated to evaluate observer reliability.

Results Overall 12 325 teeth from 670 patients were included. Most of the root groups had higher or equal prevalence of Vertucci type I configurations in the younger groups whilst presenting a greater tendency for multiple root canal system configurations in older patients, mainly Vertucci type II in both maxillary and mandibular second premolars and in the distal root of the mandibular first molar. The Cohen kappa coefficient of agreement was $89.4 \pm 1.8\%$.

Conclusion Clinicians should be aware that the root canal system configuration changes over a lifetime. In this study, the most affected teeth were the second premolars and the distal root of mandibular first molars.

Keywords: age, anatomy, cone beam computed tomography, morphology, root canal.

Received 11 July 2017; accepted 18 January 2018

Introduction

Changes in the pulp–dentinal complex occur over the course of a lifetime with physiological deposition of secondary dentine contributing to a reduction of the pulp chamber size and root canal diameter (Thomas *et al.* 1993, Gani *et al.* 2014). In addition,

stimuli such as carious lesions, deep restorations or periodontal disease may add to these changes due to deposition of reactionary dentine (Kuttler 1959). It is accepted that age-related morphological variations are a challenge to the clinician as they increase the difficulty of treatment (Johnstone & Parashos 2015).

Gani *et al.* (2014) addressed the changes in the mesial root of the mandibular first molar using clearing technique and concluded that in children (under 13 years), the root canal system tends to be single, large and triangular in shape with a single apical

Correspondence: Jorge N.R. Martins, Instituto de Implantologia of Lisbon, Av.Columbano Bordalo Pinheiro, 50, 1070-064 Lisboa, Portugal (Tel.: (+351) 96 52 64 0 63; e-mail: jnr_martins@yahoo.com.br)

foramen and a ribbon-shaped axial section. In young adults (20 to 39 years), the root canal system becomes more complex due to calcification and dentine deposition. In older adults (over 40 years), the root canals become narrower. Peiris *et al.* (2008) reached similar conclusions. Two other studies analysed clinically the middle mesial root canal in mandibular molars within ≤ 20 years, 20–40 years and ≥ 40 years age groups (Nosrat *et al.* 2015) and the second mesiobuccal root canal (MB2) in maxillary first molars within 5-year interval groups from 10 years to 85 years (Neaverth *et al.* 1987) during root canal treatment. They concluded that these root canals were more prone to be found in patients under 20 years and between the 20- and 40-year age groups, respectively.

Even though these studies are a valuable data source on the relationship between age and root canal anatomy, they have limitations, including small samples sizes (Huang *et al.* 2015, Naseri *et al.* 2016), limited groups of teeth (Neaverth *et al.* 1987, Nosrat *et al.* 2015) or a restricted methodology such as, identification of extra root canals during root canal treatment or using periapical radiographs (Thomas *et al.* 1993). These methods might not be able to represent the three-dimensional nature of the root canal anatomy clearly. The clearing technique has also been reported (Peiris *et al.* 2008, Gani *et al.* 2014), despite the fact that this method might be associated with irreversible changes to the original root canal system (Robertson *et al.* 1980, Lee *et al.* 2014). Micro-computed tomography (micro-CT) has been considered the gold standard to study *ex vivo* the root canal system morphology (Ordinola-Zapata *et al.* 2017); however, it is not designed for clinical purposes. As shown by previous reports, CBCT can be valuable when evaluating the morphology of the root canal system (Zhang *et al.* 2017).

Analysis of previous CBCT studies reveals that only a single group of teeth (Huang *et al.* 2015) or a single root (Lee *et al.* 2011) was reported on, or the study just addressed the prevalence of a specific extra canal in a specific root (Kim *et al.* 2012, Guo *et al.* 2014), or a specific root canal configuration such as the C-shaped mandibular molar (Kim *et al.* 2016, Martins *et al.* 2016). Even when combining all the available data, it is not possible to gain an overall understanding of the changes within the root canal system configuration over time because many groups of teeth have not been studied using CBCT technology. Another limitation of the published data

is the fact that most of the studies arise from different research groups using different population backgrounds (ethnic groups or geographic locations), which makes a global conclusion more difficult. Thus, the effect of age on root canal anatomy and number of root canals remains under-explored.

The purpose of this study was to analyse the root canal system configuration in patients belonging to various age groups using CBCT technology.

Material and Methods

Sample

A total of 670 CBCT examinations from Caucasian patients (243 males and 427 females) were included. The mean age was 51 years. All the examinations were performed for diagnostic purposes prior to oral surgical procedures and were kept in the Oral Radiology Department of a Lisbon Health Center. The CBCT scans were performed between May 2011 and September 2016 and were analysed retrospectively from January 2015 to September 2016 by a single evaluator after approval of the study by the centre's ethics commission (protocol number: II201403). All the CBCT examinations were performed using a 0.20 mm voxel size, 80 kV, 15 mA and an exposure time of 12 s (Planmeca Promax, Planmeca, Helsinki, Finland).

All the teeth observed in the scans were included with the exception of teeth with previous endodontic treatment, teeth with immature apices or root resorption, third molars and also images with artefacts. The scans were analysed using the Romexis visualization software (Planmeca). The evaluator had experience in the analysis of the root canal anatomy using CBCT technology and was allowed to change the visualization software settings to facilitate interpretation. All included teeth were analysed in three plans (coronal, sagittal and axial) to facilitate the interpretation of the root canal anatomy.

Data collection

The CBCT data were divided into four groups according to the age of the patient (' ≤ 20 years', '21–40 years', '41–60 years' and ' ≥ 61 years'). The following information was recorded:

1. Tooth number.
2. Root canal system configuration according to Vertucci (1984). In posterior teeth, each root was evaluated individually.

Statistical analysis

The collected data were analysed using SPSS software (IBM SPSS Statistics Version 22, Chicago, IL, USA), from which absolute counts and proportions for the analysed groups were extracted. The primary outcome was the root canal system configuration. The lower and upper limits of the 95% confidence interval for each proportion were calculated. To determine the intra-rater reliability (Cohen kappa test), the evaluator performed the analysis of the first 30 patients, which included 544 teeth (4.41% of the sample). This procedure was repeated 4 weeks later by the same operator who was blind to the first evaluation.

Results

The Cohen kappa coefficient of agreement between both Vertucci evaluations was 89.4% with an asymptotic standard error of $\pm 1.8\%$.

From the CBCT scans, a total of 12 325 teeth were analysed. Table 1 summarizes the distribution of the sample in each group of teeth according to each age group. The sample sizes from the younger group (≤ 20 years) were much smaller when compared to the older ones, which precluded a proper statistical comparison with the other groups.

Tables 2, 3, 4 and 5 summarize the proportion of each Vertucci classification type (and its supplementary configurations) according to each age group.

Table 1 Sample size distribution for each group of teeth in each age group

Tooth Groups	Age groups size (n)			
	≤ 20	21–40	41–60	≥ 61
Maxillary Central Incisor	5	225	407	270
Maxillary Lateral Incisor	9	256	408	264
Maxillary Canine	9	283	449	258
Maxillary 1st Premolar	10	256	298	150
Maxillary 2nd Premolar	10	217	270	121
Maxillary 1st Molar	10	214	239	104
Maxillary 2nd Molar	10	268	346	178
Mandibular Central Incisor	13	303	562	325
Mandibular Lateral Incisor	14	301	582	337
Mandibular Canine	14	303	581	346
Mandibular 1st Premolar	14	285	500	290
Mandibular 2nd Premolar	13	251	395	199
Mandibular 1st Molar	11	167	189	99
Mandibular 2nd Molar	9	244	309	125
Total (in groups)	151	3573	5535	3066
Total (all teeth)	12 325			

Amongst all the maxillary teeth, the second maxillary premolar had a greater variation in root canal system configuration. This tooth was associated with a progressive decrease in Vertucci type I configuration (47.5% [21–40 year], 36.3% [41–60 years], 33.9% [≥ 61 years]) which was balanced with a progressive increase in Vertucci type II (25.8% [21–40 years], 27.8% [41–60 years], 36.4% [≥ 61 years]).

The distal root of the mandibular first molar had a decrease in the Vertucci type I prevalence in the ' ≥ 61 years' group (59.6%) when compared to the younger groups (72.1% [21–40 years], 76.1% [41–60 years]) (Fig. 1). A progressive decrease in Vertucci type I configuration was also noted in the distal root of the mandibular second molar although the difference was not so substantial. The same was observed in the mandibular lateral incisor, canine and mainly on mandibular second premolars (98.8% [21–40 years], 96.2% [41–60 years], 92.5% [≥ 61 years]). The opposite situation was also noted on mandibular central incisors.

Discussion

Changes in the pulp chamber and root canal system have been documented for centuries. The first author to demonstrate it was John Hunter in his book 'The natural history of human teeth' (Hunter 1771). The author describes, in a simplistic manner, not only the dentine deposition process over the lifetime of the tooth but also possible reactions to tooth wear. Root canal anatomy is indeed susceptible to changes over the years due to physiological or pathological events. Natural physiological ageing tends to modify root canal system morphology due to the deposition of secondary dentine which starts to form once the tooth erupts and is in occlusion (Johnstone & Parashos 2015). Consequently, young patients tend to have large single canals and pulp chambers (Thomas *et al.* 1993, Gani *et al.* 2014) whilst older patients tend to have narrower root canals (Gani *et al.* 2014). Other pathological or iatrogenic factors can also modify the deposition of dentine, including occlusal trauma, periodontal disease, carious lesions or deep restorations (Lee *et al.* 2011).

Several CBCT studies investigated the type of root canal configurations amongst different age groups with a main focus on maxillary first molars (Zheng *et al.* 2010, Lee *et al.* 2011, Kim *et al.* 2012, Reis *et al.* 2013, Guo *et al.* 2014, Falcão *et al.* 2016, Naseri *et al.* 2016). In this study, an effort was made

Table 2 Root canal configurations on maxillary anterior teeth and premolars in each age group

Root canal configuration	Teeth Groups (Age groups)															
	Maxillary Central Incisor			Maxillary Lateral Incisor			Maxillary Canine			Maxillary First Premolar			Maxillary Second Premolar			
	≤20	21-40	41-60	≤20	21-40	41-60	≤20	21-40	41-60	≤20	21-40	41-60	≤20	21-40	41-60	≥61
Type I (1-1)	5	225	407	270	9	281	440	255	-	11	9	4	4	103	98	41
	100%	100%	100%	100%	100%	99.3%	98.0%	98.8%	-	4.3%	3.0%	2.6%	40%	47.5%	36.3%	33.9%
Type II (2-1)	-	-	-	-	-	2	6	3	-	53	40	29	2	56	75	44
	-	-	-	-	-	0.7%	1.3%	1.2%	-	20.7%	13.4%	19.3%	20%	25.8%	27.8%	36.3%
Type III (1-2-1)	-	-	-	-	-	-	2	-	-	-	2	-	-	4	8	1
	-	-	-	-	-	-	0.5%	-	-	-	0.7%	-	-	1.8%	3.0%	0.8%
Type IV (2-2)	-	-	-	-	-	-	1	-	9	162	216	100	1	31	56	18
	-	-	-	-	-	-	0.2%	-	90%	63.3%	72.5%	66.7%	10%	14.3%	20.7%	14.9%
Type V (1-2)	-	-	-	-	-	-	-	-	-	6	1	-	2	9	12	6
	-	-	-	-	-	-	-	-	-	2.3%	0.3%	-	20%	4.1%	4.4%	5.0%
Type VI (2-1-2)	-	-	-	-	-	-	-	-	-	13	14	6	-	9	20	11
	-	-	-	-	-	-	-	-	-	5.1%	4.7%	4.0%	-	4.1%	7.4%	9.1%
Type VII (1-2-1-2)	-	-	-	-	-	-	-	-	-	1	4	-	-	-	-	-
Type VIII (3-3)	-	-	-	-	-	-	-	-	-	0.4%	1.4%	-	-	-	-	-
Other (2-1-2-1)	-	-	-	-	-	-	-	-	-	6	20.7%	10.7%	-	31.4%	10.4%	-
Other (1-3)	-	-	-	-	-	-	-	-	-	6	-	-	-	-	-	-
	-	-	-	-	-	-	-	-	-	2.3%	-	-	-	-	-	-
Other (2-3)	-	-	-	-	-	-	-	-	1	-	3	6	-	1	-	-
	-	-	-	-	-	-	-	-	10%	-	1.0%	4.0%	-	0.5%	-	-
Other (2-1-3)	-	-	-	-	-	-	-	-	-	-	1	-	-	-	-	-
	-	-	-	-	-	-	-	-	-	-	0.3%	-	-	-	-	-
Other (2-3-2)	-	-	-	-	-	-	-	-	-	4	5	4	1	1	-	-
	-	-	-	-	-	-	-	-	-	1.6%	1.7%	2.7	10%	0.5%	-	-
Other (2-3-2-1)	-	-	-	-	-	-	-	-	-	-	1	-	-	-	-	-
	-	-	-	-	-	-	-	-	-	-	0.3%	-	-	-	-	-

Table 3 Root canal configurations on maxillary first and second molars in each age group

Root canal configuration	Teeth Groups (Age groups)												
	Maxillary First Molar ^a						Maxillary Second Molar ^a						
	Mesio buccal		Distobuccal		Palatal		Mesio buccal		Distobuccal		Palatal		
	≤20	21-40	41-60	≥61	≤20	21-40	41-60	≥61	≤20	21-40	41-60	≥61	
Type I (1-1)	2	56	59	31	10	188	209	99	99	6	120	138	67
	20.0%	29.2%	27.5%	31.0%	100%	97.9%	97.6%	99.0%	98.6%	66.7%	61.2%	54.6%	51.1%
Type II (2-1)	4	82	97	47	-	3	4	-	2	2	39	77	39
	40.0%	42.7%	45.3%	47.0%	-	1.6%	1.9%	-	0.9%	22.2%	19.9%	30.4%	29.8%
Type III (1-2-1)	-	1	4	-	-	-	1	1	1	-	1	3	1
	-	0.5%	1.9%	-	-	-	0.5%	1.0%	0.5%	-	0.5%	1.2%	0.8%
Type IV (2-2)	2	42	28	11	-	-	-	-	-	-	23	11	11
	20.0%	21.9%	13.1%	11.0%	-	-	-	-	-	-	11.7%	4.3%	8.4%
Type V (1-1-2)	-	1	7	2	-	1	-	-	-	1	5	11	5
	-	0.5%	3.3%	2.0%	-	0.5%	-	-	-	11.1%	2.6%	4.3%	3.8%
Type VI (2-1-2)	2	7	15	7	-	-	-	1	-	-	7	12	6
	20.0%	3.6%	7.0%	7.0%	-	-	-	1.0%	-	-	3.6%	4.8%	4.6%
Type VII (1-2-1-2)	-	-	-	1	-	-	-	-	-	-	1	-	-
	-	-	-	1.0%	-	-	-	-	-	-	0.5%	-	-
Type VIII (3-3)	-	-	-	-	-	-	-	-	-	-	-	-	-
Other (2-1-2-1)	-	3	3	-	-	-	-	-	-	-	-	1	1
	-	1.6%	1.4%	-	-	-	-	-	-	-	-	0.4%	0.8%
Other (3-1-2)	-	-	-	1	-	-	-	-	-	-	-	-	-
	-	-	-	1.0%	-	-	-	-	-	-	-	-	-
Other (3-2-1)	-	-	-	-	-	-	-	-	-	-	-	-	1
	-	-	-	-	-	-	-	-	-	-	-	-	0.8%

^aOnly maxillary molars with three independent roots.

Table 4 Root canal configurations on mandibular anterior teeth and premolars in each age group

Root canal configuration	Teeth Groups (Age groups)															
	Mandibular Central Incisor			Mandibular Lateral Incisor			Mandibular Canine			Mandibular First Premolar			Mandibular Second Premolar			
	≤20	21-40	41-60	≥61	≤20	21-40	41-60	≥61	≤20	21-40	41-60	≥61	≤20	21-40	41-60	≥61
Type I (1-1)	6	209	413	245	10	212	408	235	12	279	309	9	232	377	228	184
	46.1%	69.0%	73.5%	75.4%	71.4%	70.4%	70.1%	69.7%	85.7%	92.1%	89.3%	64.3%	81.4%	75.4%	78.6%	92.5%
Type II (2-1)	2	7	13	7	2	14	34	25	-	7	19	-	5	12	10	2
	15.4%	2.3%	2.3%	2.2%	14.3%	4.7%	5.9%	7.4%	-	2.3%	3.3%	4.4%	1.7%	2.4%	3.5%	1.0%
Type III (1-2-1)	5	84	131	69	2	74	134	75	-	7	20	-	9	31	18	4
	38.5%	27.8%	23.3%	21.2%	14.3%	24.6%	23.0%	22.3%	-	2.3%	3.4%	1.4%	3.2%	6.2%	6.2%	2.0%
Type IV (2-2)	-	1	-	-	-	-	-	-	2	4	6	5	2	7	7	3
	-	0.3%	-	-	-	-	-	-	14.3%	1.3%	1.0%	1.4%	0.7%	1.4%	2.4%	1.5%
Type V (1-2)	-	1	3	-	-	1	2	-	-	6	13	12	5	68	26	6
	-	0.3%	0.5%	-	-	0.3%	0.3%	-	-	2.0%	2.2%	3.5%	35.7%	11.9%	13.6%	3.0%
Type VI (2-1-2)	-	-	-	-	-	-	-	-	-	-	-	-	-	-	-	-
Type VII (1-2-1-2)	-	-	2	4	-	-	1	2	-	-	-	-	-	1	1	-
	-	-	0.4%	1.2%	-	-	0.2%	0.6%	-	-	-	-	-	0.2%	0.3%	-
Type VIII (3-3)	-	-	-	-	-	-	-	-	-	-	-	-	-	-	-	-
Other (1-2-1-2-1)	-	1	-	-	-	-	-	-	-	-	-	-	-	-	-	-
	-	0.3%	-	-	-	-	-	-	-	-	-	-	-	-	-	-
Other (2-1-2-1)	-	-	-	-	-	-	2	-	-	-	1	-	-	1	-	-
	-	-	-	-	-	-	0.3%	-	-	-	0.2%	-	-	0.2%	-	-
Other (1-3)	-	-	-	-	-	-	-	-	-	-	-	-	-	3	-	-
	-	-	-	-	-	-	-	-	-	-	-	-	-	0.6%	-	-
Other (1-3-1)	-	-	-	-	-	-	1	-	-	-	-	-	2	-	1	-
	-	-	-	-	-	-	0.2%	-	-	-	-	-	0.7%	-	0.2%	-
Other (1-3-2)	-	-	-	-	-	-	-	-	-	-	-	-	1	-	-	-
	-	-	-	-	-	-	-	-	-	-	-	-	0.4%	-	-	-

Table 5 Root canal configurations on mandibular first and second molars in each age group

Root canal configuration	Teeth Groups (Age groups)															
	Mandibular First Molar ^a						Mandibular Second Molar ^a									
	Mesial			Distal			Mesial			Distal						
	≤20	21-40	41-60	≥61	≤20	21-40	41-60	≥61	≤20	21-40	41-60	≥61				
Type I (1-1)	-	1	3	1	7	119	143	59	1	16	21	9	9	195	248	95
		0.6%	1.6%	1.0%	63.6%	72.1%	76.0%	59.6%	11.1%	7.7%	7.8%	8.6%	100%	93.7%	92.6%	91.3%
Type II (2-1)	7	74	95	41	1	15	16	23	5	126	173	66	-	2	2	1
	63.6%	44.9%	50.5%	41.4%	9.1%	9.1%	8.5%	23.2%	55.6%	60.5%	64.5%	63.4%	-	1.0%	0.7%	1.0%
Type III (1-2-1)	-	-	-	-	1	16	19	8	-	8	14	8	-	5	11	7
					9.1%	9.7%	10.1%	8.1%	-	3.8%	5.2%	7.7%	-	2.4%	4.1%	6.7%
Type IV (2-2)	3	73	72	46	-	3	5	5	3	49	46	16	-	1	2	-
	27.3%	44.2%	38.3%	46.6%	-	1.8%	2.7%	5.1%	33.3%	23.6%	17.2%	15.4%	-	0.5%	0.7%	-
Type V (1-2)	-	-	-	-	2	9	2	1	-	1	1	1	-	5	5	1
					18.2%	5.5%	1.1%	1.0%	-	0.5%	0.4%	1.0%	-	2.4%	1.9%	1.0%
Type VI (2-1-2)	-	8	7	3	-	1	2	2	-	4	6	-	-	-	-	-
		4.9%	3.7%	3.0%	-	0.6%	1.1%	2.0%	-	1.9%	2.2%	-	-	-	-	-
Type VII (1-2-1-2)	-	-	-	-	-	1	-	-	-	-	-	-	-	-	-	-
						0.6%	-	-	-	-	-	-	-	-	-	-
Type VIII (3-3)	-	-	-	-	-	-	-	-	-	-	-	-	-	-	-	-
Other (1-2-1-2-1)	-	-	-	-	-	-	-	1	-	-	-	-	-	-	-	-
								1.0%								
Other (2-1-2-1)	-	1	2	1	-	1	1	-	-	-	1	1	-	-	-	-
		0.6%	1.1%	1.0%	-	0.6%	0.5%	-	-	-	0.4%	1.0%	-	-	-	-
Other (3-2)	-	-	5	4	-	-	-	-	-	1	1	-	-	-	-	-
			2.7%	4.0%	-	-	-	-	-	0.5%	0.4%	-	-	-	-	-
Other (2-3-2)	-	-	1	-	-	-	-	-	-	-	-	-	-	-	-	-
			0.5%	-	-	-	-	-	-	-	-	-	-	-	-	-
Other (3-2-1)	1	8	3	3	-	-	-	-	-	2	4	2	-	-	-	-
	9.1%	4.8%	1.6%	3.0%	-	-	-	-	-	1.0%	1.5%	1.9%	-	-	-	-
Other (2-3-2-1)	-	-	-	-	-	-	-	-	-	1	1	-	-	-	-	-
										0.5%	0.4%	-	-	-	-	-
Other (3-2-3-2-1)	-	-	-	-	-	-	-	-	-	-	-	11.0%	-	-	-	-

^aOnly mandibular molars with two independent roots.

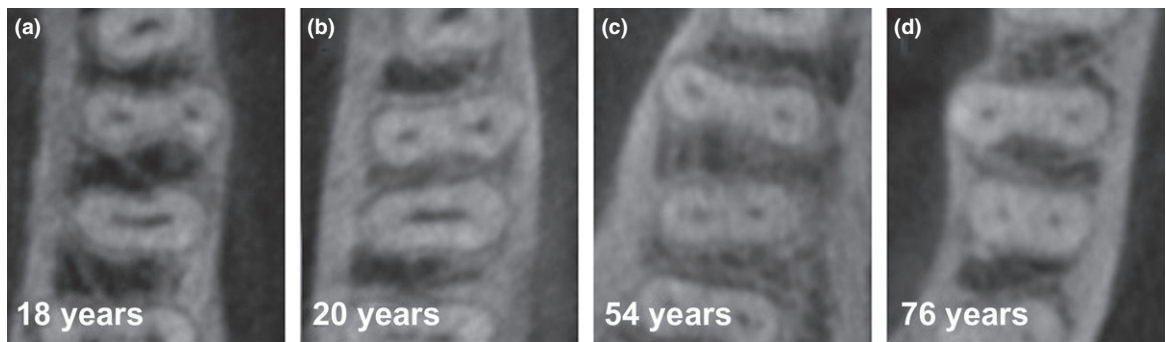


Figure 1 Examples of number of root canal configurations found in mandibular first molars according to age (different patients). (a and b) single long oval canal on distal root, compatible with isthmus type V, on younger patients; (c and d) two root canals on distal root on older patients. Note the differences on the distal roots between younger and older patients regarding the axial canal configuration and canal diameter size.

to include all groups of teeth, excluding third molars, which required an extremely large global sample. Most of the previous studies (Zheng *et al.* 2010, Lee *et al.* 2011, Kim *et al.* 2012, 2016, Guo *et al.* 2014) presented 10-year intervals. In this study, it was decided to include 20-year intervals to assure larger sample sizes in each group.

The results of the present study revealed a global tendency of a greater Vertucci type I (1-1) prevalence in younger patients. The maxillary second premolar had the greatest differences between groups. In this tooth group, a decrease of 13.6% was noted in the presence of Vertucci type I configuration when moving from '21–40 yrs' to '≥61 yrs' group. It was not possible to confirm this result with previous studies since no information regarding this tooth group is available.

Overall, most of the samples in the anterior tooth groups did not vary significantly over the years. It is important to note that the presence of two root canals in the mandibular canine and the mandibular incisors was not an uncommon finding. The overall percentage of type I anatomy in mandibular incisors, around 71% found in the present study, is similar to the overall results obtained by a previous laboratory study (Vertucci 1984). A lower overall prevalence of single canals has also been reported by Sert & Bayirli (2004) and Leoni *et al.* (2014). Similar morphologies were detected in these teeth in the different age groups. Only two *in vivo* CBCT studies have analysed anterior mandibular teeth (central and lateral incisors and canine) anatomy at different age intervals (Kayaoglu *et al.* 2015, Zhengyan *et al.* 2016). However, they did analyse the three anterior tooth groups

together as a major group and not individually. Both studies described a lower prevalence of multiple root canals on the older groups when compared to the younger ones. The current study does not support those results since multiple root canals, when the three tooth groups were combined, remained around 22% at the different age intervals (22.82% [21–40 years], 22.10% [41–60 years], 21.73% [≥61 years]).

The overall prevalence of Vertucci type I configurations in both maxillary premolars was lower than previous *in vivo* CBCT studies (Abella *et al.* 2015, Bulut *et al.* 2015), and other similar laboratory studies (Vertucci 1984, Sert & Bayirli 2004). Both teeth had a lower prevalence of one root canal in the younger groups, with the difference in the maxillary second premolar being the greatest.

This study reveals that age does not affect the prevalence of the MB2 canal in the mesiobuccal root of the first maxillary molar; the prevalence found was in the range of 69.0% (≥61 years) and 72.4% (41–60 years) depending on the age group. Previous studies also provide data on the presence or absence of the MB2 in different age groups. Three of those studies (Zheng *et al.* 2010, Lee *et al.* 2011, Naseri *et al.* 2016) reported that over 60 years, the prevalence of MB2 was lower when compared to younger groups, which corroborates the present findings. Two other studies from Brazil (Reis *et al.* 2013, Falcão *et al.* 2016) also confirmed the previous findings. On the other hand, two studies found a higher prevalence of the MB2 in patients over 50 years in Korea (Kim *et al.* 2012) or over 60 years in the USA (Guo *et al.* 2014) (Table 6). With regard to the maxillary second

Table 6 CBCT studies reporting the prevalence of MB2 root canal in the maxillary first molar according to age groups

Study	Country	Technique	Method	Sample	<20 years	20–30 years	30–40 years	40–50 years	50–60 years	>60 years
Falcão <i>et al.</i> (2016)	Brazil	CBCT	<i>In vivo</i>	80		76.9%	53.9%		51.9%	
Guo <i>et al.</i> (2014) ^a	USA	CBCT	<i>In vivo</i>	634	67.6%	72.4%	60.0%	74.6%	60.8%	80.0%
Jing <i>et al.</i> (2014) ^a	China	CBCT	<i>In vivo</i>	630	26.9%	37.3%	30.1%	36.2%		22.1%
Kim <i>et al.</i> (2012)	Korea	CBCT	<i>In vivo</i>	814	58.4%	65.6%	68.1%	51.8%		69.4%
Lee <i>et al.</i> (2011) ^a	Korea	CBCT	<i>In vivo</i>	458	81.5%	72.5%	85.5%	70.7%	59.2%	50.0%
Reis <i>et al.</i> (2013) ^b	Brazil	CBCT	<i>In vivo</i>	158	n/a	90.7%	92.1%	82.6%		81.9%
Zheng <i>et al.</i> (2010) ^a	China	CBCT	<i>In vivo</i>	624	50.2%	68.3%	51.2%	42.2%	44.0%	40.0%
Present Study	Portugal	CBCT	<i>In vivo</i>	567	80.0%		70.8%		72.4%	69.0%

n/a, Not available.

^aStudy reporting a significant difference in the age groups distribution.

^bStudy combines the results from maxillary first and second molars.

molar, the results showed a MB2 prevalence around 43%. It is important to note that the prevalence of the MB2 canal in maxillary molars is in agreement with the findings of several laboratory and *in vivo* studies (Buhrley *et al.* 2002, Cleghorn *et al.* 2006, Lee *et al.* 2011, Guo *et al.* 2014).

Mandibular premolars, particularly the first premolar, have been associated with several morphologic variations, including C-shaped and multiple canals. In this study, the mandibular first and second premolars had multiple root canal systems in 18.6% (21–40 years) and 24.6% (41–60 years), and 1.2% (21–40 years) and 7.5% (≥ 61 years) of the cases, respectively.

In mandibular molars, the current study has identified an apparent increase in the number of root canals in the distal root of mandibular first molar in the over 60-year age group. In the case of the distal root of the mandibular first molar, there was an increase in Vertucci type II (2–1) from 8.5% in the 41–60 years group to 23.2% in the group over 60 years, which suggests a deposition mainly in the coronal portion of the root canal system. A previous study (Thomas *et al.* 1993) observed a two-directional calcification pattern. They noticed that canals with a large cross section may be divided into two narrow root canals in the extremities of the original large canal when the dentine deposition starts to form in the middle, creating an isthmus. In the following stages, there is a closure of the isthmus making the two canals independent. This pattern may explain the differences found in the Vertucci type II (2–1) configurations, and increasing prevalence in multiple root canals in the mandibular premolars and especially in the distal root of the mandibular first molar, which traditionally has oval or large cross-section root canals (Filpo-Perez *et al.* 2015).

One limitation of the CBCT time-interval root canal system evaluation in assessing age changes is that they compare the results from different individuals at a certain point in time not taking into consideration the stimuli that each tooth has taken over its lifespan which might have resulted in a more rapid increase in reactionary dentine deposition. To assess the real effect of time on the root canal system, there would be a need to evaluate the same individuals over time with regular analysis and recording the stimulus each one has had. However, that methodology would be technically very demanding and ethically questionable because it would require an unnecessary exposure to radiation for the patient. To avoid this exposure, the time-interval analysis of pre-existing CBCT examinations appears indeed to be the most feasible method. The CBCT examination analysis has the advantage of being extremely close to what it is possible to find clinically. The 0.20 mm voxel size used in the present study has also been used previously in root canal system investigations (Reis *et al.* 2013, Naseri *et al.* 2016). Although it would require a higher radiation dose, it would be interesting to understand if with smaller voxel sizes the results could be different due to the higher resolution of the examinations.

Other limitations of the study were the 20-year time intervals which makes it difficult to make a comparison with the few available studies which usually present 10-year time intervals. However, this decision was made to avoid small sample sizes making the interpretation of the results difficult. The small sample size in the under 20-year group might be explained by youth. CBCT radiation exposures tend to be avoided in young patients, and the apices might not be completely mature. To compensate the division of 14 groups of teeth amongst different age intervals, a

large global sample had to be collected to allow for an acceptable interpretation of the entire dentition.

Conclusions

There was a tendency for a greater prevalence of single root canal configuration (Vertucci type I) in younger patients when compared to older ones. A larger increase in the number of root canals was found mainly in the maxillary and mandibular second premolars and distal root of mandibular first molars, in the older groups. Multiple root canal configurations (mainly Vertucci type II) were more frequent in older groups.

Conflict of interest

The authors have stated explicitly that there are no conflict of interests in connection with this article.

References

- Abella F, Teixidó L, Patel S, Sosa F, Duran-Sindreu F, Roig M (2015) Cone-beam computed tomography analysis of the root canal morphology of maxillary first and second premolars in Spanish population. *Journal of Endodontics* **41**, 1241–7.
- Buhrley L, Barrows M, Begole E, Wenckus C (2002) Effect of magnification on locating the MB2 canal in maxillary molars. *Journal of Endodontics* **28**, 324–7.
- Bulut D, Kose E, Ozcan G, Sekerci A, Canger E, Sisman Y (2015) Evaluation of root morphology and root canal configuration of premolars in the Turkish individuals using cone beam computed tomography. *European Journal of Dentistry* **9**, 551–7.
- Cleghorn B, Christie W, Dong C (2006) Root and root canal morphology of the human permanent maxillary first molar: a literature review. *Journal of Endodontics* **32**, 813–21.
- Falcão C, Albuquerque V, Amorim N et al. (2016) Frequency of the mesiopalatal canal in upper first permanent molars viewed through computed tomography. *Acta Odontologica Latinoamericana* **29**, 54–9.
- Filpo-Perez C, Bramante C, Villas-Boas M, Húngaro Duarte M, Versiani M, Ordinola-Zapata R (2015) Micro-computed tomographic analysis of the root canal morphology of the distal root of mandibular first molar. *Journal of Endodontics* **41**, 231–6.
- Gani O, Boiero C, Correa C et al. (2014) Morphological changes related to age in mesial root canals of permanent mandibular first molars. *Acta Odontológica Latinoamericana* **27**, 105–9.
- Guo J, Vahidnia A, Sedghizadeh P, Enciso R (2014) Evaluation of root and canal morphology of maxillary permanent first molar in North America population by cone beam computed tomography. *Journal of Endodontics* **40**, 635–9.
- Huang Y, Wu J, Sheu R et al. (2015) Evaluation of the root and root canal system of mandible first premolars in northern Taiwanese patients using cone-beam computed tomography. *Journal of the Formosan Medical Association* **114**, 1129–34.
- Hunter J (1771) *The natural history of the human teeth. Explaining their structure, use, formation, growth, and diseases*. London: J. Johnson.
- Jing Y, Ye X, Liu D, Zhang Z, Ma X (2014) Cone-beam computed tomography was used for study of root and canal morphology of first and second molars. *Beijing Da Xue Xue Bao. Yi xue ban* **46**, 958–62.
- Johnstone M, Parashos P (2015) Endodontics and the ageing patient. *Australian Dental Journal* **60**, 20–7.
- Kayaoglu G, Pekker I, Gumusok M, Sarikir C, Kayadugun A, Uçok O (2015) Root and canal symmetry in the mandibular anterior teeth of patients attending a dental clinic: CBCT study. *Brazilian Oral Research* **29**, pii:S1806-83242015000100283
- Kim Y, Lee S, Woo J (2012) Morphology of maxillary first and second molars analyzed by cone-beam computed tomography in a Korean population: variations in the number of roots and canals and the incidence of fusion. *Journal of Endodontics* **38**, 1063–8.
- Kim S, Kim B, Kim Y (2016) Mandibular second molar root canal morphology and variants in a Korean subpopulation. *International Endodontic Journal* **49**, 136–44.
- Kuttler Y (1959) Classification of dentine into primary, secondary, and tertiary. *Oral Surgery, Oral Medicine, and Oral Pathology* **12**, 996–9.
- Lee JH, Kim KD, Lee JK, et al. (2011) Mesio Buccal root canal anatomy of Korean maxillary first and second molars by cone-beam computed tomography. *Oral Surgery Oral Medicine Oral Pathology Oral Radiology Endodontics* **111**, 785–91.
- Lee K, Kim Y, Perinpanayagam H et al. (2014) Comparison of alternative image reformatting techniques in micro-computed tomography and tooth clearing for detailed canal morphology. *Journal of Endodontics* **40**, 417–22.
- Leoni G, Versiani M, Pécora J, Sousa-Neto M (2014) Micro-computed tomography analysis of the root canal morphology of mandibular incisors. *Journal of Endodontics* **40**, 710–6.
- Martins JNR, Mata A, Marques D, Caramês J (2016) Prevalence of C-shaped mandibular molars in the Portuguese population evaluated by cone-beam computed tomography. *European Journal of Dentistry* **10**, 529–35.
- Naseri M, Safi Y, Baghban A, Khayat A, Eftekhari L (2016) Survey of anatomy and root canal morphology of maxillary first molars regarding age and gender in an Iranian population using Cone-Beam computed tomography. *Iranian Endodontic Journal* **11**, 298–303.

- Neaverth E, Kotler L, Kattenbach R (1987) Clinical investigation (*In vivo*) of endodontically treated maxillary first molars. *Journal of Endodontics* **13**, 506–12.
- Nosrat A, Deschenes R, Tordik P, Hicks M, Fouad A (2015) Middle mesial canals in mandibular molars: incidence and related factors. *Journal of Endodontics* **41**, 28–32.
- Ordinola-Zapata R, Bramante C, Versiani M *et al.* (2017) Comparative accuracy of the clearing technique, CBCT and micro-CT method in studying the mesial root canal configuration of mandibular first molars. *International Endodontic Journal* **50**, 90–6.
- Peiris H, Pitakotuwage T, Takahashi M, Sasaki K, Kanazawa E (2008) Root canal morphology of mandibular permanent molars at different ages. *International Endodontic Journal* **41**, 828–35.
- Reis A, Soares R, Barletta F, Fontanella V, Mahl C (2013) Second canal in mesiobuccal root of maxillary molars is correlated with root third and patient age: a cone-beam computed tomographic study. *Journal of Endodontics* **39**, 588–92.
- Robertson D, Leeb J, McKee M, Brewer E (1980) A clearing technique for the study of root canal systems. *Journal of Endodontics* **1**, 421–4.
- Sert S, Bayirli G (2004) Evaluation of the root canal configuration of the mandibular and maxillary permanent teeth by gender in the Turkish population. *Journal of Endodontics* **30**, 391–8.
- Thomas R, Moule A, Bryant R (1993) Root canal morphology of maxillary permanent first molar teeth at various ages. *International Endodontic Journal* **26**, 257–67.
- Vertucci F (1984) Root canal anatomy of the human permanent teeth. *Oral Surgery, Oral Medicine, and Oral Pathology* **58**, 589–99.
- Zhang D, Chen J, Li M *et al.* (2017) The root canal morphology in mandibular first premolars: a comparative evaluation of cone-beam computed tomography and micro-computed tomography. *Clinical Oral Investigations* **21**, 1007–12.
- Zheng Q, Wang Y, Zhou X, Wang Q, Zheng G, Huang D (2010) A cone-beam computed tomography study of maxillary first permanent molar root and canal morphology in a Chinese population. *Journal of Endodontics* **36**, 1480–4.
- Zhengyan Y, Keke L, Fei W, Yueheng L, Zhi Z (2016) Cone-beam computed tomography study of root and canal morphology of mandibular permanent anterior teeth in a Chongqing population. *Therapeutics and Clinical Risk Management* **12**, 19–25.