

New Hierarchical Approach for Microaneurysms Detection with Matched Filter and Machine Learning

Jiayi Wu¹, Jingmin Xin¹, Lai Hong², Jane You³ and Nanning Zheng¹

Abstract—Microaneurysms are regarded as the first signs of diabetic retinopathy (DR), but the microaneurysms are not clear in the color retinal images, and many researches were studied to detect and locate these lesions. In this paper, a new hierarchical computing-aided diagnosis approach is proposed for the microaneurysms detection by using the multi-scale and multi-orientation sum of matched filter (MMMF) and machine learning, where 37 dimensional features are extracted from each candidate. Furthermore, several classifiers such as the k-nearest neighbor (kNN), local linear discrimination analysis (LLDA) and support vector machine (SVM) are modified to distinguish the true microaneurysms from the false ones, which is a typical unbalanced classification problem. The effectiveness of the proposed method is verified through the training set of a publicly available database, and the experiment results show that the proposed method has better detection performance including the receiver operating characteristic (ROC) curve and the free-response receiver operating characteristic (FROC) curve. Moreover, the proposed method with 37 dimensional features outperforms that with other features and has a sensitivity from 1/8 to 8 with the average of all seven points being 0.286 tested on the same database.

I. INTRODUCTION

According to a study of the American Diabetes Association (ADA), the diabetic retinopathy (DR) affected more than 4.4 million Americans of age 37 and older during the period of 2005-2008 and with almost 0.7 million Americans having the DR could lead to severe vision loss. Early detection and treatment of the DR can probably decrease the risk of severe vision loss by over 90%. Hence efficient and cost-effective DR screening systems has attained considerable attentions [1], where the color retinal fundus camera images are used to diagnose the DR and to obtain some information about retinal, ophthalmic, and even systemic disease such as diabetics and hypertension.

In general, the DR may cause several abnormalities in the retina such as bright lesion (hard exudates and cotton wool spots) and red lesion (hemorrhages and microaneurysms). In these lesions, the microaneurysms are considered to be the earliest clinically detectable lesion of the DR and are indirect evidence of ischaemia, since each microaneurysm can be thought of as representing the occlusion of at least one capillary as shown in Fig. 1. However, since the microaneurysms

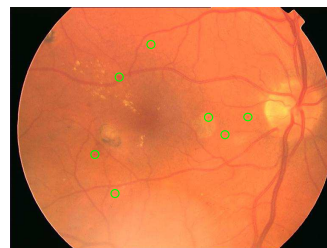

Fig. 1. The example of microaneurysms

in the color retinal images are not clear, the accuracy of microaneurysms detection is affected by the background noises, and the microaneurysms can be “merged” into small vessels during filtering operation, because they are often surrounded by small vessels. Furthermore, the greyscale distribution along vessel orientation is often discontinuous and hence the small vessels are easily misclassified as microaneurysms. Several detection methods were presented to tackle this challenge (e.g., [2], [3]). A hybrid scheme was suggested to use both the top-hat based method and a supervised pixel classification based method to detect the microaneurysm candidates in color fundus photographs in [2], while a multi-scale Bayesian correlation filtering based method was proposed to detect the microaneurysm in [3].

In this paper, by using the multi-scale and multi-orientation sum of matched filter (MMMF) and machine learning, a new hierarchical is proposed to detect the retinal microaneurysm candidates, where the affection of the small vessels is suppressed, while the microaneurysms is enhanced. for microaneurysms detection. Usually in the microaneurysms detection, more microaneurysms as possible should be detected, although this does mean that many spurious objects bearing a similarity to the microaneurysms are also segmented. In the proposed method, 37 dimensional features are extracted from each candidate, and several classifiers such as the k-nearest neighbor (kNN) [4], local linear discrimination analysis (LLDA) [5] and support vector machine (SVM) [6] are modified to distinguish the true microaneurysms from the false ones and to combat the unbalanced classification problem. The receiver operating characteristic (ROC) curve and the free-response receiver operating characteristic (FROC) curve are produced on per lesion base for verifying the detection performance. By testing the proposed method through the publicly available database ROC [7], which provides 50 retinal images with manually labeled ground truth, it is shown that the SVM classifier with probabilistic outputs has better detection performance for microaneurysms classification. Moreover, the

*This work was supported by the Programme of Introducing Talents of Discipline to Universities under Grant B13043 and the knowledge innovation program of Shenzhen (JCYJ20130401095947230)

¹ J. Wu, J. Xin and N. Zheng are with the Institute of Artificial Intelligence and Robotics, Xi'an Jiaotong University, Xi'an 710049, China

² L. Hong is with the School of Software Engineering, Shenzhen Institute of Information Technology, Shenzhen, Guangdong, China

³ J. You is with the Department of Computing, The Hong Kong Polytechnic University, KLN, Hong Kong, China

proposed method with 37 dimensional features outperforms that with other features and has a sensitivity from 1/8 to 8 with the average of all seven points being 0.286 tested on the same database, which is larger than that of the method [3] being 0.201.

II. NEW HIERARCHICAL APPROACH FOR MICROANEURYSMS DETECTION

The approach herein presented for microaneurysm detection consists of three steps: 1) detection of microaneurysm candidates, 2) features extraction, and 3) classification of microaneurysm candidates. Fig. 2 shows the architecture of the proposed method. This section describes our method to detect retinal microaneurysms in details.

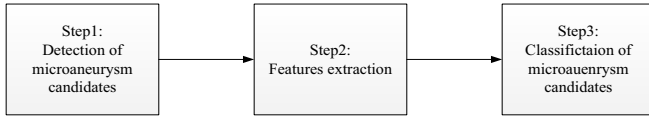

Fig. 2. The architecture of the proposed approach

A. Detection of Microaneurysm Candidates

The task for detecting the microaneurysm candidates is to identify all possible microaneurysm candidates in a retinal image. Firstly, we apply a median filter with a 3×3 pixel kernel and the morphological opening images in the image to denoise the color retinal (e.g., Fig. 3(a)) that I_{green} represents the green channel of the original retinal image, and a typical result of the operation I_{bg} is shown in Fig. 3(b). Then the vessels are suppressed by using the morphological closing in the image I_{bg} and consequently the resulted image I_{lesion} contains mainly the non-elongated structures such as red lesion. Because the shape of a microaneurysm is a circle, its cross-sections are the same at all orientations, while the cross-sections of the vessels are different at different orientations. In order to enhance the center response of a microaneurysm and to suppress the vessel response, a method based the multi-orientation sum of matched filter (MSMF) was proposed in [8], where the matched filter is rotated an anisotropic Gaussian function to different orientations, and the MSMF defined as

$$R(x, y) = \sum_{\phi} I(x, y) * m^{\phi}(\bar{x}, \bar{y}) \quad (1)$$

for $\phi = 0, \pi/12, \dots, 11\pi/12$, where $I(x, y)$ is the processed image, and

$$m^{\phi}(\bar{x}, \bar{y}) = m(x, y) \quad (2)$$

$$\bar{x} = x \cos \phi + y \sin \phi \quad (3)$$

$$\bar{y} = y \cos \phi - x \sin \phi \quad (4)$$

$$m(x, y) = \frac{x^2 - \sigma^2}{\sqrt{2\pi}\sigma^5} \exp\left(\frac{-x^2}{2\sigma^2}\right) \quad (5)$$

where $|x| \leq \sigma$, $|y| \leq L/2$, σ is the standard deviation of the Gaussian function, L is the length of the neighborhood along y-axis to smooth noise. For the MSMF in one-dimensional

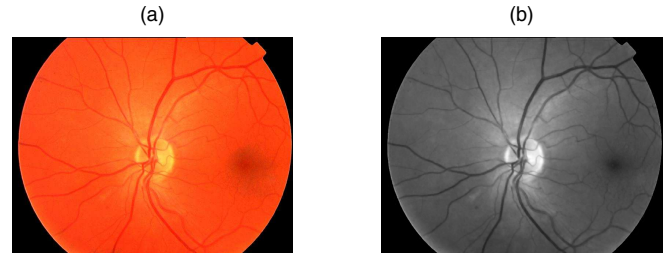

Fig. 3. (a) The color fundus photographs with microaneurysms and (b) the preprocessing result of (a)




Fig. 4. (a) The convolution result with the proposed MMMF and (b) the segmenting result of (a) with a threshold of 0.37.

(1-D) case, the center response of the cross-sections of a microaneurysm or a vessel can be derived by

$$R(0) = m(x) * v(x)|_{x=0} = -24 \times h \times g'_{\sigma}(w) \quad (6)$$

where $v(x)$ represents the cross-sections of a microaneurysm or a vessel, w and $-h$ are the width and pixel value of $v(x)$ respectively, and $g'_{\sigma}(w)$ is the first derivative of Gaussian function. The convolution results are the maximum, when the value of w and σ are same.

Since microaneurysms vary in size, different sigma values for the MSMF are required to enhance the microaneurysms. Here for matching various microaneurysms dimensions, we propose an Multi-scale and Multi-orientation Sum of Matched Filter (MMMMF) by including the selection of multiple scales to process the image I_{lesion} . For example, by choosing the anisotropic Gaussian function defined in (1) to represent the microaneurysms of different sizes being $\sigma = 1.1, 1.2, 1.3, 1.4$ and 1.5 , the maximum values from each of the five responses are combined to form a final response I_{match} as shown in Fig. 4(a). Obviously the center response of a microaneurysm is enhanced and the vessel response is suppressed. In order to determine the number of microaneurysms candidates, a threshold is applied to produce a binary image I_{bin} . As shown in Fig. 4(b), the true microaneurysms can be reinstated well, when the threshold is set to $I_{bin} = 0.37$.

Then the candidates on the blood vessels should be removed in the filtered image I_{bin} . The region growing algorithm [2] is used to grow back the original pathologies, when the darkest pixel under each of the binary objects is used as the starting point. The grown objects together form the final candidate object set are shown in Fig. 5(b). As the threshold level to produce image I_{bin} is deliberately set to ensure that as many microaneurysms as possible would

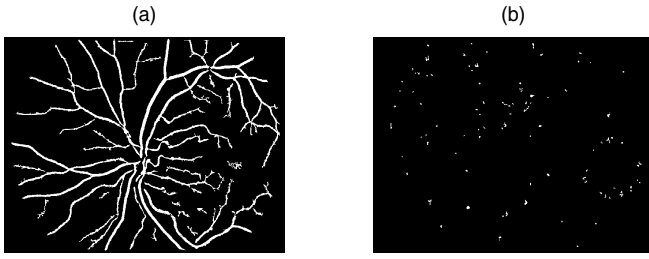


Fig. 5. (a) The vascular map of the retinal image shown in Fig. 3(a) and (b) all the microaneurysm candidates.

be detected, this does mean that many spurious objects are detected as microaneurysm candidates by using the approach described above. For the serious unbalanced dataset problem, the microaneurysm candidate classifiers will be used to remove the spurious objects.

B. Features Extraction

The selection of features is an important aspect for lesion classification, and a feature set comprised of 31 dimensional features were introduced by using the system in [3]. Except for these 31 dimensional features, other 6 features are also automatically extracted and recorded for each segmented candidate in this paper. These new features are based on the maximum, minimum and average of MMMF response, and the maximum, minimum and average of the morphology matched filter response for each microaneurysm candidate. Because the true microaneurysms are uniformity in grey scale, in order to produce the output to represent the uniform of images, the morphology matched filter is defined as the ratio of the maximum $I_{cmax}(x, y)$ and the minimum $I_{cmin}(x, y)$ of morphological closing operation in the image I_{green} as

$$M_{mor}(x, y) = \frac{I_{cmax}(x, y)}{I_{cmin}(x, y)} \quad (7)$$

and it rotates a linear structuring element to different orientations to suppress microaneurysms in all orientations. After the features are extracted from the candidates, the feature vectors will be divided into two groups: true microaneurysms and false microaneurysms.

C. Classification of Microaneurysm Candidates

As aforementioned, the amount of false microaneurysms is considerably larger than that of the true microaneurysms in the final candidate object set, and they should be classified by using the features extracted in Section II.B. Here several classifiers are modified to deal with the tackle this problem.

In this paper, 50 retinal images were prepared, where an ophthalmologist classified each candidate object as a microaneurysm or otherwise in each image. From 50 retinal images, 4719 candidates is carried out gathered with the detection of microaneurysm candidates, and 181 candidates of them are labelled as microaneurysm by the ophthalmologist. Each classifier is trained and tested on this data set, and we initially train the kNN, LLDA and SVM classifiers to reject false

positives. For training the classifiers, each candidate object is represented by a set of 37 features described in Section II.B.

1) *K-Nearest Neighbor*: As a classic approach, the kNN classification finds a group of k objects in the training set that are closest to the test object and bases the assignment of a label on the predominance of a particular class in this neighborhood. The kNN classifier firstly tunes a neighborhood parameter k by 5-fold cross-validation of the training samples, and the output of the kNN classifier does not provide a calibrated posterior probability. The posterior probability p is calculated to enable post-processing, where p is determined by

$$p = \frac{n}{k} \quad (8)$$

in which k is the number of nearest neighbors, and n is the number of the true microaneurysms in the k nearest neighbors.

2) *Local Linear Discriminant Analysis*: The LLDA incorporates several different forms of linear feature component approaches, and it is more powerful than the tradition LDA algorithms, when the global data structure is not completely consistent with local data structure. By considering the characteristic of the datasets: 1) the unbalanced of the data, 2) a large number of negative samples and 3) the correlation between features, we apply the LLDA algorithm to train a subset, which contains the test sample's M nearest neighbors and apply the kNN classifier with probabilistic outputs to classify the candidates as microaneurysms or spurious objects. In this classification, M and k are decided by 5-fold cross-validation of the training samples, and the dimensionality is set as $c - 1$ where c is the number of category. Similarly to the kNN classifier described above, we assign a probability to each candidate.

3) *Support Vector Machine*: The SVM is considered one of the most robust methods among all well-known algorithms. In a two-class learning task, the aim of SVM is to find the best classification function to distinguish between members of the two classes in the training data. In this paper, the SVM classifier adopts the RBF kernel function, which is more reasonable than other kernels, and the 5-fold cross validation and grid search are used to identify two parameters for RBF kernel. Since the standard SVM does not provide probabilities, herein one method to map the SVM outputs into probabilities is used, where a parametric form of a sigmoid function is given by

$$p(y = 1|f) = \frac{1}{1 + \exp(Af + B)} \quad (9)$$

where f is the unthresholded output of an SVM, and A and B are fit using maximum likelihood estimation [9] from the training set.

Finally once each test candidate object is assigned a probability of being a lesion, these probabilities are compared to a threshold probability t in the range $[0,1]$ in increments of 0.05, and then the candidate object is determined as a lesion or not and the ROC and FROC curves are obtained.

TABLE I

THE AVERAGED NUMBER OF FALSE POSITIVES PER IMAGE FOR TRAINING SET.

FPS/scan	1/8	1/4	1/2	1	2	4	8	Average
Method [3]	0.060	0.096	0.138	0.189	0.267	0.311	0.345	0.201
Proposed Approach	0.034	0.067	0.134	0.230	0.365	0.515	0.655	0.286

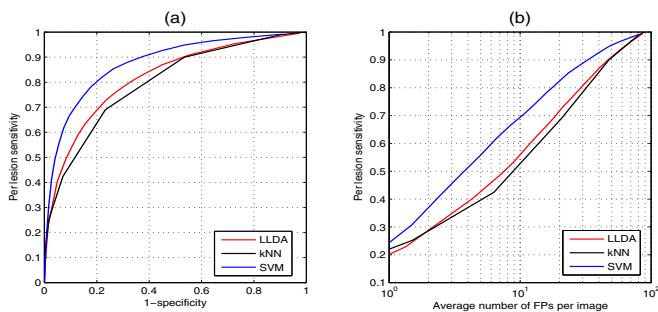


Fig. 6. (a) The ROC curves and (b) the FROC curves of classification results by using the kNN, LLDA, SVM for microaneurysms classification.

III. EXPERIMENT RESULTS AND DISCUSSION

The proposed method is tested by using the training set of the publicly available database ROC, which includes 100 images (split into 50 training and 50 test) with manually labeled ground truth.

Firstly the candidates are carried out gathering from 50 training images through the detection of microaneurysm candidates. Then the kNN, LLDA, SVM classifiers are used to separate the microaneurysms from the false positive foreground objects, where a part of true microaneurysm candidates and false microaneurysms candidates are used to train the classifiers, and the rest candidates are used to test. The classification performance is verified in terms of the sensitivity and specificity on the ROC curves shown in Fig. 6(a), while the FROC curves of all the classifiers produced by plotting lesion sensitivity against average false positives (FPs) per image are compared to determine the better classifier as shown in Fig. 6(b). Obviously we can see that the FROC curve of the SVM classifier has a higher sensitivity than that of other classifier for the same false positives per image.

Furthermore, an experiment is carried out for comparing the effectiveness of the suggested 37 dimensional features and that of 31 dimensional features on the performance of classification. Fig. 7 shows the ROC curves and the FROC curves of detection results by using the SVM for microaneurysms classification, respectively. We can observe that the sensitivity of method based on 37 dimensional features outperforms that based on 31 dimensional features.

In addition, Table I lists the sensitivity of 1/8, 1/4, 1/2, 1, 2, 4 and 8 false positives per image of the proposed method and the method presented in [3]. From this table, we can find that the proposed method has a greater sensitivity from 1/8 to 8 with the average of all seven points being 0.286 and the method [3].

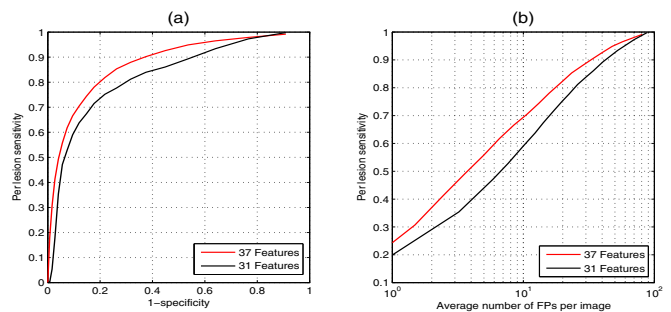


Fig. 7. (a) The ROC curves and (b) the FROC curves of detection results based on the 37 and 31 dimensional features by using the SVM for microaneurysms classification.

IV. CONCLUSION

In this paper, we proposed a new hierarchical approach based on the MMMF and machine learning to detect and classify all microaneurysms from color fundus retinal image. This method was evaluated through the training set of a public retinal image database ROC. The experiment results demonstrated that the proposed method has better detection performance including the ROC curve and the FROC curve and the proposed method with 37 dimensional features outperforms that with other features and has a sensitivity from 1/8 to 8 with the average of all seven points being 0.286 tested on the same database.

REFERENCES

- [1] M.D. Abramoff, M. Niemeijer and S.R. Russell, Automated detection of diabetic retinopathy: barriers to translation into clinical practice, *Expert Review of Medical Devices*, vol. 7, no. 2, pp. 287-296, 2010.
- [2] M. Niemeijer, B. van Ginneken, J. Staal and M.S.A. Suttorp-Schulten, Automatic detection of red lesions in digital color fundus photographs, *IEEE Trans. Medical Imaging*, vol. 24, no. 5, pp. 584-592, 2009.
- [3] B. Zhang, X. Wu, J. You, Q. Li and F. Karray, Detection of microaneurysms using multi-scale correlation coefficients, *Pattern Recognition*, vol. 43, no. 6, pp. 2237-2248, 2010.
- [4] E. Fix and J. Hodges, Discriminatory Analysis. Nonparametric Discrimination: Consistency Properties, *International Statistical Review*, vol. 57, no. 3, pp. 238-247, 1951.
- [5] Z. Fan, Y. Xu and D. Zhang, Local linear discriminant analysis framework using sample neighbors, *IEEE Trans. Neural Networks*, vol. 22, no. 7, pp. 1119-1132, 2011.
- [6] V. Vapnik, *The nature of statistical learning theory*, Springer Science & Business Media, 2000.
- [7] M. Niemeijer, Retinopathy online challenge: automatic detection of microaneurysms in digital color fundus photographs, *IEEE Trans. Medical Imaging*, vol. 29, no. 1, pp. 185-195, 2010.
- [8] Q. Li, R.X. Li, S.G. Miao and J. You, Detection of microaneurysms in color retinal images using multi-orientation sum of matched filter, *Proceedings of 3rd International Conference on Multimedia Technology (ICMT-13)*, vol. 84, pp. 1341-1348, 2013.
- [9] J.C. Platt, Probabilistic outputs for support vector machines and comparisons to regularized likelihood methods, *Advances in Large Margin Classifiers*, pp. 61-74, 1999.