



Is Pickelhaube Sign Really the Hallmark of Arrhythmogenic MVP in Athletes? And Does MVP Really Cause Sudden Death? A Case Report

Masimo Bognesi*

Centre for Sports Cardiology - Internal General Medicine Department, AUSL della Romagna - District of Cesena, Italy

Abstract

The Pickelhaube Sign is today recognized as a novel Echocardiographic Risk Marker for Malignant Mitral Valve Prolapse Syndrome. In this short manuscript the author describes the case of an asymptomatic and fit amateur 46-year old male cyclist who has a mitral valve prolapse with mild to moderate mitral regurgitation. He also showed sporadic uncommon Premature Ventricular Contractions (PVCs) at exercise stress test, and the Pickelhaube sign during sports preparticipation screening. So, his eligibility for sports competition was questionable.

Introduction

Mitral Valve Prolapse (MVP) has long been recognized to be a relatively common valve abnormality in the general population [1,2]. Patients with relatively non-specific symptoms and asymptomatic athletes who have MVP still represent an important clinical conundrum for any physician involved in preventive medicine and sports screening[3]. Although cardiac arrhythmias and/or cardiac death are an undesirable problem in MVP patients, when these subjects were studied with Holter Electrocardiogram (ECG) monitoring a prevalence of ventricular arrhythmias up to 34% was observed, with premature ventricular contractions as the most common pattern (66% of cases) [4]. At this regard a paper by Anders et al. described a series of cases that suggest that even clinically considered benign cases of MVP in young adults may cause sudden and unexpected death[5]. However, cardiac arrest and Sudden Arrhythmic Cardiac Death (SCD) resulted in rare events only in patients with MVP based on data from a community study[6].

For a long time the mysterious entity of the mitral valve prolapse has been the subject of an always fruitful discussion among sports cardiologists in association with scientist and experts of sudden cardiac death. This association between arrhythmogenic mitral valve prolapse and sudden cardiac death of athletes carrying this congenital valve abnormality has recently led many anatomopathologists in collaboration with cardiologists to report some papers about malignant MVP. With this anecdotal case report the author gives information about a typical situation that can occur in the setting of sport medicine and sports preparticipation screening in everyday practice.

Case Report

A middle-aged athletic male who has been practicing competitive cycling for about 20 years came to our Sports Medicine Centre to undergo screening of sports preparation for competitive cycling and the related renewal of certification for participation in sports competitions. This athlete was always considered suitable in previous competitive fitness assessments performed in other sports medicine centers. His family history was unremarkable, as well as his recent and remote pathological anamnesis. The physical examination revealed a regurgitation heart murmur, 3/6 intensity, at the cardiac apex with a click in the mid late systole. Previous echocardiographic examinations revealed a mitral valve prolapse which was considered benign with mild mitral regurgitation hemodynamically not relevant. He did not complain of symptoms such as dyspnea or heart palpitations during physical activity. The resting ECG (Figure 1) showed negative T waves in the inferior limb leads, and the stress test showed sporadic premature ventricular beats (a couple) with right bundle branch block morphology (Figure 2). An echocardiogram confirmed the presence of a classic mitral valve prolapse with billowing of both mitral leaflets (Figure 3), associated with a mild to moderate valve regurgitation. The TDI exam at the level of the lateral mitral annulus showed a high-velocity mid-systolic spike (Figure 4) like a Pickelhaube sign, i.e. spiked German military helmet morphology. Consequently, an in-depth diagnostic imaging with cardiac magnetic resonance imaging was proposed, but the athlete refused it, both because he was totally asymptomatic and above all because he would be forced to pay a considerable amount of money as the examination is not guaranteed by the Italian National Health Service. In conclusion, the athlete remained sub judice as for competitive suitability,

Article Information

DOI: 10.31021/ijcmc.20203137
Article Type: Case Report
Journal Type: Open Access
Volume: 3 Issue: 3
Manuscript ID: IJCMC-3-137
Publisher: Boffin Access Limited

Received Date: 01 January 2020
Accepted Date: 22 January 2020
Published Date: 23 January 2020

*Corresponding author:

Masimo Bognesi
Centre for Sports Cardiology - Internal General Medicine Department
AUSL della Romagna - District of Cesena
Italy
E-mail: massimo.bognesi@medici.progetto-sole.it

Citation: Bognesi M. Is Pickelhaube Sign Really the Hallmark of Arrhythmogenic MVP in Athletes? And Does MVP Really Cause Sudden Death? A Case Report. 2020 Jan;3(3):137

Copyright: © 2020 Bognesi M. This is an open-access article distributed under the terms of the Creative Commons Attribution 4.0 international License, which permits unrestricted use, distribution, and reproduction in any medium, provided the original author and source are credited.

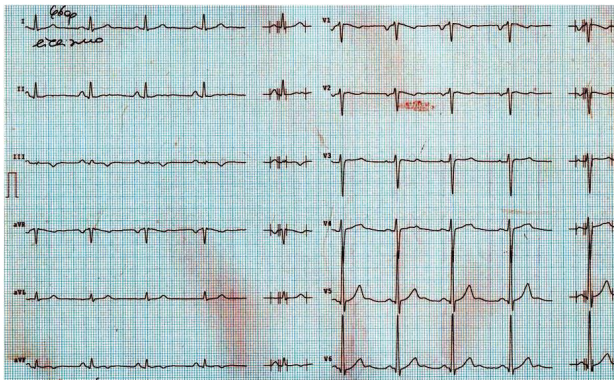

Figure 1: Resting ECG shows negative T waves in the inferior limb leads

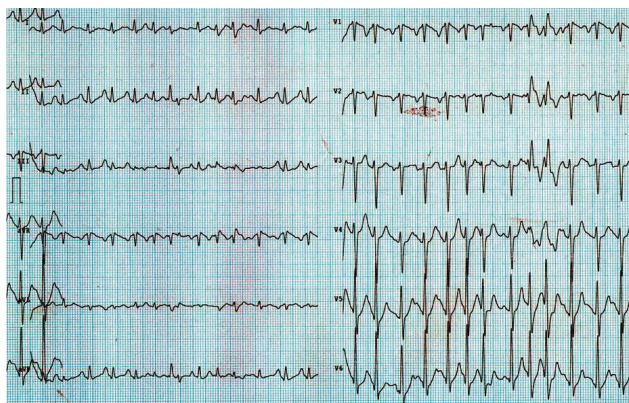


Figure 2: Ex-ECG stress test shows a couple of PVCs with RBBB morphology

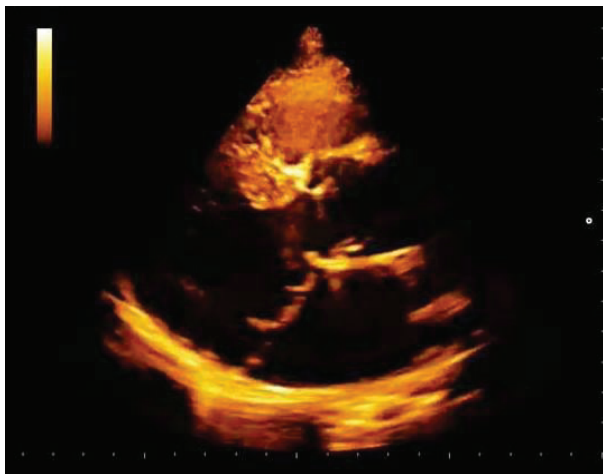

Figure 3: 2DTT echocardiogram shows a classical billowing of bileaflets MVP

and was then lost in the follow up with filed practice not having delivered the required tests.

Discussion

The association between arrhythmogenic mitral valve prolapse and sudden death of athletes is a growing topic between experts of sports cardiology medicine. This congenital mitral valve abnormality has recently led many anatomopathologists in collaboration with cardiologists to report some papers about malignant MVP. However, this makes us wonder why, despite being such a frequent anomaly in

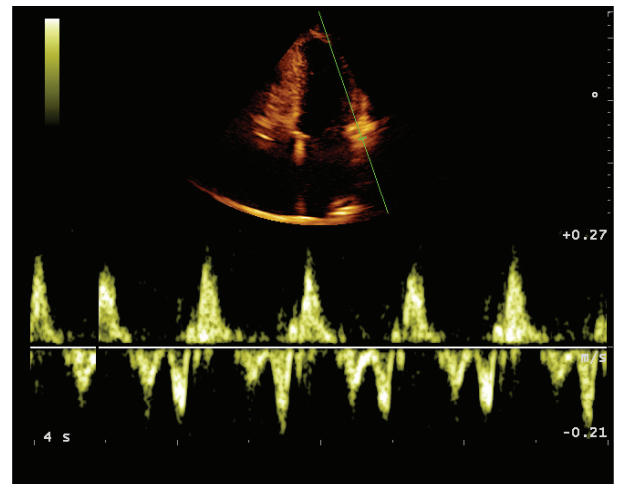


Figure 4: 2DTT echocardiogram shows TDI pattern with high-velocity mid-systolic spike named Pickelhaube Sign, like spiked German military helmet

the population, the risk of sudden death is so rare and so difficult to prove. Indeed, only autopsy examinations have shown the presence of MVP in people and athletes who died suddenly without any other apparent structural or organic heart disease, so this logical deduction and clinical association was born. In order to reinforce such assumption, even cardiovascular imaging diagnostics have shown that these subjects with high-risk arrhythmogenic PVM often show mitral postero lateral mitral fibrosis with evidence of LGE[7,8]. So, what more does it takes today to stop all athletes showing these arrhythmogenic electrocardiographic, echocardiographic and cardiovascular imaging features? Brilliant authors hypothesize that the tugging of the posteromedial papillary muscle in mid-systole by the myxomatous prolapsing leaflets causes the adjacent posterobasal left ventricular wall to be pulled sharply toward the apex, resulting in the showed spiked configuration of the lateral annular velocities[7]. Furthermore, it has been suggested that this mechanical traction of the papillary muscles and posterolateral left ventricular wall is arrhythmogenic with early electrical dysfunction being recognized during electrophysiological studies even in the absence of gadolinium enhancement on CMR[8]. Endocardial friction lesions in the inferolateral mural endocardium are considered able to provoke ventricular arrhythmias in myxomatous mitral valve disease and MVP[9]. In addition, recent CMR studies[10] have shown delayed gadolinium enhancement in these areas suggesting a myocardial damage like fibrosis. All these newest findings support the assumption of the emerging risk markers of arrhythmogenic MVP syndrome, suggesting the possibility, but not the probability, that this spiked tissue Doppler velocity profile may be a risk marker for malignant arrhythmias in patients with Myxomatous Mitral Valve Disease and Bileaflet Mitral Valve Prolapse.

Conclusion

Finally, the question is: does MVP really cause sudden death? Is it enough to detect the Pickelhaube signal by echocardiography to stop this athlete? Let us bear in mind that this athlete was asymptomatic, and he had not had any trouble during exercise and maximal effort for many years. Why must we declare him unsuitable to do competitive sports? What are the probabilities that he could have sudden cardiac death? Just because there is a new theorem about sudden cardiac death and MVP? In my humble opinion, there appears to be a slight increase in the risk of sudden death from ventricular tachycardia or ventricular fibrillation in people who have truly significant MVP, but not in the large majority of people who have received the diagnosis of MVP. Most athletes diagnosed with MVP have an extremely mild form of the condition, which carries no measurable risk, even though they have the Pickelhaube sign or slight myocardial fibrosis at the

basal posterior and inferolateral LV wall. Initial evidence that MVP may be associated with sudden death came mainly from autopsy series. In studies in which the heart has been carefully examined in people who have died suddenly, evidence of MVP can be found in a substantial minority. So naturally, MVP has been assumed to be the cause of these sudden deaths. However, two things are generally not mentioned in these studies. Firstly, many sudden death victims have no identifiable cardiac abnormality at all. Secondly, when there is a determination to find MVP, at least some evidence of it will be found in a large proportion of the general population. There is very little evidence that the vast majority of people diagnosed with MVP have any measurably increased risk of sudden death. Therefore, it is very difficult to penalize and disqualify asymptomatic athletes who are carriers of PVM and other signs such as Pickelhaube, only on the basis of theorems and hypothetical assumptions elaborated by genius minds such as the world's experts on sudden cardiac death, when in fact there are arrhythmogenic cardiac deaths and channelopathies still unknown today that occur in athletes with structurally normal hearts and/or other mild anomalies without any meaning. The screening of sports preparticipation in Master amateur or Veteran athletes hides many pitfalls and controversies. The current knowledge in this field is really rare, considering that the Italian law is based on scientific evidence carried out on a population of young people less than 35 years of age. The high incidence of false positives in middle-aged amateur athletes leads to requiring additional and expensive cardiovascular imaging examinations, with the real possibility that these third-level cardiological examinations will fail to solve the clinical question if the athlete could have a submerged and potentially dangerous disease. This is detrimental for the individual athlete, sports and health service.

References

1. Delling FN, Rong J, Larson MG, Lehman B, Osypiuk E, et al. Familial clustering of mitral valve prolapse in the community. *Circulation*. 2015 Jan;131(3):263-268.
2. Devereux RB, Kramer-Fox R, Brown WT, Shear MK, Hartman N, et al. Relation between clinical features of the mitral prolapse syndrome and echocardiographically documented mitral valve prolapse. *J Am CollCardiol*. 1986 Oct;8(4):763-772.
3. Boudoulas H, Wooley CF. Mitral Valve: Floppy Mitral Valve, Mitral Valve Prolapse, Mitral Valvular Regurgitation. *Current Treatment Options in Cardiovascular Medicine*. 2001 Feb;3(1):15-24.
4. Zuppiroli A, Mori F, Favilli S, Barchielli A, Corti G, et al. Arrhythmias in mitral valve prolapse: relation to anterior mitral leaflet thickening, clinical variables, and color Doppler echocardiographic parameters. *Am Heart J*. 1994;128(5):919-927.
5. Anders S, Said S, Schulz F, Puschel K. Mitral valve prolapsed syndrome as cause of sudden death in young adults. *Forensic Sci Int*. 2007;171(2-3):127-130.
6. Narayanan K, Uy- Evanado A, Teodorescu C, Reinier K, Nichols GA, et al. Mitral Valve Prolapse and Sudden Cardiac Arrest in the Community. *Heart Rhythm* 2016 Feb;13(2):498-503.
7. Muthukumar L, Rahman F, Jan F. The Pickelhaube Sign Novel Echocardiographic Risk Marker for Malignant Mitral Valve Prolapse Syndrome. *Jacc: Cardiovascular Imaging*. 2017 Sep;10(9):1076-1080.
8. Syed FF, Ackerman MJ, McLeod CJ. Sites of successful ventricular fibrillation ablation in bileaflet mitral valve prolapse syndrome. *CircArrhythmElectrophysiol*. 2016 May;9(5):e004005.
9. Basso C, Perazzolo Marra M, Rizzo S. Arrhythmic mitral valve prolapse and sudden cardiac death. *Circulation* 2015 Aug;132(7):556-566.
10. Han Y, Peters DC, Salton CJ. Cardiovascular magnetic resonance characterization of mitral valve prolapse. *J Am CollCardiolImaging*. 2008 May;1(3):294-303.