



RESEARCH ARTICLE

ANTHROPOMETRIC STUDY OF PROXIMAL END OF DRIED ADULT HUMAN FEMUR: A CROSS SECTIONAL STUDY

Dr. Gurpreet Singh¹, Sukhman Kahlon¹, Dr. Shehnaz², Dr. Geetika Arya², Dr. Ravina Vashishth³, Dr. Vishal Asar³, Dr. Sukhdeep Sran⁴ and Dr. Aparajeeta Paul⁴

Manuscript Info

Manuscript History

Received: 29 November 2022

Final Accepted: 30 December 2022

Published: January 2023

Key words:-

Femur, Orthopedician, Stature,
Anthropologists, Neck

Abstract

Introduction: Femur is the longest and strongest bone of the human body. Its length is associated with a striding gait, its strength with weight and muscular forces. It comprises of an upper end, shaft and lower end. Proximal part of femur includes head, neck, greater and lesser trochanters.

Objectives: The present study aimed to record the femoral length and head diameter parameters were carried out which would be of help to the orthopedicians while carrying out surgical repairs around the hip joint especially in fracture of the neck of femur.

Material & Methods: A total of 100 North Indian unpaired dry adult human femora (Right-50, Left-50) of unknown sex were studied. Femoral length and Head Diameter of the femur were measured with the help of osteometric board and vernier caliper and recorded in centimeters. The raw data obtained were statistically analyzed. Range, mean, standard deviation, and standard error of mean were determined. Results: - The mean femoral length was found to 43.93cm (Right-44.53cm and Left- 43.33cm) with a range of 38.5 – 58.8cm (Right = 38.5 – 58.8cm and Left=38.5 – 51.3cm). The mean femoral head diameter was 39.35mm (Right = 39.86mm and Left =38.84mm) with a range of 20 – 47mm (Right = 20 – 46mm and Left = 32 - 47mm). No significant difference in values of femoral parameters were found in the right and left femur.

Conclusion: The overall goal of this study was to generate information that would be useful for geometric modeling of femora and collecting data which could prove useful for the development of prosthetic implants.

Copy Right, IJAR, 2023,. All rights reserved.

Introduction:-

Femur is the longest and strongest bone of the human body. Its length is associated with a striding gait, its strength with weight and muscular forces. It comprises of an upper end, shaft and lower end. Proximal part of femur includes head, neck, greater and lesser trochanters. Head is slightly more than half a sphere; it faces anterosuperomedially to articulate with the acetabulum to form hip joint. Its smoothness is interrupted posteroinferior to its center by a small, rough fovea¹.

The morphology of proximal femur is an essential parameter in the design and development of implant because inappropriate implant design and size could affect outcome of the surgery with reported complications such as stress shielding, micro motion, and loosening². Undersized or overhanging femoral implants could lead to altered soft tissue tensioning and altered patella femoral stresses³. Bony marking such as the head and neck of femur can be used in determination the femoral length when only one fragment of proximal femur is available and the required size of length of neck can be determined to design prosthesis for restoration of normal neck shaft angle⁴. In case of total hip arthroplasty, it is mandatory that the design and dimensions of femoral component should match the anatomy of proximal femur. In clinical practice, if the implant happens to be ill-fitting, hip dislocation and implant fractures are quite common⁵.

Intact long bones of lower extremities have been used in derivation of regression equation for estimation of stature in different population groups. These bodies are sometimes presented to forensic anthropologists in different states of fragmentation, thereby making derived equations unstable this has to necessitate the need to assess the usefulness of measurement of fragments of long bones in estimation of stature⁶.

It is an important to know the morphometric characteristics of the proximal femur, with the intent of minimizing the risk of complications related to surgical procedures executed in the area due vascular traumatic or metabolic causes, and to achieve an alignment of prosthesis to be implanted⁷. Most of the Indian orthopaedic surgeons have currently felt the need for the modification in implant sizes suitable for Indian population⁸. Thus, in addition to the orthopaedic surgeons this study will be of great help to the anatomists, anthropologists, forensic experts and radiologist also. Moreover, not much study has been done on morphometric analysis of proximal part of the femur in North Indian population.

Material & Methods:-

A total of 100 North Indian unpaired right and left dry adult human femora of unknown sex were studied from teaching collection of the Anatomy department, Guru Gobind Singh Medical College, Faridkot. Out of the total of 100 femora, 50 were of the right side and 50 were of the left side. All the femora were complete and showed normal anatomical features. Bones with any gross abnormality or broken bones were excluded from the study

Femoral Length (FL):

It is the distance from highest point of femur head to the lowest point of medial condyle. It will be measured by placing the femur on to the osteometric board and recorded in centimeter (cm).

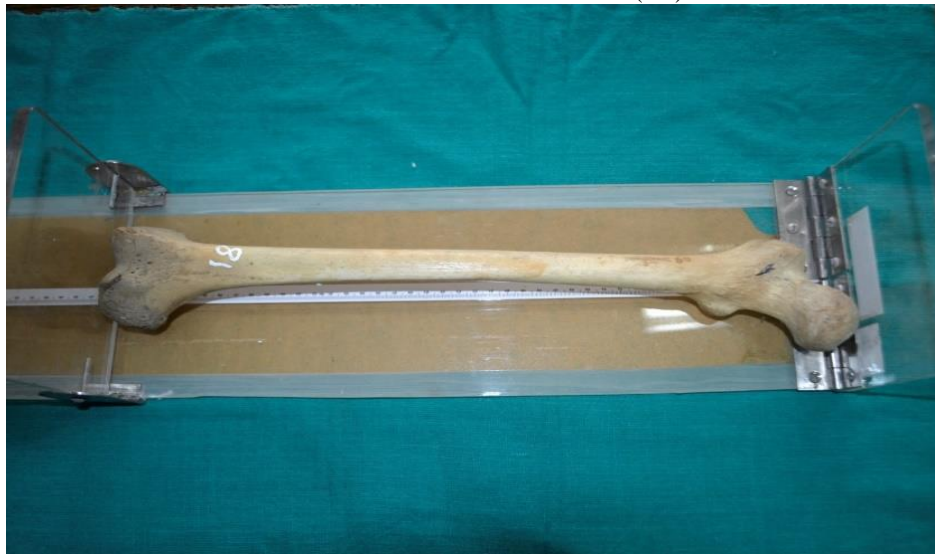

Fig No. 1:- Showing the measurement of Femoral Length on osteometric board.

Femoral Head Diameter (FHD):

It will be measured as distance in a straight line between the upper end to the lower end of femoral head in cranio-caudal axis and taken with the help of vernier caliper. It is recorded in millimeters (mm).

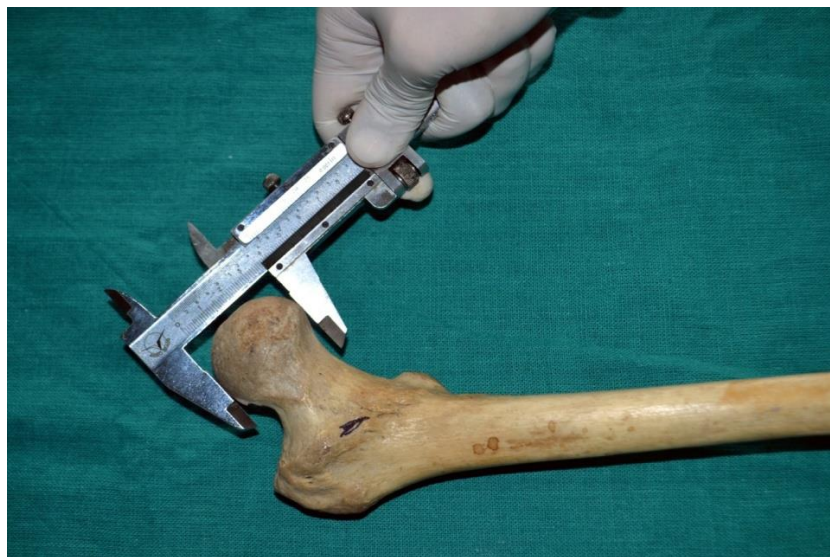

Fig No. 2:- Showing the measurement of Femoral Head Diameter of with the help of vernier caliper.

Results: -

A total of 100 femora (50 right and 50 left) were studied. Overall range, mean, standard deviation, and standard error of mean and distribution on the right and left side of parameters are given in Tables 1-2.

Table no 1:- Showing Parameter of Femoral Length of Right and Left Femur (cm).

Side	Range	Mean	SD	SEM
Right	38.5 – 58.8	44.53	3.76	0.53
Left	38.5 – 51.3	43.33	3.00	0.42
Total	38.5 - 58.8	43.93	3.44	0.47

p- value 0.081 (non-significant).

Graph no. 1:- Showing Parameter of Femoral Length of Right and Left Femur (cm).

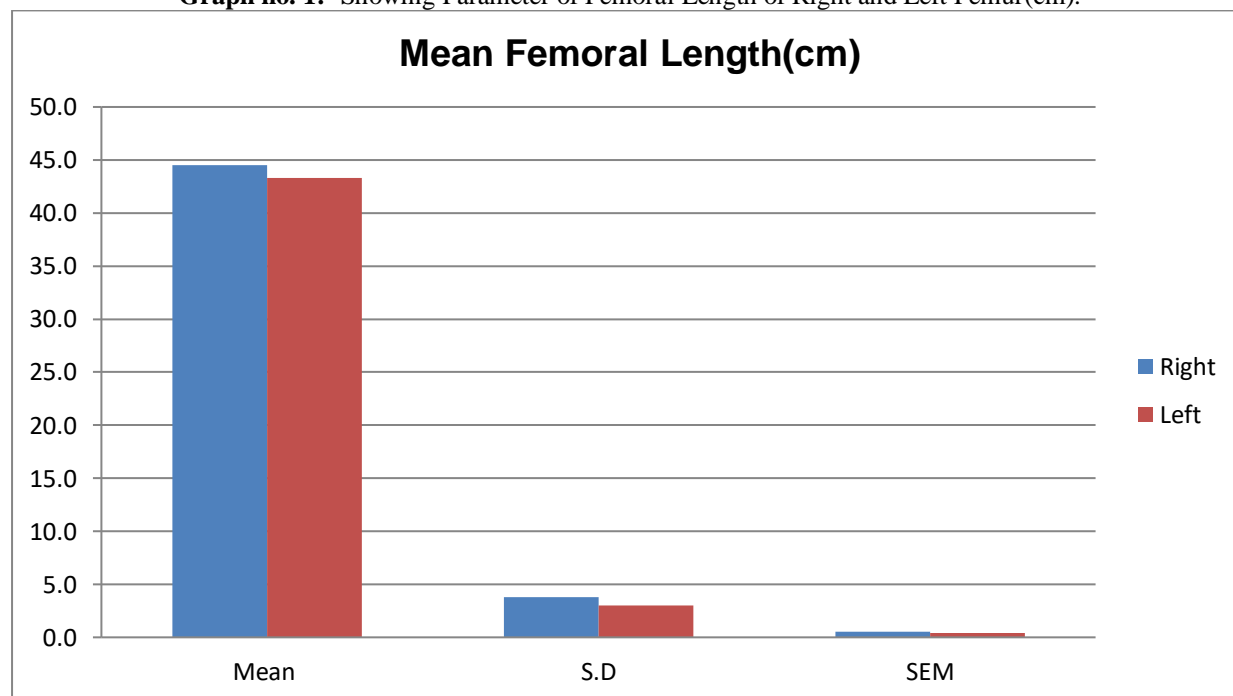
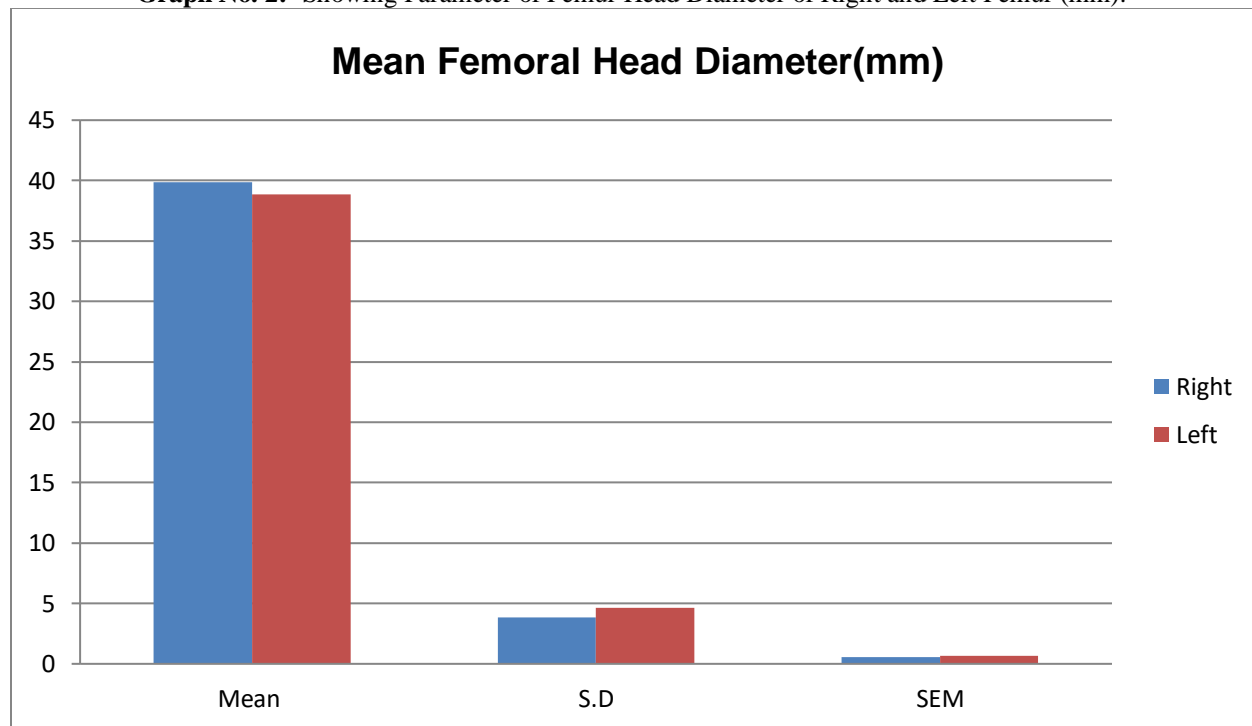


Table No2:- Showing Parameter of Femoral Head Diameter Right and Left Femur (mm).

Side	Range	Mean	SD	SEM
Right	20 – 46	39.86	3.82	0.54
Left	32 – 47	38.84	4.63	0.65
Total	20 – 47	39.35	4.25	0.59

p- value 0.233(non-Significant)

Graph No. 2:- Showing Parameter of Femur Head Diameter of Right and Left Femur (mm).

Discussion: -

The femoral length and head Diameter are two parameter which has been extensively studied by many workers. The parameter was taken with the help of osteometric board, vernier caliper and computed tomography. The present study was conducted on 100 (50 right and 50 left) dry adult human femora in North Indian Population. The mean femoral length was found to 43.93cm (Right- 44.53cm and Left-43.33cm) with a range of 38.5 – 58.8cm (Right=38.5 – 58.8cm and Left=38.5 – 51.3cm). The mean femoral head diameter was 39.35mm (Right=39.86mm and Left=38.84mm) with a range of 20 – 47mm (Right=20 – 46mm and Left= 32 - 47mm).

200 ossified femora belonging to skeletons of known age, sex and stature were studied by Shroff et al⁹. They divided the femur into five segments and found that mean of total length was 43.93 cm. They correlated the length of maximum number of segments of femur with total length of femur so that even if a small segment of femur was available, stature could be estimated fairly accurately. Also, the study done by Reddy et al¹⁰ analyzed length of femur was 43.55cms (SD=2.283).

Khan et al¹¹ in year 2014 studied on 250 femora and recorded the length of femur was 446.2+26.39mm, right femur was 446.6+26.66mm and left femur was 445.8+26.12mm.

Neelima et al¹² did study on 60 dried femora the mean values for the various parameters were as follows: length of femur was 414.83mm and diameter of head was 122.5mm,

Sousa et al¹³ in the year 2010 studied on 110 Brazilian human femur (49 right and 61 left) they found that femoral head diameter (FHD) 31.1+2.7mm and 30.8+3.0mm.

Ravi et al¹⁴ conducted a study on 592 dry femurs in South Indian population and found the average length of femur was 447.1±28.94mm (right femur 447.9±28.72mm and (left femur -446.2±29.12mm).

The present study was in consonance with Shroff et al⁹ and Reddy et al¹⁰. The values quoted by Khan et al¹¹ and Ravi et al¹⁴ are higher than present study. They did their study on South Indian population. Neelima et al¹² measured length of femur on Visakhapatnam subjects and the values were lesser than the present study. This disparity in values may be due to racial variation as quoted by other workers.

The present study observation of the mean femoral head diameter of femur is 39.35mm which is near in accordance with the study done by Neelima et al¹². Apart from India, studies have been conducted on other population like study on Brazilians population by Souse et al¹³. The mean length of right and left femur of present study are higher than Brazilians population because Indian are tall statured and well built.

Conclusion: -

The overall goal of this study was to generate information that would be useful for geometric modeling of femora and collecting data which could prove useful for development of prosthetic implants. In cases, where destruction of femora is extensive, due to trauma or some disease, the data may be helpful for sizing the replacement and reconstructing normal alignment. However, it should be kept in mind, that the present study had a smaller number of femur bones, so it is worthwhile to perform similar study on a greater number of bones for its theoretical and practical importance in the coming years.

References: -

1. Standring S. Gray's Anatomy. 42nded. London: Churchill Livingstone; 2016. Chapter 80, Pelvic girdle, gluteal region and thigh; p.1348-1351.
2. Baharuddin MY, Kadir MR, Zulkifly AH, Saat A, Aziz AA, Lee MM. Morphology study of the proximal femur in Malay population. *Int J Morphol* 2011;29:1321-1325.
3. Gnudi S, Ripamonti C, Lisi L, Fini M, Giardino R, Giavaresi G. Proximal femur geometry to detect and distinguish femoral neck fractures from trochanteric fractures in postmenopausal women. *Osteoporos Int* 2002;13:69-73.
4. Bidmos MA. Estimation of stature using fragmentary femora in indigenous South Africans. *Int J Legal Med* 2008;122:293-299.
5. Chowdhary S, Naushaba H, Begum J, Ahmed S, Khan LF, Parash TH, et al. Morphometrical and topographical anatomy of position of nutrient foramen on fully ossified left femur. *Delta Med Coll J* 2013;1:13-18.
6. Ravichandran D, Muthukumaravel N, Jaikumar R, Das H, Rajendran M. Proximal femoral geometry in Indian and Its Clinical applications. *J Anat Soc India* 2011; 60(1):6-12.
7. Krogman WM and Iscan MY. Human skeleton in forensic medicine. 2nded, Springfield, Charles C, Thomas. 1986.
8. Mahaisavariya B, Sitthiseripratip K, Tongdee T, Bohez EL, Sloten J & Oris P. Morphological study of the proximal femur: a new method of 57 geometrical assessment using 3-dimensional reverse engineering. *Med Eng Phys* 2002; 24(9):617-22.
9. Shroff AG, Panse AA, Diwan CV. Estimation of length of femur from its fragments. *J Anat Soc India* 1999; 48(1):1-5.
10. Reddy KS, Kumar DA. Morphometry of proximal end of femur in population of Telangana state and its clinical application. *Indian J Clin Anat and Phy*, January-March, 2019; 6(1):57-60.
11. Khan SM, Saheb SH. Study on neck shaft angle and femoral length of South Indian femurs. *Int J Anat Res* 2014; 2(4):633- 635.
12. Neelima P, Ravi R, Sand Hima AB. A study on morphometric measurement of adult dried femora in Visakhapatnam. *Int J Adv Res* 2016; 4(8):564-567.
13. DE Sousa E, Fernandes R.M.P, Mathias M.B, Rodrigues M.R, Ambram A.J and Babiniski M.A. Morphometric study of proximal femur extremity in Brazilians. *Int J Morphol* 2010:835-840.
14. Ravi GO, Saheb SH, Abraham RJN. A morphometric study of femur and its clinical importance. *Int J Intg Sci* 2016; 3(7):341-344.