



Journal Homepage: -www.journalijar.com

INTERNATIONAL JOURNAL OF ADVANCED RESEARCH (IJAR)

Article DOI:10.21474/IJAR01/14679

DOI URL: <http://dx.doi.org/10.21474/IJAR01/14679>



RESEARCH ARTICLE

A COMPARATIVE EVALUATION OF EFFICACY OF DIFFERENT OBTURATION TECHNIQUES USING CBCT: AN IN VITRO STUDY

Dr. Anu Susan Joy¹, Dr. Deepti Jawa Singh², Dr. Rani Somani³, Dr. Shipra Jaidka², Dr. Sanjeet Singh⁴, Dr. Deepa P.¹, Dr. Anaswara S.¹ and Dr. Serene M.S.¹

1. Post Graduate Student, Department of Pediatric and Preventive Dentistry, Divya Jyoti College of Dental Science and Research.
2. Professor, Department of Pediatric and Preventive Dentistry, Divya Jyoti College of Dental Science and Research.
3. Professor and Head of the Department, Department of Pediatric and Preventive Dentistry, Divya Jyoti College of Dental Science and Research.
4. Professor and Head of the Department, Department of Oral & Maxillofacial Pathology And Oral Microbiology, Divya Jyoti College of Dental Science and Research.

Manuscript Info

Manuscript History

Received: 05 March 2022

Final Accepted: 08 April 2022

Published: May 2022

Key words:-

Endodontic Pressure Syringe,
Lentulospirals, Local Anasthetic
Syringe, Pastinject

Abstract

Introduction: Pulpectomy helps in preserving a pulpally involved primary tooth by extirpating the diseased pulp associated with microorganism and debris from the canal and obturating with an antibacterial resorbable filling material

Aim: To evaluate and compare the obturation quality interms of underfilling, optimal filling, over fillings, and voids in single rooted teeth amongst the 4 different obturation techniques using cone beam computed tomography(C.B.C.T.)

Method: 40 freshly extracted single rooted teeth were collected and where arranged on U shaped arch ,each arch contained 10 teeth each and 4 groups and obturated with lentulospiral technique, local anaesthetic syringe, endodontic pressure syringe, pastinject technique. The assessment of obturation technique was done using CBCT. For evaluating quality of obturation and voids in the obturated canals, based on the following criteria given by Coll and Sadrian (1996) was used for CBCT and checked for Under filling ,Optimal filling ,Over filling and Voids.

Results: Pastinject showed 90% of optimal filled canals and minimum void. Endodontic pressure syringe showed minimum number of optimum filled canals(20%)

Conclusion: Pastinject technique of obturation proved to be the best in terms of optimal filling and less number of voids.

Copy Right, IJAR, 2022,. All rights reserved.

Introduction:-

Dentistry has evolved into an extremely refined and technologically developed profession. As the field of dentistry advances, it has many scientific improvements¹. Endodontics has an expanded role as it relates to preservation of healthy dental pulp¹. As primary teeth are the best space maintainers, preservation of intact primary dentition until

Corresponding Author:- Dr. Anu Susan Joy

Address:- Post Graduate Student, Department of Pediatric and Preventive Dentistry, Divya Jyoti College of Dental Science and Research.

eruption of the permanent successors is very important in maintaining integrity of the arch form.² Pulp therapy is widely used in relation with pediatric patients, while attempting to prevent premature exfoliation of primary teeth.

Pulpectomy helps in preserving a pulpally involved primary tooth by extirpating the diseased pulp associated with microorganism and debris from the canal and obturating with an antibacterial resorbable filling material³. Different obturation techniques like conventional manual condensation by amalgam pluggers, tuberculin syringe, disposable injection technique, endodontic pressure syringe, lentulospiral, mechanical syringe, incremental filling technique using endodontic finger or hand plugger, jiffy tube, reamer technique, insulin syringe technique, cotton pellet, paper point, navitip technique, past inject, etc¹ have been used to obturate primary teeth root canals.⁴

The success of pulpal treatment depends on the obturation. The ideal requirements of the obturation is it should provide good hermetic seal, it should have good adhesion to the canal wall, it should be radiopaque, it should not stain the tooth, it should not shrink upon setting, it should be bacteriostatic, it should be resorbable and non soluble with tissue fluids which will lead to a successful endodontic treatment, which further leads to good prognosis of the teeth⁵.

An ideal technique should assure complete filling of the canal without overfill and with minimal or no voids.⁶ Clinical indication of a completely filled canal is the expression of the filling material out of the coronal portion of the canal during the obturating procedure. Conformation of filling quality is obtained from postoperative radiograph. The lentulo spiral is the most commonly used instrument as the root canal paste carrier. The obturating paste can be filled by means of a manual lentulo spiral or mounted on micromotor handpiece.³ The process is easy and economical. Filling the root canal does not produce a densely compacted root canal filling and much reliance is placed on adherence of the paste to the walls of the canal.³

Another simple method of completely obturating canal space and filling the apical portion of the root canal is disposable syringe and thereby, eliminating voids and incomplete filling along the root canal space.³

The Greenberg and Katz [1961] designed endodontic pressure syringe, another method of filling the apical portion of the root canal and completely obturating the root canal space. It eliminates voids and incomplete filling at the apex and along the length of a solid core and the canal walls.⁶

The past inject paste carrier is a specifically designed device and works similarly to the lentulo spiral. The past inject provides good placement of the obturating material, while eliminating voids and providing a high density of the obturating materials³.

So far, none of the obturation techniques available have been found ideal for obturation of root canals in primary teeth. Pastinject are used for the placement of calcium hydroxide and root canal sealers in the permanent teeth, but there are not enough studies to evaluate their use as obturation technique.³ Obturation quality of in vivo or in vitro techniques can be evaluated using radiographs, fluid filtration, bacterial leakage, dye penetration, radio isotopes, microscopic analysis, clearing technique and digital radiography like radiovisiography (R.V.G) or cone beam computed tomography (C.B.C.T) method.⁷ Radiographs are the most common technique used but the major drawback is that it does not assess completeness of obturation in three dimensions. Therefore, there is a need for a relatively advanced new technology in dentistry like C.B.C.T. This may provide more precise 3-D information about volumetric analysis of root canal fillings, determining the complex morphology of roots, canals and various anomalies of the teeth without sectioning the study material.⁷ Thus this study was undertaken to compare traditional techniques like Lentulo spiral, disposable local anaesthetic syringe technique and pressure syringe, with Pastinject as obturation techniques.

Aim :

To evaluate and compare the obturation quality in terms of underfilling, optimal filling, over fillings, and voids in single rooted teeth amongst the 4 different obturation techniques using cone beam computed tomography (C.B.C.T.)

Material And Method:-

For the study 40 freshly extracted single rooted teeth were collected and having complete roots or with two-thirds of remaining roots were included. grossly decayed and having root caries, Fractured teeth with more than one-third of root resorption were excluded.

Access cavity was prepared and patency of the canals was checked using a 10 K file. Root canals were instrumented till file number 30–35. All the canals were irrigated with normal saline. Then the canals were dried using appropriate size paper points.

Sample division

40 single rooted teeth on which access opening was done was randomly divided into 4 groups equally (10 each)

Preparation of model

A model of “U” shape was made using modeling wax. Four of such models were made such that it mimicked the natural arch form of human jaw. To these, U shaped arch specimens on which prepared samples were embedded such a way that the root was inside the wax while rest was exposed. Each arch contained ten teeth. (fig 1).

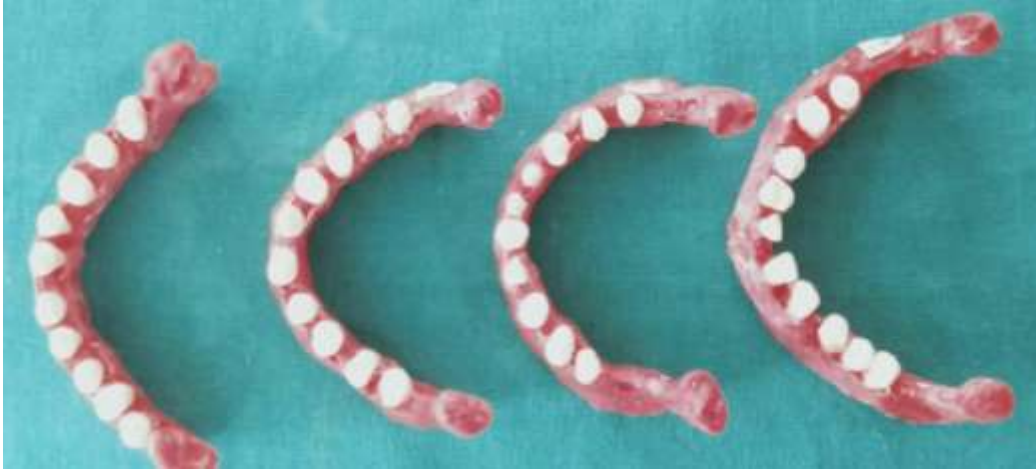

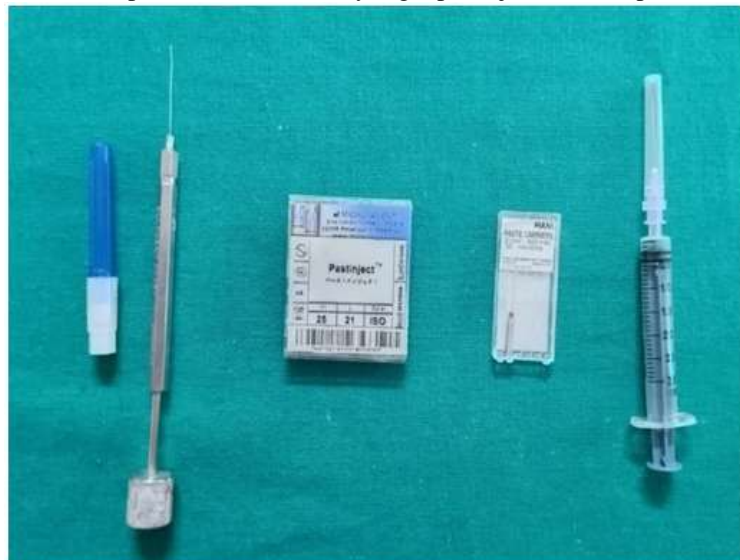Fig 1:- wax pattern with samples.

Root canal obturation

The prepared root canal were filled using slow setting zinc oxide eugenol paste with four different methods. To achieve a similar creamy mix of ZOE, the paste was obtained by mixing one volume unit of powder with 2 volume unit of liquid. A homogenous mixture of ZOE, according to manufacturer instructions, was used for filling the root canals. The paste was transported into the root canals for each tooth using one of the randomly assigned assessed techniques.

Based on technique of obturation, it was divided into 4 groups. (fig :2)

Fig 2:- Endodontic pressure needle and syringe, pastinject, lentulospirals, LA syringe.



Group I: 10 teeth obturated with lentulospiral technique.

Group II: 10 teeth obturated with local anaesthetic syringe

Group III: 10 teeth obturated with endodontic pressure syringe.

Group IV: 10 teeth obturated with pastinject technique.

Group 1 Lentulospiral Technique: Prepared root canals were filled with ZOE paste mixed to a creamy consistency.

The lentulo spiral was used in a slow-speed handpiece, it was inserted into the canal, rotated in a clockwise direction, and withdrawn gently from the canal while still rotating. A rubber stopper was used to keep the lentulo spiral 1 mm short of the working length, and the process was repeated 5 to 7 times for each canal until the canal orifice appeared filled with the paste.

Group II Local Anaesthetic Syringe: Prepared root canals were obturated using a local anesthetic syringe. A local anesthetic syringe (Disposable 2-ml syringe DispoVan) (fig 6) with 27-gauge, 1.5-inch length needle was used. The needle was inserted into the root canal right up to 1 mm short of apical foramina and the material was gently pushed into the root canal till the material was seen flowing out of the canal orifice. Now, the needle was gradually withdrawn while pushing the material till the needle reaches the pulp chamber.

Group III Endodontic Pressure Syringe: Prepared root canals were filled with ZOE paste mixed to a creamy consistency using an endodontic pressure syringe (pulpdent, root canal pressure syringe) with a 30-gauge needle. Remove the white cap from the 30 gauge pressure syringe needle and completely fill the hub of the needle with the thick mix. The filling of the hub was done using a plastic instrument by pressing it tightly into the needle hub, eliminating air pockets. Make sure the barrel and screw plunger are separated. Then needle was threaded onto the pressure syringe barrel and hand tightened using the color plastic sheath as a holder. Remove the color plastic sheath from the pressure syringe needle. Turn the screw plunger clockwise until sealer begins to extrude at the end of the needle using the root canal stop as the guide, the needle was placed into the root canal 1-2 mm from the apex. The needle has been bent for easy access. The needle was inserted into the root canal and using a slow, withdrawing-type of motion, the needle was withdrawn in 3 mm intervals with each quarter turn of the screw until the canal was visibly filled at the orifice.

Group IV Pastinject Technique: Prepared root canals were filled with ZOE paste mixed to a creamy consistency using pastinject (micromega). It was inserted 1 mm short of the root canal apex of teeth, thus reducing the risk of fracture. Its great flexibility allows it to perfectly follow the shape of the canal. The instrument's helical shape creates a translational movement, facilitates the transport of the filling material and guarantees its perfect application onto the canal walls. Motor driven technique of obturation in a slow speed handpiece was used in filling the material inside the canal, rotated in a clockwise direction, and withdrawn gently from the canal while still rotating. A rubber stopper was used to keep the 1 mm short of the working length, and the process was repeated 5 to 7 times for each canal until the canal orifice appeared filled with the paste.

Then the orifice was closed with thick zinc oxide eugenol paste.

Assessment of Obturation Techniques:

For evaluating quality of obturation and voids in the obturated canals, based on the following criteria given by Coll and Sadrian (1996) was used for CBCT:

- Under filling (Score 1): All the canals were filled more than 2 mm short of the apex.
- Optimal filling (Score 2): One or more of the canals having obturating material ending at the radiographic apex or upto 2 mm short of the apex..
- Over filling (Score 3): Any canal showing obturating material extending beyond the radiographic apex..
- Voids: Obturated canals showing voids (presence/ absence).

For evaluating obturation quality using CBCT (Genoray Papaya 3D Plus CBCT Machine), U shaped arch with samples were undergone CBCT individually.

Results:-

	Under filled (Score 1)	Optimum Filled (Score 2)	Over Filled (Score 3)
Group I	02 (20%)	07 (70%)	01 (10%)
Group II	02 (20%)	06 (60%)	02 (20%)

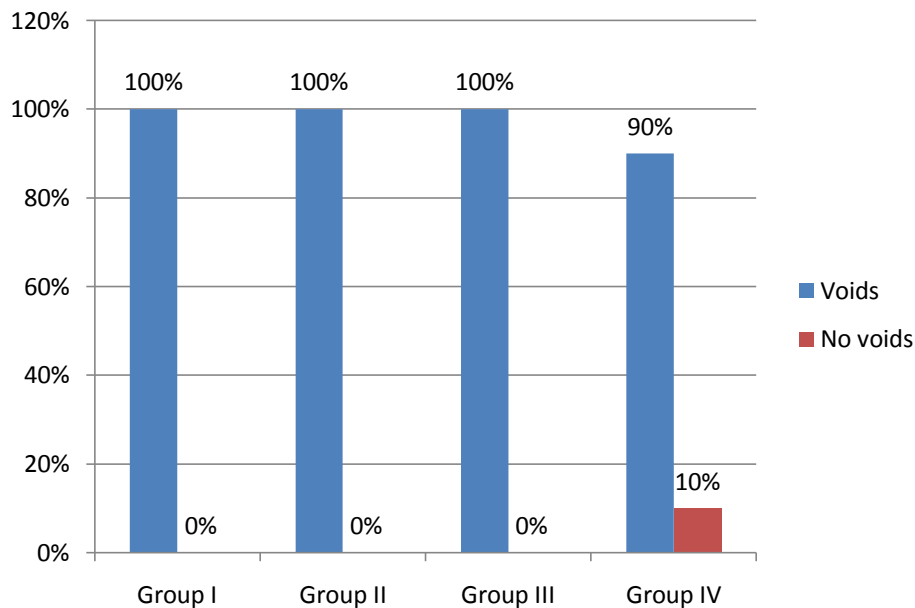
Group III	06 (60%)	02 (20%)	02 (20%)
Group IV	0 (0%)	09 (90%)	01 (10%)

Table 1:- Values obtained after obturation using different techniques –CBCT.**One Way ANOVA Table**

	Sum of Squares	df	Mean Square	F	Sig.
Between Groups	1.400	3	.467	1.183	0.330
Within Groups	14.200	36	.394		
Total	15.600	39			

Table 2:- One way ANOVA table.**Post Hoc Intergroup Comparison**

	Mean difference	P value	Significance
Group I vs Group II	-.10000	.724	NS
Group I vs Group III	.30000	.293	NS
Group I vs Group IV	-.20000	.481	NS
Group II vs Group III	.40000	.163	NS
Group II vs Group IV	-.10000	.724	NS
Group III vs Group IV	-.50000	.083	Significant

Table 3:- Intergroup comparison of obturation scores between the groups using CBCT.**Graph 1:-** Bar diagram showing presence and absence of voids.

When the void evaluation was done on CBCT, in the three groups (Group I, Group II and Group III) 100 percent of the samples were having voids present whereas in the Group IV 90 percent of the samples were having voids present.

Discussion:-

An ideal filling technique should assure complete filling of the canal, without overfill and with minimal or no voids. Overfilled canals lead to mild foreign body reaction and a risk of deflection of succedaneous tooth. The success rate of root canal is primarily depends upon the operators manual dexterity. ⁸The mixing technique of the obturation

material and the technique used for obturation also significantly influence the success rate.⁹ There are many obturation technique are available in literature .

A 3D seal of the root canal system through obturation hinders microleakage between the root canal and the periapical tissues thus depriving any surviving microorganism of nutrient and prevent toxic bacterial products from entering the periapical tissues.¹⁰ Furthermore, the technique should assure complete filling without spilling of the material periapically with minimal or no voids. There are various techniques available to fill the pulpectomized canals of primary teeth are available in literature like plugger, local anesthetic syringe, lentulo spiral, tuberculin syringe, NaviTip syringe , endodontic pressure syringe etc ¹⁰.

The plugger technique basically involves carrying thick consistency of material into the chamber with a plastic instrument or a lentulo and packing it into the canal with root canal plugger or lentulo, which is followed by pushing the material into the canal using a cotton pellet held in cotton pliers acting as a piston within the pulp chamber. The technique appears simple, but remains difficult to master ¹⁰.

The incremental filling technique was developed by Gould in 1972.⁴ Canal size plugger with stopper was used to place thick zinc oxide eugenol paste inside the canal. Length of the endodontic plugger equaled the predetermined root canal length minus 2 mm. Additional increments of 2-mm blocks were added until the canal was filled to the cervical area.⁴

To confirm the best, various studies have investigated different filling techniques in vivo and in vitro. Radiographs were assessed for the presence of minor voids and were graded as “presence” or “absence” of voids. Most commonly used method to confirm filling quality is the use of a postoperative radiograph which may be conventional radiographs¹¹. Apart from these, different methods were employed to check for the quality of root filling such as radioisotope, dye penetration, fluid filtration, bacterial leakage, microscopic analysis, clearing techniques, and microcomputerized tomography (CT). However, studies show that these methods have certain drawbacks.¹⁰

The revolutionary invention in the dentomaxillofacial imaging is the use of cone beam CT (CBCT) ,a nondestructive technology provides 3D interpretation of the specimen which has made many works simpler.¹⁰ It gives 3D volume measurements in a noninvasive manner. Thus, there is no loss of material and it could be used for further research.¹² Although micro or spiral CT scan has been used for the volumetric evaluation of obturation materials in primary teeth, the CBCT has various advantages over spiral CT, such as lower effective radiation doses, lower costs, fewer space requirements, easier image acquisition, and interactive display modes such as multiplanar reconstruction and the specimen can be used for the future research¹⁰. An extensive literature review shows that less studies have being performed to evaluate the efficiency of different obturation techniques in primary teeth using CBCT. Furthermore, assessments which compared different obturation techniques were performed either on permanent teeth or compared two or three techniques on deciduous anterior teeth¹⁰. Hence, to fill the gap in our knowledge, this study was designed wherein to evaluate four different obturation techniques were compared with the help of CBCT.

Total of 40 samples were selected.A sample size of 10 samples each for a group were selected after confirming statistical validity for the study. Similar studies were done by Nagarathna, C et al (2017)¹³ ,Sijeria P,et al (2018)¹⁴ and used same sample size.

The root canal therapy technique in this study was carried out on all teeth by a single operator. A study design with a single operator offers the advantage of consistent and reproducible technique.³

In our study, we preferred use of ZOE as a material of choice because of easy availability and cost-effectiveness as compared to any other filling material used for the purpose, though any filling material with desired physical properties and biologic behavior can be used using this technique.¹⁵ As it is the most commonly used root canal filling material for primary teeth and many investigations has assessed its performance in past. Also the material can be easily obtained and cost effective as compared with other materials. The ZOE has been used by Bhandari et al(2012)⁸ ,Sijeria P et al(2018)¹⁴ when obturation techniques were compared.

An acceptable obturation techniques is one which shows optimal fills along with least number of voids .In this study the standardization is maintained. Similar studies were done by Omar A et al(2005)¹⁵ , Romero O T (2011)¹⁶ , R.

Grover,(2013)⁶, Umapathy Thimmegowda(2021)¹⁷.By using a common biomechanical procedure , and obturating material of same radioopaque and consistency to avoid variability in the results.

In present study the obturation quality was assessed by Coll and Sadrian criteria (1996)which is underfilled (score 1), optimally filled (score 2), and overfilled (score 3) canals along with presence and absence of voids¹. Many studies assessed the above criteria to compare the different obturation techniques some of the studies are Akhil E. J. (2018)⁷ using DIOR and CBCT.

Sijeria P,et al (2018)¹⁴also used CBCT ,Deveaux et al.,(2000)¹⁸used conventional radiography to assess the quality of obturation.

In the present study majority of the canals obturated with Pastinject showed optimal filling, which might be accredited to the fact that a standardised procedure was followed, keeping Pastinject 1 mm short of the working length. Success of the technique can also be attributed to the fact that Pastinject is a specially designed paste carrier with flattened blades, which improves material placement into root canal, causing a lower occurrence of underfilled and overfilled canals [Deveaux et al., 2000]¹⁸. This can be correlated with the study by Oztan et al. [2002]¹⁹, in which they compared two different carriers for intracanal placement of calcium hydroxide. The results showed that canals obturated with the Lentulo spiral were short of the apex by more than 2 mm, whereas the canals obturated with Pastinject were either at the apex or only 1 to 2 mm short.it concluded that pastinject is the best⁶

In the present study highest number of overfilled canals was observed in local anaesthetic syringe . According to Memarpour et al.(2013)²⁰, the quality of root canal filling with the local anesthetic syringe was inferior to that of the lentulospiral and NaviTip groups. Similar results was obtained Peters et al.(1996)²¹ for local anaesthetic syringe. Limited flexibility , thicker tip of the needle and excessive pressure leads to overfilling of canals

In the present study maximum number of underfilled canals were seen in endodontic pressure syringe .When comparison of lentulo spiral was done with pressure syringe by Greenberg; lentulo spiral gave better results. Ayrald et al (1987)²² also gave similar results along with Bawazir and Salama(2006)¹⁵. Using of endodontic pressure syringe is technique sensitive. According to Kalaskar RR(2021)²³ removing and reinserting the syringe repeatedly decreases filling quality .

In the present study maximum number of voids were seen in endodontic pressure syringe. According to Krakow et al.(1965)²⁴ difficulties in placing the rubber stop correctly and removing the needle (because of the need to refill the hub of the syringe several times during the procedure) may lead the clinician to remove and reinsert the syringe repeatedly, which, in turn, may displace the paste, create voids, and thus decrease filling quality. Memarpour et al.(2013)²⁰found the highest frequency of voids (87%) with pressure syringe and packing groups.

Similar review was given by Kalaskar RR(2021)²³ and also the need to clean the syringe immediately after use makes this method more complex and time consuming.

According to Grover et⁶ al the highest number of overfilled canals was observed with pressure syringe when comparing with lentulospirals , past inject and bidirectional spiral (Subba et al, 1997²⁰). Memarpour et al found that highest frequency of voids with pressure syringe in his study²⁰.

In the present study quality of filling was checked using voids and were interpreted three dimensionally using CBCT. According to Nagaveni et al(2017)¹⁰ CBCT showed clear 3D view of obturation in root canal. Hence in the present study, the quality of root canal obturation with the pastinject was best followed by lentulospirals, local anesthetic syringe group and endodontic pressure syringe respectively. Pastinject showed maximum number of optimal filled canals and least number of voids.In a study conducted by Grover et al(2013)⁶, it was concluded that among lentulospirals, bi-directional spiral, pastinject and pressure syringe, the pastinject technique has proved to be the most effective, yielding a higher number of optimally filled canals and minimal voids, combined with easier placement of the material into the canals. Similar studies done by Guelmann et al.(2002)²⁵,and Grover et al.(2013)⁶, showed result same that of the present study. The results showed that canals obturated with the Lentulo spiral were short of the apex by more than 2 mm, whereas the canals obturated with Pastinject were either at the apex or only 1 to 2 mm short.⁶Lentulo spiral was only second to pastinject in filling the canal with calcium hydroxide as shown by Deveaux et al.(2000)¹⁸ and Oztan et al.(2002)¹⁹

Therefore in the present study it is found that pastinject showed better results in terms of optimal filling and minimal voids. The present in vitro study is limited to single rooted teeth with lesser sample size and moreover the obturation methods are technique sensitive. So further studies are required to evaluate the obturation quality by different techniques.

Conclusion:-

Within the limitations of this in vitro study it is found that: -

1. Pastinject showed the best obturation efficacy in terms of optimal filling and minimum voids followed by lentulo spirals, LA syringe, Endodontic pressure syringe respectively.
2. Endodontic pressure syringe showed the least efficacy in obturation quality among pastinject, lentulo spirals, LA syringe

Pastinject technique of obturation proved to be the best in terms of optimal filling and less number of voids. Thus it can be recommended as better alternative to other obturation technique used in this study.

References:-

1. Vashista K, Sandhu M, Sachdev V. Comparative Evaluation of Obturating Techniques in Primary Teeth: An in vivo Study. *Int J Clin Pediatr Dent* 2015;8(3):176-180
2. Rajshaker S, Mallineni SK, Nuvvula S. Obturating Materials Used for Pulpectomy in Primary Teeth- A Mini Review. *J Dent Craniofac Res*(2018) Vol.3 No.1: 3.
3. Gandhi M, Tandon S, Vijay A, Kalia G, Rathore K. Clinical assessment of various obturating techniques in primary teeth a comparative study. *J. Clin Diagn Res* .2017 ; 11(7)Z C48-ZC51
4. Chavhan DP, Somvanshi DY, Kumar DS, Niswade D, Sajjanar DA, Rojekar D, Awari D, Deo D. Different obturating techniques used in primary teeth: a review. *European Journal of Molecular & Clinical Medicine*. 2021 Mar 15;8(3):958-65.
5. Gupta S, Das G. Clinical and radiographic evaluation of zinc oxide eugenol and metapex in root canal treatment of primary teeth. *Journal of Indian Society of Pedodontics and Preventive Dentistry*. 2011 Jul 1;29(3):222
6. Grover R, Mehra M, Pandit IK, Srivastava N, Gugnani N, Gupta M. Clinical efficacy of various root canal obturating methods in primary teeth: a comparative study. *European journal of paediatric dentistry*. 2013 Jun 1;14(2):104-8.
7. Akhil JE, Prashant B, Shashibushan KK. Comparative evaluation of three obturation techniques in primary incisors using digital intra-oral receptor and CBCT—an in vitro study. *Clinical Oral Investigations*. 2019 Feb;23(2):689-96.
8. Bhandari SK, Prajapati U. Root canal obturation of primary teeth: Disposable injection technique. *Journal of Indian Society of Pedodontics and Preventive Dentistry*. 2012 Jan 1;30(1):13.
9. Bawazir OA, Salama FS. Clinical evaluation of root canal obturation methods in primary teeth. *Pediatric dentistry*. 2006 Jan 1;28(1):39-47.
10. Nagaveni NB, Yadav S, Poornima P, Bharath KP, Mathew MG, Naveen Kumar PG. Volumetric evaluation of various obturation techniques in primary teeth using cone beam computed tomography – An in vitro study. *J Indian Soc Pedod Prev Dent* 2017;35:244-8.
11. Aminabadi NA, Asl Aminabadi N, Jamali Z, Shirazi S. Primary tooth pulpectomy overfilling by different placement techniques: A systematic review and meta-analysis. *J Dent Res Dent Clin Dent Prospects*. 2020 Fall;14(4):250-261.
12. Duarte ML, Pepino JC, Sancias MC, Moreira JP, Neves AD, Pintor AV, Primo LG. Reliability of Two Methods of Evaluation of the Apical Limit of Obturation of Root Canals of Primary Teeth: A Pilot Study. *Pesquisa Brasileira em Odontopediatria e Clínica Integrada*. 2020 May 29;20.
13. Nagarathna C, Veena R. Revisit of endodontic pressure syringe procedures in ne. *Int J of current research* 2017 Nov Vol 9 issue 11
14. Sijeria P, Bhartia R, Nanjunda Swamy KV, Kulkarni S, Singla S. Evaluation of root canal filling in primary teeth by volumetric analysis: In vitro study. *International Journal of Clinical Pediatric Dentistry*. 2018 Sep;11(5):386.
15. Bawazir OA, Salama FS. Clinical evaluation of root canal obturation methods in primary teeth. *Pediatric dentistry*. 2006 Jan 1;28(1):39-47.

16. Ochoa-Romero T, Mendez-Gonzalez V, Flores-Reyes H, Pozos-Guillen A. Comparison between rotary and manual techniques on duration of instrumentation and obturation times in primary teeth. *Journal of Clinical Pediatric Dentistry*. 2011 Jul 1;35(4):359-64.
17. Thimmegowda U, Thomas J. Comparison of Novel navitip Obturating Technique with Lentulospiral and Endodontic Plugger Techniques in Primary Teeth: A Randomized Clinical Trial. *Journal of South Asian Association of Pediatric Dentistry*. 2021;4(2).
18. Deveaux E, Dufour D, Boniface B. Five methods of calcium hydroxide intracanal placement: an in vitro evaluation. *Oral Surg Oral Med Oral Pathol Oral Radiol Endod*. 2000;89(3):349–55.
19. Öztan MD, Akman A, Dalat D. Intracanal placement of calcium hydroxide: a comparison of two different mixtures and carriers. *Oral Surgery, Oral Medicine, Oral Pathology, Oral Radiology, and Endodontology*. 2002 Jul 1;94(1):93-7.
20. Memarpour M, Fijan S, Asgary S, Keikhaee M. Calcium-Enriched Mixture Pulpotomy of Primary Molar Teeth with Irreversible Pulpitis. A Clinical Study. *Open Dent J*. 2016 Mar 7;10:43-9.
21. Peters LB, Wesselink PR. Periapical healing of endodontically treated teeth in one and two visits obturated in the presence or absence of detectable microorganisms. *International endodontic journal*. 1996 Aug 1;35(8):660-7.
22. Aylard SR, Johnson R. Assessment of filling techniques for primary teeth. *Pediatr Dent*. 1987 Sep 1;9(3):195-8.
23. Kalaskar R, Thosar N, Balasubramanian S, Kalaskar A. Obturation Techniques in Primary Teeth: A Systematic Review. *Annals of the Romanian Society for Cell Biology*. 2021 Aug 1;25(6):18773-86.
24. Berk H, Krakow AA. The endodontic pressure syringe. *CDS review*. 1975 Sep;68(9):21-4
25. Guelmann M, mceachern M, Turner C. Pulpectomies in primary incisors using three delivery systems: an in vitro study. *J Clin Paediatr Dent*. 2004;28:323–26.