



Journal Homepage: - [www.journalijar.com](http://www.journalijar.com)

## INTERNATIONAL JOURNAL OF ADVANCED RESEARCH (IJAR)

Article DOI: 10.21474/IJAR01/13734

DOI URL: <http://dx.doi.org/10.21474/IJAR01/13734>



### RESEARCH ARTICLE

#### MULTIMODAL IMAGING OF CORNEAL NEOVESSELS: OCT ANGIOGRAPHY IN COMPARISON TO FLUORESCIN ANGIOGRAPHY ON 10 EYES AND REVIEW OF THE LITERATURE.

Younes Akannour, Tazi Habiba, Louai Serghini, El Hassan Abdallah and Berraho Amina

Establishment: Specialty Hospital, Department B of Ophthalmology, Rabat, Morocco.

#### Manuscript Info

##### Manuscript History

Received: 15 September 2021

Final Accepted: 17 October 2021

Published: November 2021

##### Key words:-

Corneal Neovessels, OCT Angiography, Fluorescein Angiography, Cornea, Diffusion

#### Abstract

**Introduction:** The use of OCT angiography for the analysis of neovessels of the ocular surface is currently at the experimental stage. Through this work we evaluate the benefits of OCTA in the detection of corneal neovessels, their depth and surface, the signs suggestive of activity / quiescence in comparison to fluorescein angiography.

**Materials And Methods:** 10 patients (10 eyes) with corneal neovessels (CNV) were prospectively recruited to Ophthalmology B at the Rabat Specialty Hospital between June and September 2019. All patients received OCT A fluorescein angiography (AF) at two-week intervals.

**Results:** The results of the OCT A matched the AF data by showing immature neovessel (NV) characteristics for the early-diffusing NVs, allowing the study of the structure : trunk, numbers of segments, and fractal divisions, the existence of apical loop. As well as the detection of the flow level, exudative phenomena and associated lesions in high resolution OCT B.

**Discussion:** Few studies have evaluated the OCTA in the evaluation of NVC, the published articles analyze the feasibility and reproducibility of this technique. Our initial analyzes suggest that scans provide better penetration and resolution of NVCs, but this requires direct comparative studies between OCTA systems used to scan the same eyes. The learning curve seemed fast for this technique.

**Conclusion :** The evaluation of antiangiogenic treatments and the risk of graft rejection, it should be noted when interpreting OCTA scans of the anterior segment that artifacts may appear in dense scars areas in addition to motion artifacts. Future software enhancements and optimization for anterior segment acquisition may reduce these artifacts even more and improve the resolution of the image.

Copy Right, IJAR, 2021,. All rights reserved.

#### Introduction:-

The cornea is normally an avascular tissue maintained by a dynamic balance between pro and anti-angiogenic factors and the inhibition of immunological and inflammatory reactions.

Many inflammatory, infectious, degenerative and traumatic pathologies can destabilize this balance and cause corneal neovascularization.

**Corresponding Author:- Younes Akannour**

Address:- Establishment: Specialty Hospital, Department B of Ophthalmology, Rabat, Morocco.

The use of OCT angiography to analyze neovessels of the ocular surface is currently under experimental procedures, eased by new and developed processors.

This work allows to evaluate the benefits of OCTA, a non-invasive examination with a quick acquisition concerning corneal neovessels detection, their depth and surface, signs suggesting activity/quiescence, compared to fluorescein angiography to guide treatments indications and assess its efficiency.

### Patients And Methods:-

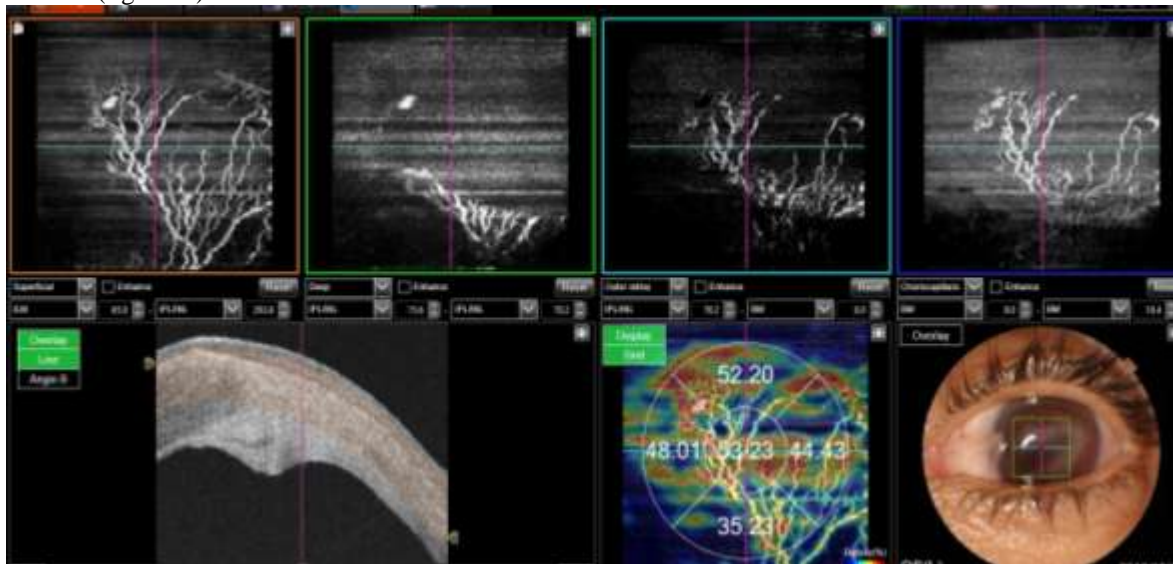
10 patients (10 eyes) with corneal neovessels clinically clear by biomicroscopy were prospectively admitted to the Ophthalmology B department in specialities hospital of RABAT from June to September 2019.

Only one eye was explored for each patient.

#### All patients got :

OCT A, fluorescein angiography two weeks apart.

-OCT A (figure 1 ):



**Figure 1:-**

OCT A Examination report of the area of the neovascularization: the C scans automatically obtained show the segmentation set for a retinal examination (superficial capillary layer, deep layer, external retina, and choriocapillary) the slab was manually moved to get a complete visualization of the neovascular network located in the thickness of the stroma with progressive deepening as the neovessel approaches the axis (orange interval on the B scan) between 65  $\mu\text{m}$  from the surface and 293  $\mu\text{m}$ ]. The neovessel is deeper than when using the slit lamp, the analysis is then hindered by the corneal opacity.]

The high-resolution B Scan is used to assess corneal thickening, exudative phenomena and an accurate topography of lesions.

The colored board allows a semi-quantitative analysis of the vascular flow detected, hot colors show a high flux density designating an active neovessel.

The device used is a Swept Source DRI OCT (Triton+ Topcon, Tokyo, Japan) with a 1050 nm wavelength .

We used the OCT angiography to get scans of 3mm x 3mm with a speed of 100000 A scans per second, an axial resolution of 8  $\mu\text{m}$  and lateral resolution of 20  $\mu\text{m}$ , without the use of the front segment adaptation lens.

We deactivated the Eye tracking and backlighting function with manual adjustment of the XYZ axis and focal length

The frontal OCT images were interrelated with the depth of the corneal neovascularization with manual segmentation adjustment.

The AF was performed using a Zeiss device.

With an injection into a peripheral vein (bend of the elbow ) of 3 ml of fluorescein 10% with acquisition every 3 seconds during the first 5 minutes and a late time at 10 and 15 min.

#### Analysis of the images:

The OCT A and Angio-fluo images were ranked independently for angio-fluo appearance and staining and neovascular aspect in OCT A.

The parameters analysed are:

- The diameter,
- branching, tortuosity and depth.

For AF: the period before the ocurrence of fluorescence , the presence of leakage and the delay of its appearance: early/late.

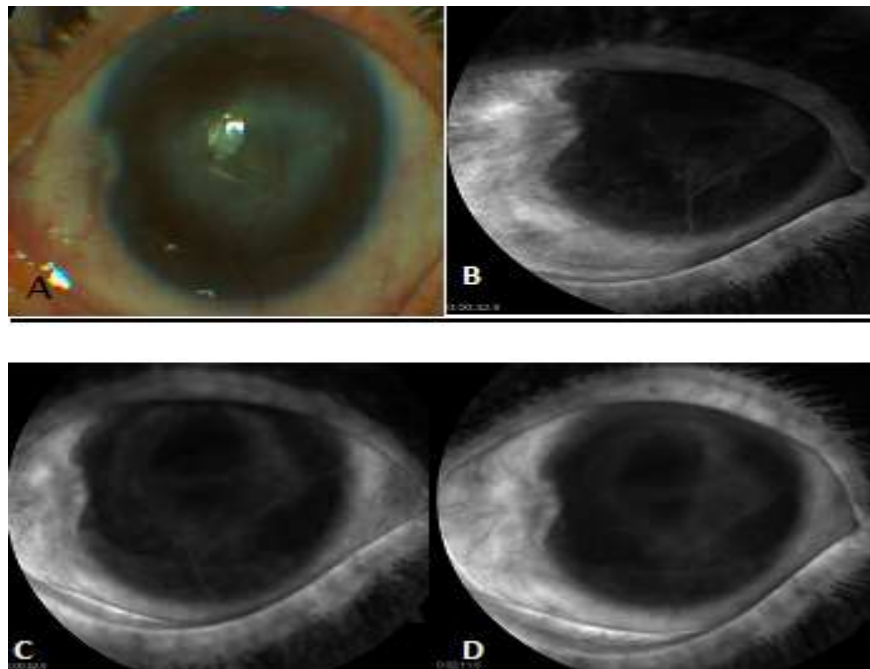
#### Results:-

10 patients (10 eyes) were included in the study, the age of our patients ranged from 16 to 62 years, 5 patients had sequelae of bacterial keratitis, 4 patients had NVC in a context of herpes and 1 patient had a continuing corneal wound.

The progress delay was less than 1 month for 4 patients, more than 6 months for 6 patients.

A patient was on bevacizumab as eye drops.

At angiography, the average delay for the appearance of the neovessel was 31 S, the diffusion showed on average at 38 S (4 min for the patient treated). Neonatal vessels that have been evolving for less than a month showed an early diffusion around 30 S. (Figure 2)



**Figure 2:-**

Slit Lamp and Corneal Fluorescein Angiography OG image

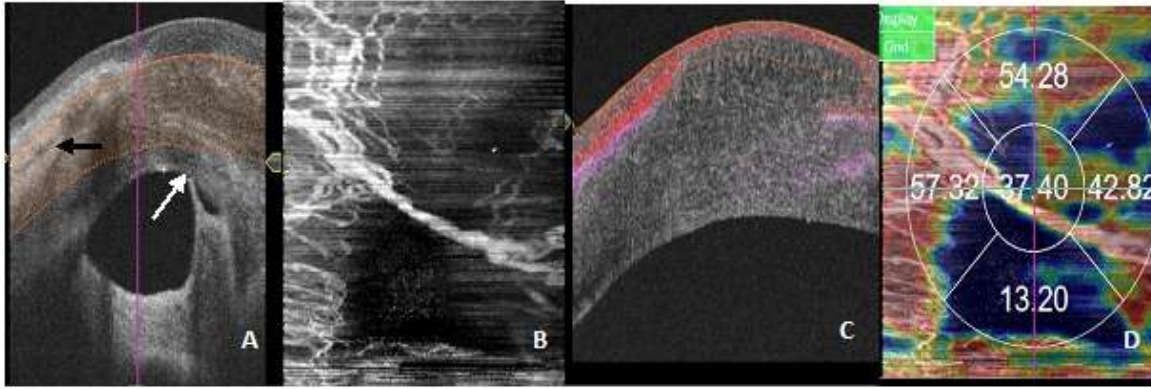
A:Central corneal opacity , superficial neovessels going from 6h and extending to the centre.

B:Ramifications and diffusion detected at 32 S.

C, D: enhancement of the diffusion making the appreciation of the neovessel impossible.

Image acquisition and report analysis in OCT A required manual adaptation, with an average acquisition time of 6 Seconds.

The results of the OCT A corresponded to the AF data by showing features of immature neovessels for early diffusing neovessels, allowing the study of the structure: trunk, number of segments and fractal divisions, the presence of an apical loop. (Figure 3)

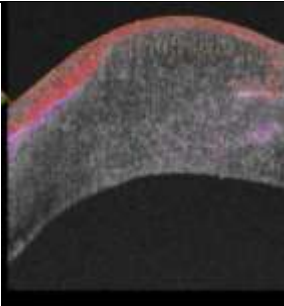
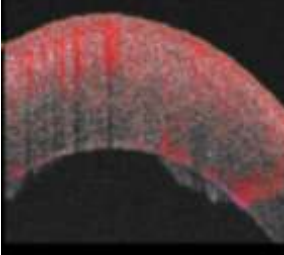


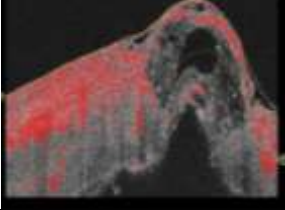
**Figure 3:-**

A: B scan showing an overall thickening of the basal cornea with an adherent leucoma ( white arrow) and perivascular exudation ( black arrow) the neovessel is visible with a slab starting at 184  $\mu\text{m}$  from the surface and extending at 577  $\mu\text{m}$ . B: C neonatal scan with a larger trunk than in angiography and the detection of a large flow superficially in C as well as at the the limbic vessels as certified by the color map in D

The depth of the neovessels is studied on the B scan with flow detection enabling to consider a neovessel as superficial if the flow detection is at the epithelium or the anterior third of the stroma and deep if the flow is in the center or third back of the stroma. (Table 1).

**Table:**

Patient	Location of the Neovessel	Image B scan associated to the flow detection
2	Superficial ( 1/3 anterior)	
3	Deep (average parity )	

4	Deep (middle part and 1/3 posterior)	
---	--------------------------------------	---

**Table 1:-** Example of Neovascular Flow Level Detection.

### Discussion:-

The corneal neovessels occurs due to a cascade of inflammatory reactions that lead to the release of angiogenic agents that promote the formation of nvc.

To better assess NVC, Easty and Bron [1] obtained AF NVC images of 250 patients.

They could not point out a specific shape in the abnormal vascular system of the cornea and struggled to differentiate the arterial and venous phases, as the flow was quick in addition to the presence of several vascular layers in the same cornea.

However, leaks in the corneal stroma were noticed with an inflammation and immaturity of the vessel. [1] as observed at our first four patients.

Easty and Bron [1] also described the phenomenon of pseudo-fluorescence and apical leakage observed in the case of two of our patients.

In a recent study, Anije et al. Find an average time of the appearance of fluorescein of 20 +/- 7 seconds after intravenous injection, regardless of the degree of maturity of the neovessels [2].

In our study it is 31 s. Fluorescein tends to diffuse significantly out of the neovessels disturbing their precise delineation.

The average time for the occurrence of the diffusion that begins at the neovessels apex is 41 s. In our study it's around 38 seconds with a diffusion at 4 min for patient 8. However, the apical vascular diffusion allows to evaluate the maturity of the neonatal vessels and the degree of inflammatory activity in the corneal tissue.

Indeed, the earlier the diffusion is (around 30 seconds) the more immature the neovessels are, which is indicative of early and inflammatory stages of keratitis (patient 4).

The more mature and stabilized the neovessels are, for example after the healing of a keratitis, the later the diffusion is (around 50 seconds: patients: 3, 8, and absence of diffusion for patient: 5 [3].

Few studies have assessed OCTA in the NVC evaluation, the articles published evaluate the practicability and reproducibility of this technique.

Our initial analyses suggest that scans provide better NVC penetration and resolution, but this requires direct comparative studies between OCTA systems used to scan the same eyes.

The reports analysis requires manual adaptation of the slabs, these lines are not suitable for corneal curvature.

The presence of large fractal divisions, large diameter and apical loops are criteria of activity.

The flow representing the neovascularization in B scan is dense, uniform forming a clod.

Monitoring can be done subjectively on the aspect and flow detected or objectively by evaluating the neovascular surface through external software.

Cai Y et al [4] studied a total of 12 OCTA (Angio Vue) scans in three eyes with corneal vascularization, comparing images before and 3 months after treatment.

They found that OCTA was able to detect a significant decrease in vascularization area in all eyes: for thin needle diathermy (48.7-41.5%,  $P = 0.048$ ), sub-conjunctival bevacizumab (45.7-38.5%,  $P = 0.015$ ) and systemic steroid therapy after transplant rejection (38.1-32.2%,  $P = 0.003$ ).

We recognize the limitations of our preliminary study: An extended prospective study of different corneal pathologies and comparing with other systems OCTA, or ICGA and a comparison of before and after treatment images.

Nevertheless, we offer promising results that suggest that this rapid and non-invasive OCTA system could be further developed for corneal vascularization imaging, which could help to better understand its role in various corneal, conjunctival and scleral diseases.

### **Conclusion:-**

This innovative technique is promising for the delineation of the NVC and the anterior segment, the evaluation of antiangiogenic treatments and the risk of graft rejection, it should be noted when interpreting OCTA scans of the anterior segment that artifacts may appear in dense scars areas in addition to motion artifacts.

Future software enhancements and optimization for anterior segment acquisition may reduce these artifacts even more and improve the resolution of the image.

### **Références:-**

1. Easty DL, Bron AJ. Fluorescein angiography of the anterior segment. Its value in corneal disease. *Br J Ophthalmol*. 1971; 55: 671-682.
2. Anijeet D.R., Zheng Y., Tey A., Hodson M., Sueke H., Kaye S.B. Imaging and evaluation of corneal vascularization using fluorescein and indocyanine green angiography *Invest Ophthalmol Vis Sci* 2012 ; 53 : 650-658 .
3. Kirwan R.P., Zheng Y., Tey A., Anijeet D., Sueke H., Kaye S.B. Quantifying changes in corneal neovascularization using fluorescein and indocyanine green angiography *Am J Ophthalmol* 2012 ; 154 : 850-858.
4. Cai Y , Alio Del Barrio JL , Wilkins MR, Ang M, 4Angiographie par tomographie en cohérence optique série pour la vascularisation cornéenne. *Graefes Arch Clin Exp Ophthalmol*. 2017 Jan; 255 (1): 135-139. doi: 10.1007 / s00417-016-3505-9/.