



CODEN (USA): IAJPBB

ISSN: 2349-7750

## INDO AMERICAN JOURNAL OF PHARMACEUTICAL SCIENCES

Available online at: <http://www.iajps.com>

Research Article

### HISTOLOGICAL PATTERN OF OVARIAN TUMORS IN REPRODUCTIVE AGE GROUPS

Dr. Naila Qureshi<sup>\*1</sup>, Dr. Adnan Ahmed<sup>2</sup>, Dr. Fareen Memon<sup>3</sup>

<sup>1</sup> MBBS, FCPS, Isra University Hospital Hyderabad.

<sup>2</sup> MBBS, FCPS, Assistant Professor, Radiology department, Liaquat University of Medical and Health Sciences, Jamshoro (LUMHS)

<sup>3</sup> MBBS, DGO, MS, Assistant Professor, Indus Medical College, TM KHAN

Received: 02 March 2017

Accepted: 10 March 2017

Published: 28 March 2017

**Abstract:**

**OBJECTIVES:** To detect the frequency of histological pattern of ovarian tumor in reproductive age group in a tertiary care Hospital.

**SUBJECTS AND METHODS:** This cross sectional descriptive study had been carried out at dept. of obstetrics and gynecology at Isra University Hospital Hyderabad. Total 106 patients with following presenting complaint of ovarian tumors like abdominal mass, bloating, discomfort, pain or pelvic swelling and ultrasound showed ovarian mass greater than 4 cm were included in this study. Ultrasound finding was recorded. Specimen for histopathological examination was sent to pathology department. All the data was recorded on the predesigned proforma.

**Results:** The average age of the patients was  $34.57 \pm 6.2$  years. Frequency of histological pattern of ovarian tumor which was epithelial cell tumor was observed in 50% (53/106) cases followed by germ cell tumor 33.96% (36/106) and sex cord stromal tumor was 16.04% (17/106) cases.

**Conclusion:** Our interpretations as well as outcomes are proven as significant base line data about frequency & pattern of ovarian tumors in our area and it is concluded that exact histological analysis as well as staging is curatively & prognostic-ally valuably.

**Key Words:** Ovarian tumors, Malignancies, Histological pattern

**Corresponding Author:**

**Dr. Naila Qureshi,**

Address: E 169 Gulistan e Sajjad,

Jamshoro road Hyderabad.

Cell # 03332700192

Email: saedarain@yahoo.com

QR code



Please cite this article in press as Naila Qureshi et al, *Histological Pattern of Ovarian Tumors in Reproductive Age Groups*, Indo Am. J. P. Sci, 2017; 4(03).

**INTRODUCTION:**

Ovarian tumors are the most widespread malignancies worldwide which affects every age group [1]. Out of every gynecological malignancy challenge, ovarian tumors stand for the utmost. It is 2nd commonest diagnosed tumor of female genital system [2]. Ovarian tumors are of 3 major types; Germ cell, Epithelial ovarian, & Sex cord-stromal tumor. Ovarian tumor syndromes are unspecific moreover not easily distinguished from other conditions. Common indications are; gastro-intestinal indication & pain, abdominal swelling, fatigue, urinary symptoms, weight loss, sporadically abnormal-vaginal-bleeding, back-ache/Abdominal pain, energy insufficiency.

Their occurrence is rising worldwide. It's the fifth commonest tumor as well as fifth leading mortality causing malignancy in females make up to 50% cancers mortalities of women's genital tract [3]. It's frequently termed as "silent killer" as syndrome is generally not diagnosed before advanced stage. Worldwide, above 0.2 million females are likely to acquire ovarian malignancies [4]. Annually 0.1 million females expire as result of ovarian malignancy. In general the expected life span risk is 1:70 (1.4%) of females.<sup>5</sup> Amongst gynecological cancers it is unluckily being gradually more come across in Pakistan. By multicenter study regarding ovarian tumor-malignant incidence projected by PMRC ovarian cancer occurrence was 3.37 percent during 1973. in contrast to the Indian as well as western studies, ovarian malignancies were additional recurrent as compare to cervical malignancies.<sup>6</sup> Initial ovarian malignancy mass doesn't lead to evident indications and majority of the females are with advanced stage having poor diagnosis, Although intensive and intricate treatments are accessible.<sup>7</sup> The malignant/benign lesion diagnosis could be accomplished through bimanual examination & history. U/S is a standard analysis to diagnose ovarian pathology because it provides data concerning the consistency, origin, etc however ultimate diagnosis can be executed just via tissue biopsy.<sup>8</sup> This study will help us in finding the definite type of ovarian tumor confirmed on histopathological reporting in reproducing age groups, this can help in pre-operative counseling and management plan of patients at Isra university hospital Hyderabad

**MATERIAL AND METHODS:**

This cross sectional study carried out at obstetrics & gynecology department at Isra University Hospital Hyderabad. All patients in reproductive age group

from 20 to 49 years with any one or more of following presenting complaint of ovarian tumors like abdominal mass, bloating, discomfort, pain or pelvic swelling along with Ultrasound shows ovarian mass greater than 4 cm, were integrated in our study. All the cases more than 49 years of age and with previous history of ovarian tumor were excluded. Subject was selected through indoor/ outdoor from all units of gynae and Obstetric department of ISRA University Hospital Hyderabad. After obtaining brief history of duration of complaint and examination consent was taken. Ultrasound finding was recorded and biopsy was taken by a consultant with more than five years and assisted by researcher. Specimen for histopathological examination was sent to pathology department. All the data was recorded on the predesigned proforma e.g age, clinical finding, ultrasound findings and histopathological diagnosis. After collection of data the analyses were done via SPSS V.16.

**RESULTS:**

There were 106 patients with following presenting complaint of ovarian tumors like abdominal mass, bloating, discomfort, pain or pelvic swelling and ultrasound showed ovarian mass greater than 4 cm were included in this study. The average age of the patients was  $34.57 \pm 6.2$  years. Out of 106 women, 27(25.47%) were between 21 to 30 years of age, 63(59.43%) were 31 to 40 years age and 16(15.09%) were over 40 years age. Table:1

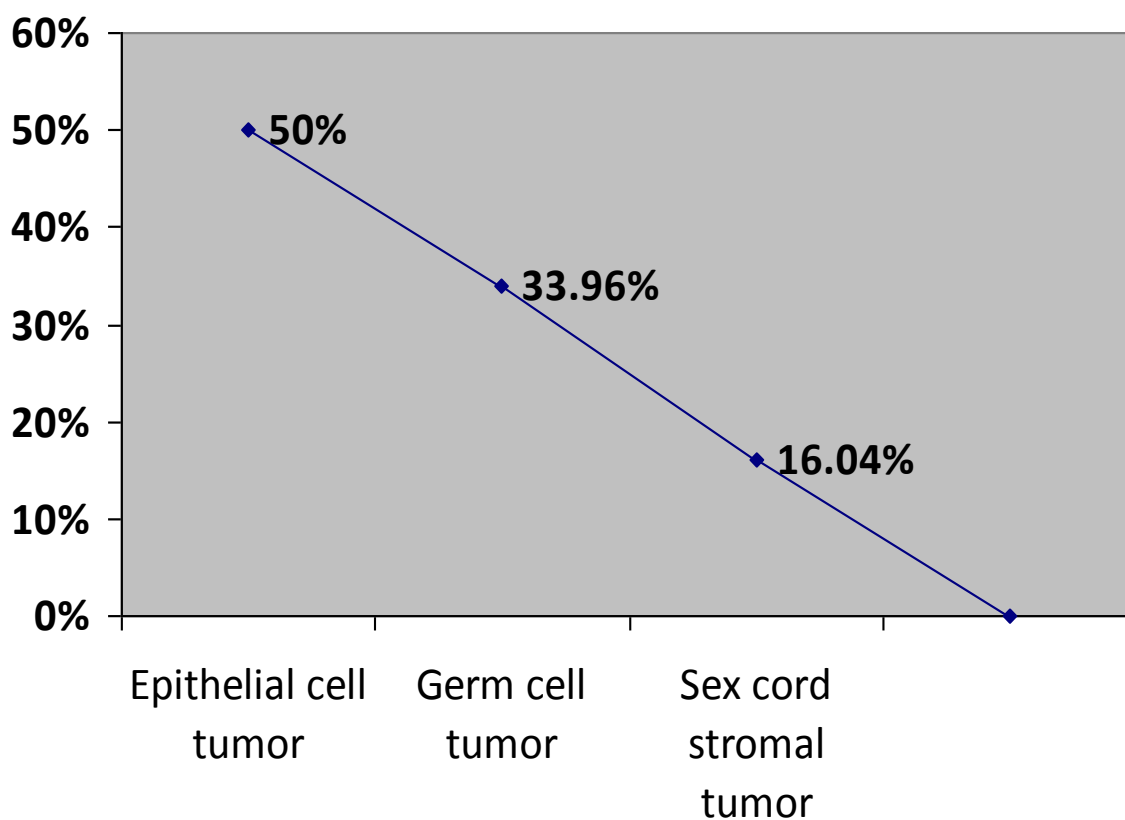
There were 61(57.55%) woman had primiparous and 45(42.45%) women had multiparous. Table:1  
Frequency of histological pattern of ovarian tumor is presented in (Fig 1) in which epithelial cell tumor was observed in 50% (53/106) cases followed by germ cell tumor 33.96% (36/106) and sex cord stromal tumor was 16.04% (17/106) cases. Fig: 1

Rate of epithelial cell tumor and sex cord stromal tumor were significantly high in elder age groups patients as compare to younger age group while rate of germ cell tumor was significantly high in younger age groups as compare to elder age women. Table:2  
Comparison of rate of pattern of ovarian tumor between parity groups in which rate of epithelial cell tumor was high in multiparous women as compare to primiparous while rate of germ cell was significantly high in primiparous women as compare to multiparous women. Table:3

Similarly rate of histological pattern of ovarian tumor was also observed with respect to duration of complain as shown in Table:4

**Table 1: Baseline Characteristics of the Patients n=106**

Characteristics	N. of patients/(%)
<b>Mean age (mean<math>\pm</math>SD)</b>	(34.57 $\pm$ 6.2)
<b>Age groups</b>	
21-30	27/(25.47%)
31-40	63/(59.43%)
< 40	16/(15.09%)
<b>Parity</b>	
Primi	45/(42.45%)
Multi	61/(57.52%)

**Fig: 1: Frequency of Histological Pattern of Ovarian Tumor n= 106**

**Table 2: Frequency of Histological Pattern of Ovarian Tumor with Respect to age n=106**

HISTOLOGY OF OVARIAN TUMOR	Age Groups (Years)			P- value
	21 to 30 Years n=27	31 to 40 Years n=63	>40 Years n=16	
EPITHELIAL CELL TUMOR	2(7.4%)	40(63.5%)	11(68.8%)	0.005
GERM CELL TUMOR	25(92.6%)	10(15.9%)	1(6.3%)	0.002
SEX CORD-STROMAL TUMOR	00	23(20.6%)	4(25%)	0.029

**Table 3: Frequency of histological pattern of ovarian Tumor with respect to parity**

HISTOLOGY OF OVARIAN TUMOR	Primiparous n=61	Multiparous n=45	P-Value
EPITHELIAL CELL TUMOR	21(34.4%)	32(71.1%)	0.005
GERM CELL TUMOR	28(45.9%)	8(17.8%)	0.003
SEX CORD-STROMAL TUMOR	12(19.7%)	5(11.1%)	0.23

**Table 4: Frequency of histological pattern of ovarian Tumor with respect to duration of complain**

HISTOLOGICAL PATTERN OF OVARIAN TUMOR	DURATION OF COMPLAIN (months)		P-Value
	≤4 months n=64	>4 months n=42	
EPITHELIAL CELL TUMOR	33(51.6%)	20(47.6%)	0.69
GERM CELL TUMOR	26(40.6%)	10(23.8%)	0.07
SEX CORD-STROMAL TUMOR	5(7.8%)	12(28.6%)	0.004

**DISCUSSION:**

Ovarian tumor is the 2nd commonest malignancy of female genital system as well as primary reason of mortality resulting from gynecologic cancer [9]. Ovarian malignancy comprise a multifaceted broad neoplasm spectrum concerning various histological identifications varying from connective & epithelial tissues, specialized hormone secretions to embryonal & germinal cells. Ovarian malignancy identification can be tricky because of various pathologic symptoms which can influence ovaries as well as present with alike radiologic & clinical symptoms. Know-how of age-specific & morphological characteristics can assist enhance the diagnosis [10]. In this study, most of the patients were above 40

years of age. Out of 106 women, 27(25.47%) were between 21 to 30 years of age, 63(59.43%) were 31 to 40 yrs age and 16(15.09%) were over 40 yrs age. average age of the patients was  $34.57 \pm 6.2$  years In a study done by Suresh Kumar Mandal[11], amongst 957 ovarian malignancy cases, at presentation median age was 35 years. Majority of benign malignancies took place from 20 to 40 yrs age, whereas cancer lesions presented normally from 41 to 50 yrs. Other investigators in alike studies emphasized that majority of ovarian malignancies (47.2%) are observed from 21 to 40 yrs, while most malignant cancers were (73.1%) over 40 yrs [12]. In other studies a greater median age for malignant lesions of 60 to 65 yrs was projected from western nations as

well as from western & southern India [13,14] With the raise in total quantity of older females, the consequence of ovarian malignancies for given age group is likely to be greater than before [14]. Sex cord stromal & malignant epithelial tumors were commonest following 50 yrs, though germ cell malignancies are further prevailing before 20 yrs age [15]. In this study, malignant epithelial malignancies were primarily in group of 31 to 40 yrs age. Though, a significant quantity of melanoma surface epithelial malignancies were as well observed in >40 Yrs.

Histological categorization of ovarian malignancies by WHO is based upon normal ovary histogenesis [16]. The most widespread malignant cancer within this series had been of surface epithelial malignancies (50%), after germ cell cancers (33.96%) and sex-cord stromal tumors (16.04%). This finding is alike the Shy et al [17] as well as Di et al findings [18]. Histologically, surface epithelial malignancies are most common. These malignancies involve 48.8% & 63.5% of the entire ovarian malignancies in various studies.[19,20] The foremost malignant tumors burden is in addition contributed by this group (93%) [14]. Likewise, in this study, surface epithelial malignancies contained 50% (53/1060) patients from every tumor.

Germ cell malignancy was 2nd foremost tumors group in this study (33.96%). The germ cell malignancies ratio varied in different studies from 23.9 to 42.2% [12,19]. Significantly greater quantity of germ cell malignancies was projected from South Africa. Outcomes with GCT including the most common of every ovarian neoplasm was observed in studies executed by Lucas et al [22] as well as Lancaster et al [21].

Sex Cord Stromal malignancies includes 5 to 8% of every OT however this study exhibited a slightly higher occurrence (16.04%)- prevalence which is contrary to the finding of Salvi V [23] (3.3%). Androgenic influence of malignancy was not observed in our study whereas it was observed in 100% of 34 patients projected by Roth et al [24].

### CONCLUSION:

Our Outcomes & observations proved to be helpful base line data concerning pattern & occurrence of ovarian malignancy in our area. In our study, Histology exposed that germ cell malignancies as well as surface epithelial malignancies together make up the huge majority of patients. Ovarian melanoma exhibits an incredible clinical challenge to radiotherapists, medical oncologists as well as gynecologists. It is detected with difficulty by laboratory/physical assessment; thus one has to rely on the microscopic structure of the malignancy for additional administration of ovarian malignancies.

An exact histological staging as well as diagnosis is prognostically & therapeutically significant.

### REFERENCES:

1. Baloch S, Khaskheli M, Malik AM, Sheeba A, Khushk IA. Clinical spectrum and management of ovarian tumours in young girls upto 20 years of age. J Ayub Med Coll Abbottabad. 2008;20(4):14-7.
2. Baloch S, Khaskheli M, Malik AM. Clinical spectrum and management of ovarian tumours in young girls upto 20 years of age. J Ayub Med Coll Abbottabad. 2008;20(4):14-7.
3. Iffat N, Saima M, Malik SS. Review of ovarian tumours. Ann King Edward Med Coll. 2001;7:180-2.
4. Koldjeski D, Kirpatrick MK, Swanson M, Evertt L, Brown S. Ovarian cancer early symptom patterns. Oncol Nurs Forum. 2003;30:927-33.
5. Goff BA, Mandel LS, Melancon CH, Muntz HG. Frequency of symptoms of ovarian cancer in women presenting to primary care clinics. JAMA. 2004;291:2705-12.
6. Panprom P, Lertkhachonsuk R. Outcome of ovarian cancer patients who underwent incomplete surgical staging. J Med Assoc Thai. 2008;91:1323-30.
7. Jamal S, Moghal S, Mamoon N, Musthaq S, Luqman M, Anwar M. The pattern of malignant tumors: tumour registry data analysis, AFIP, Rawalpindi, Pakistan (1992-2001). J Pak Med Assoc. 2006;56:359-62.
8. Gentry-Maharaj A, Menon U. Screening for ovarian cancer in the general population. Best Pract Res Clin Obstet Gynaecol. 2012;26:243-56.
9. Tortolero-Luna G, Mitchell MF. The epidemiology of ovarian cancer. J Cell Biochem Suppl. 1995;23:200-7.
10. Sutton CL, McKinney CD, Jones JE, Gay SB. Ovarian masses revisited: Radiologic and pathologic correlation. Radiographics. 1992;12:953-77.
11. Mondal SK, Banyopadhyay R, Nag DR, Roychowdhury S, Mondal PK, Sinha SK. Histologic pattern, bilaterality and clinical evaluation of 957 ovarian neoplasms: a 10-year study in a tertiary hospital of eastern India. J Can Res Ther. 2011;7:433-7.
12. Jha R, Karki S. Histological pattern of ovarian tumors and their age distribution. Nepal Med Coll J. 2008;10:81-5.
13. Murthy NS, Shalini S, Suman G, Pruthvish S, Mathew A. Changing trends in incidence of ovarian cancer - the Indian scenario. Asian Pac J Cancer Prev. 2009;10:1025-30.
14. Yancik R. Ovarian cancer. Age contrasts in incidence, histology, disease stage at diagnosis, and mortality. Cancer. 1993;71 Suppl 2:517-23.

15. Gilani MM, Behnamfar F, Zamani F, Zamani N. Frequency of different types ovarian cancer in Vali-e-Asr Hospital (Tehran University of Medical Sciences) 2001-2003. *Pak J Biol Sci.* 2007;10:3026-8.
16. Tavassoli FA, Devilee P, editors. Pathology and genetics of tumors of the breast and female genital tracts. Lyon: IARC Press; 2003. p. 114
17. Shy Y. Histological classification in 10,288 cases of ovarian malignant tumors in China. *Zhinghua Fu Chan Ke Za Zhi.* 2002 Feb;37(2):97-100.
18. Di Bonito L, Patriarca S, Delendi M, Alberico S. Ovarian tumours: anatomohistopathological contribution to their interpretation. *Eur J Gynaecol Oncol.* 1988;9(4):324-30.
19. Gupta N, Bisht D, Agarwal AK, Sharma VK. Retrospective and prospective study of ovarian tumours and tumour-like lesions. *Indian J Pathol Microbiol.* 2007;50:525-7.
20. Ahmad Z, Kayani N, Hasan SH, Muzaffar S, Gill MS. Histological pattern of ovarian neoplasma. *J Pak Med Assoc.* 2000;50:416-9.
21. Lancaster EJ, Muthuphei MN. Ovarian tumours in Africans: a study of 512 cases. *Cent Afr J Med.* 1995;41:245-8.
22. Lucas SB, Vella EJ. Ovarian tumors in Malawi - a histopathological study. *J Obstet Gynaecol East Cent Africa.* 1983 Sep;2(3):97-101.
23. Maheshwari V, Tyagi SP, Saxena K, Tyagi N, Sharma R, Aziz M, et al. Surface epithelial tumours of the ovary. *Indian J Pathol Microbiol.* 1994 Jan;37(1):75-85.
24. Roth LM, Anderson MC, Govani AD, Langley FA, Gowing NFC, Woodcock AS. Leydig cell tumors: clinicopathologic study of 34 cases. *Cancer.* 1981 Jul;48(1):187-97.