

 <p>ISSN NO. 2320-5407</p>	<p>Journal Homepage: - www.journalijar.com</p> <p>INTERNATIONAL JOURNAL OF ADVANCED RESEARCH (IJAR)</p> <p>Article DOI: 10.21474/IJAR01/10330 DOI URL: http://dx.doi.org/10.21474/IJAR01/10330</p>	 <p>INTERNATIONAL JOURNAL OF ADVANCED RESEARCH (IJAR) ISSN 2320-5407 Journal Homepage: http://www.journalijar.com Article DOI: 10.21474/IJAR01/10330</p>
---	--	--

RESEARCH ARTICLE

SIGMOID VOLVULUS ON PREGNANCY COMPLICATED BY FETAL DEATH IN UTERO

Cheikh Malaaynine M.F.¹, Rabbani K.¹, Lammat H.¹, Louzi A.¹, Finech B.¹, El. Mahfoudi A.², Asmouki H.², Aboufalah A.² and Soumani A.²

1. Department of General Surgery, University Hospital Center Mohamed VI, Marrakech, Morocco.
2. Department of Gyneco-Obstetric, University Hospital Center Mohamed VI, Marrakech, Morocco.

Manuscript Info

Manuscript History

Received: 25 November 2019

Final Accepted: 27 December 2019

Published: January 2020

Key words:-

Pregnancy, Sigmoid Volvulus, Surgical
Emergency

Abstract

Sigmoid volvulus in pregnancy is a very rare condition. Clinicians should have a high index of suspicion of this condition if they encounter a pregnant woman with symptoms suggestive of bowel obstruction. However incorrect diagnosis may be catastrophic, resulting in major complications, including fetal and maternal death. Here we report a case of a 30-year-old parturient with a sigmoid volvulus associated an in utero fetal death at 26 weeks of amenorrhea during labour.

Copy Right, IJAR, 2020,. All rights reserved.

Introduction:-

Sigmoid volvulus in pregnancy is a very rare entity which can be associated with extremely high rates of mortality and morbidity for both mother and fetus [1]. Incidence of occlusions digestive during pregnancy, reports in literature, varies between 1 case out of 66,343 and 1 case out of 1500. The sigmoid volvulus is the most common cause of bowel obstruction during Pregnancy after occlusions on bridges, representing 25 to 44% of cases [2].

The danger lies in the insidious nature of symptom development. Delay in presentation and diagnosis can result in bowel ischemia, which may require colectomy and formation of a stoma, and also put pregnancy in jeopardy [3]. Maternal complications include perforation, peritonitis, and sepsis. Fetal complications include preterm delivery, intrauterine death, and neonatal sepsis. A high index of suspicion and use of modern imaging modalities are required for achieving better results for both mother and fetus [4].

Case Presentation:

It's about a 30-year-old multiparty patient with no significant history, developing for 3 days an occlusive syndrome and abdominal pain, nausea, vomiting with no other associated signs; on a pregnancy of 26-week amenorrhea based on T1 ultrasound.

general examination showed a conscious and stable patient, with slight conjunctival discoloration, a distended abdomen with generalized tympanism and diffuse abdominal tenderness without abdominal contracture. The rectal bulb was empty at the rectal touch.

Abdominal x-ray showed a colic hydoaeric level (figure 1).

Corresponding Author:- Cheikh Malaaynine M.F

Address:- Department of General Surgery, University Hospital Center Mohamed VI, Marrakech, Morocco.

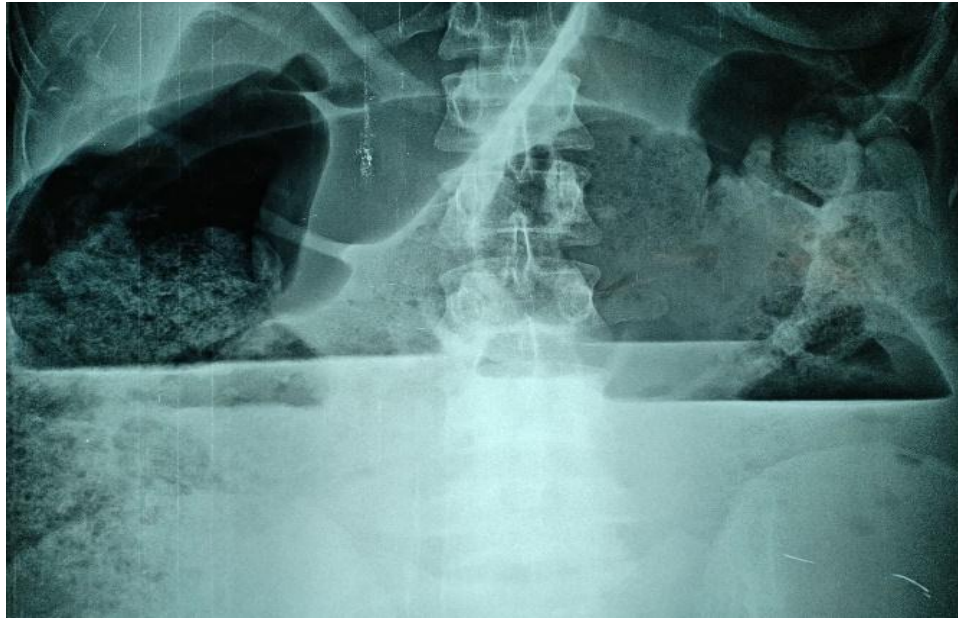


Fig 1:- A Colic Hydroaeric level, appearance in coffee bean.

Abdominal CT showed a sigmoid volvulus with signs of intestinal suffering: the intestinal wall appeared to be extremely thin and prone to perforation with peritoneal effusion on non-progressive pregnancy (Figure 2).

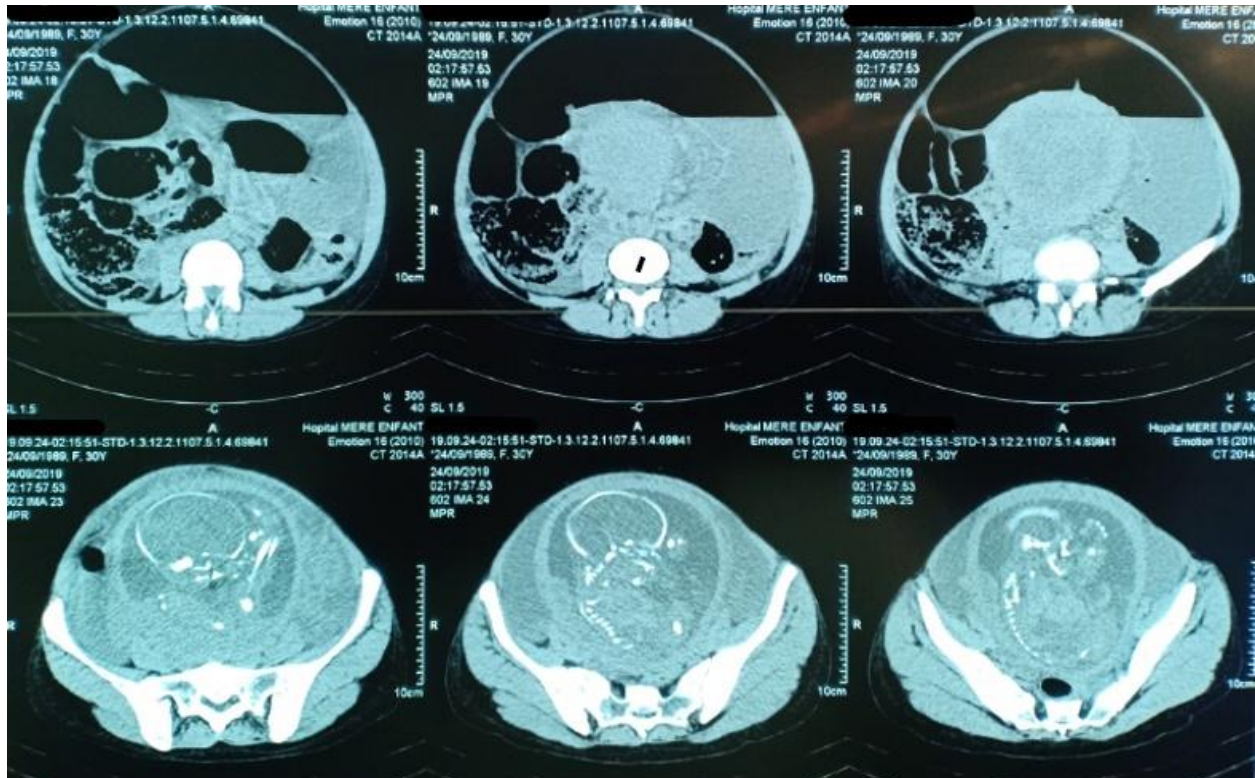


Fig 2:- Abdominal CT showed a sigmoid volvulus with signs of intestinal suffering: the intestinal wall appeared to be extremely thin and prone to perforation with peritoneal effusion on 26 AW non-progressive pregnancy.

Obstetrical exam revealed a fetal death in utero of 950g estimated fetal weight. The patient was in labour, the cervix dilatation attempted 1 cm, erased to 60%, a moving cephalic presentation, with a pocket of water intact. A low birth was performed with the extraction of a dead-born female weighing 980g (Figure 3).

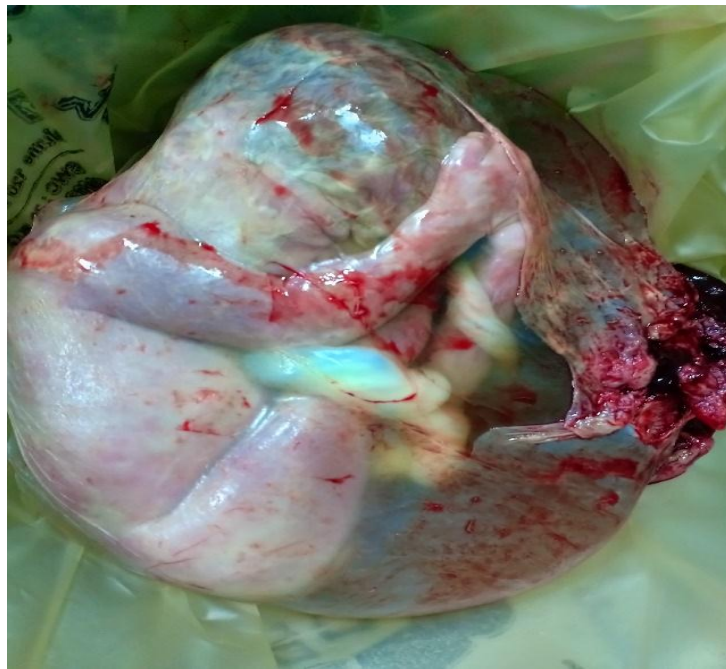


Fig 3:- spontaneous expulsion of a female stillborn weighing 980g.

Explorations showed a peritoneal haematous and suspicious of a great abundance effusion with an important distention of the colic frame in relation to a sigmoid volvulus, extensive necrosis of the entire sigmoid loop and a dolichosigmoid measuring 70cm (Figure 4).

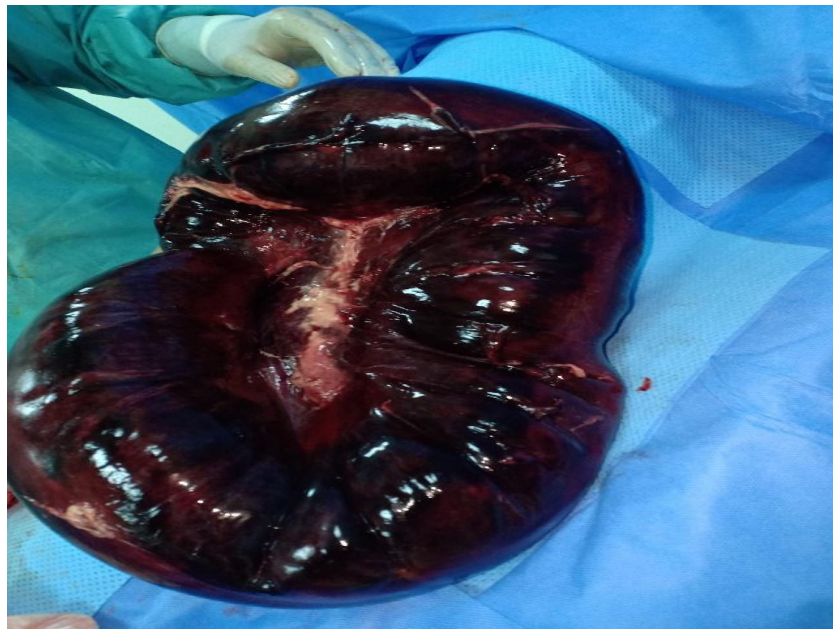


Fig 4:- Extensive necrosis of the sigmoidal loop.

Our gesture consisted in a devolution of the sigmoidal loop with sigmoidal resection up to the level of the recto-sigmoidal hinge and colostomy according to Hartmann (Figure 5). The post-operative and obstetrical suites were simple. The recovery of the continuity was realized three months after.

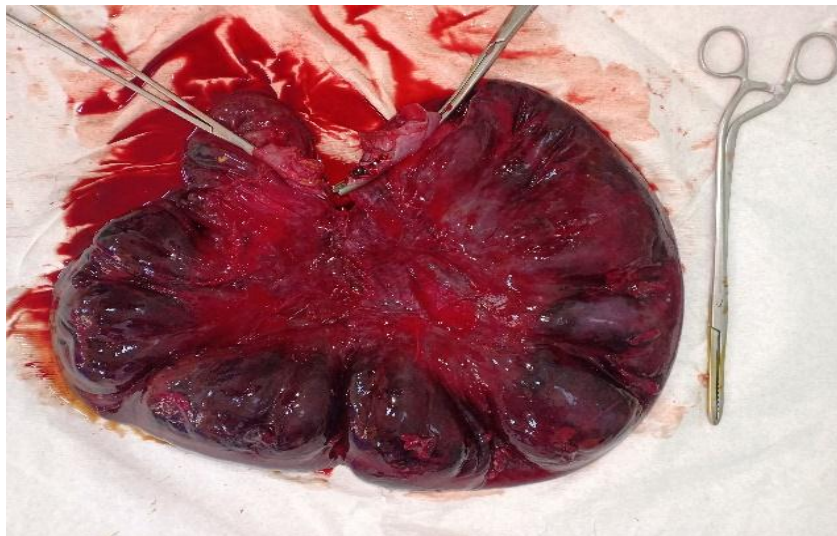

Fig 5:- part of the sigmoidal resection.

Discussion:-

In the United States, sigmoid volvulus (SV) is usually reported in institutionalized, debilitated, or chronically constipated patients who have long redundant sigmoid colons. A high incidence reported in Africa has been attributed to the high-fiber vegetable diet indigenous to that population [5].

Sigmoid volvulus in pregnancy is an extremely uncommon condition, with only 84 cases to have been reported in the English literature. Bowel obstruction in pregnancy varies from 1 in 1500 to 1 in 66,431 deliveries, and SV is the cause of 44% of the cases. A long sigmoid colon (dolichocolon) compressed by the enlarged gravid uterus can cause sigmoid volvulus. This might explain the increased incidence of SV in the third trimester of gestation [3, 4].

The diagnosis of SV in pregnancy is often delayed because the symptoms mimic typical pregnancy-associated complaints. The literature suggests to suspect the diagnosis of SV when a pregnant patient presents with abdominal distention, pain, and absolute constipation. The patient will vomit and not tolerate oral intake of food or water [4]. As there was pain and distention, but no vomiting, and additionally there were multiple episodes of diarrhea. While the obstruction was incomplete, the dilatation of the large intestine was quite marked, as revealed on the MRI scan and at laparotomy. Imaging options for the diagnosis of SV in pregnancy are controversial given the rarity of this condition in pregnancy. It is widely accepted that exposure of the pregnant patient to radiation should be avoided due to the danger of chromosomal mutations during the first two trimesters and the increased risk for hematological abnormalities such as leukemia in the third trimester. The safe radiation exposure limit is between 5 and 10 rad. Although the radiation dose of an abdominal CT scan is thought to be within this limit, many authors still believe that CT should be avoided. This was the reason we decided to proceed to MRI option, given that it combines diagnostic accuracy and is also considered to be safe for the fetus [6].

The management of SV in the pregnant patient involves aggressive fluid resuscitation, decompression of the proximal bowel and recognition of this entity as an acute surgical emergency [7]. The treatment options include endoscopic reduction of the volvulus and surgery. There are case reports indicating that endoscopy and decompression can have good results in the treatment of SV during pregnancy in cases where bowel necrosis or vascular occlusion has been ruled out. In the absence of peritoneal signs or mucosal ischemia, it would seem reasonable to attempt detorsion and decompression via sigmoidoscopic placement of a soft rectal tube, volvulus distortion through a flexible sigmoidoscopy, or colonoscopy [2,7].

In our case, the extremely dilated sigmoid colon prevented us from attempting endoscopic reduction, as we did not want to increase the possibility of an iatrogenic rupture of the colon. The intraoperative findings confirmed our suspicions, as the intestinal wall appeared to be extremely thin and prone to perforation. In cases with dead intestine, resection and formation of a stoma are the necessary actions which must be taken. Even though many surgeons attempt primary anastomosis in cases with uncomplicated sigmoid volvulus, this requires further thought in pregnant patients as an anastomotic leak can result in major problems to the gravid uterus and fetus [8].

Conclusion:-

The sigmoid volvulus is a rare complication of pregnancy; diagnostic difficulty and delay in taking load may cause significant fetal and maternal morbimortality. The importance of perfect collaboration between the various stakeholders: obstetricians, radiologists and surgeons.

References:-

1. Sigmoid volvulus in pregnancy: case report and review of literature Costas Serafeimidis, Ifereimi Waqainabete, Anne Creaton, Esala Vakamacawai & Ronal Kumar Department of Surgery, Fiji School of Medicine, Colonial War Memorial Hospital, Fiji National University, Suva City, Fiji Clinical Case Reports 2016; 4(8): 759–761
2. Volvulus du sigmoid en cours de grossesse : un piège diagnostique V. Balayaa, *,b,c , A.F. Alixd , J. Nizardd a Service de chirurgie cancérologique, gynécologique et du sein, hôpital européen Georges-Pompidou (HEGP), 20, rue Leblanc, 75908 Paris cedex 15, France Gynécologie Obstétrique Fertilité & Sénologie 45 (2017) 122–126.
3. Khan, M. R., and S. Ur Rehman. 2012. Sigmoid volvulus in pregnancy and puerperium: a surgical and obstetric catastrophe. Report of a case and review of the world literature. World J. Emerg. Surg. 7:10.
4. Aftab, A., A. Toro, A. Abdelaal, M. Dasovsky, S. Gehani, A. Abdel Mola, et al. 2014. Endoscopic reduction of a volvulus of the sigmoid colon in pregnancy: case report and a comprehensive review of the literature. World J. Emerg. Surg. 9:41
5. Sigmoid volvulus in pregnancy and puerperium: a case series Ali Kolusari1 , Mertihan Kurdoglu1 *, Ertan Adali1 , Recep Yildizhan1 , H Guler Sahin1 and Cetin Kotan2 Addresses: 1 Department of Obstetrics and Gynecology, Yuzuncu Yil University School of Medicine, Van, Turkey 2 Department of General Surgery, Yuzuncu Yil University School of Medicine, Van, Turkey Cases Journal 2009, 2:9275 doi: 10.4076/1757-1626-2-9275
6. Palmucci, S., M. L. Lanza, F. Gulino, B. Scilletta, and G. C. Ettorre. 2014. Diagnosis of a sigmoid volvulus in pregnancy: ultrasonography and magnetic resonance imaging findings. J. Radiol. Case Rep. 8:54–62.
7. Wani, M. D., and S. A. Mir. 2013. Gangrenous sigmoid volvulus complicating pregnancy. World J. Med. Surg. Case Rep. 4; <http://www.npplweb.com/wjmscr/fulltext/2/23>.
8. Akcan, A., H. Akyildiz, T. Artis, N. Yilmaz, and E. Sozuer. 2007. Feasibility of single-stage resection and primary anastomosis in patients with acute noncomplicated sigmoid volvulus. Am. J. Surg. 193:421–426.