

 <p>ISSN NO. 2320-5407</p>	<p>Journal Homepage: -<a href="http://www.journalijar.com">www.journalijar.com</a></p> <h2 style="text-align: center;">INTERNATIONAL JOURNAL OF ADVANCED RESEARCH (IJAR)</h2> <p style="text-align: center;">Article DOI:10.21474/IJAR01/8757 DOI URL: <a href="http://dx.doi.org/10.21474/IJAR01/8757">http://dx.doi.org/10.21474/IJAR01/8757</a></p>	 <p>INTERNATIONAL JOURNAL OF ADVANCED RESEARCH (IJAR) ISSN 2320-5407 Journal Homepage: <a href="http://www.journalijar.com">http://www.journalijar.com</a> Article DOI:10.21474/IJAR01/8757</p>
---	--	--

### RESEARCH ARTICLE

#### EFFECT OF BIO-GEN MIX GRANULES IN TREATMENT OF PERIODONTAL INTRABONY DEFECTS.

**Mohammad M. Al Habbal<sup>1</sup>, Wael M. Safwat<sup>2</sup> and Jilan M. Youssef<sup>3</sup>.**

1. Postgraduate student, Department of Oral Medicine, Periodontology, Diagnosis & Oral Radiology, Faculty of Dentistry, Mansoura University, Mansoura City, Egypt.
2. Assistant Professor, Department of Oral Medicine, Periodontology, Diagnosis & Oral Radiology, Faculty of Dentistry, Mansoura University, Mansoura City, Egypt.
3. Professor and Head, Department of Oral Medicine, Periodontology, Diagnosis & Oral Radiology, Faculty of Dentistry, Mansoura University, Mansoura City, Egypt.

#### Manuscript Info

##### Manuscript History

Received: 20 January 2019

Final Accepted: 22 February 2019

Published: March 2019

##### Key words:-

Periodontal intrabony defects, BIO-GEN, bone regeneration.

#### Abstract

**Objective:** Evaluating the effect of BIO-GEN MIX Granules in treating periodontal intrabony defects in severe and advanced periodontitis patients.

**Methods:** The study was based on a split mouth design on 15 patients as follow: Control sites: includes 15 periodontitis patients which were treated by open flap debridement (OFD). Study sites: includes 15 periodontitis patients with periodontal intrabony defects which were treated by OFD with equine bone graft. After completion of phase I therapy, an evaluation of the periodontal indices was performed to start the surgical phase. Clinical parameters included; plaque index (PI), gingival index (GI), bleeding on probing index (BOP), probing pocket depth (PPD), clinical attachment level (CAL), and assessment of bone level (BL) using cone beam radiography. These parameters were recorded for all patients at baseline, three months and six months postoperatively except for BL which was only assessed at baseline and 6 months postoperatively.

**Results:** The clinical and radiographic indices showed better results in the study group when compared to the control group regarding bone regeneration.

**Conclusion:** OFD with BIO-GEN and OFD alone were effective in reducing pocket depth, improving clinical attachment levels and promoting defect fill, OFD with BIO-GEN xenograft material showed better results than OFD alone.

Copy Right, IJAR, 2019,. All rights reserved.

#### Introduction:-

Globally, one of the most widespread complaints is the periodontal disease. Losing the periodontal supporting structures including the periodontal ligament (PDL), alveolar bone, and cementum is the most severe outcome, which leads to the early loss of teeth.(1, 2)

**Corresponding Author:-Mohammad M. Al Habbal.**

Address:-Postgraduate student, Department of Oral Medicine, Periodontology, Diagnosis & Oral Radiology, Faculty of Dentistry, Mansoura University, Mansoura City, Egypt.

Treatment of periodontitis aims at minimizing manifestations of the disease, preventing further disease progression with the intentions to decrease the risk of tooth loss, provide information on maintaining a healthy periodontium and perhaps regenerate the lost periodontal tissue.(3) Scaling and root planning is the official periodontal treatment, which is very impressive in restoring minor disease-related tissue damage and stopping the advancement of the disease. However, they do little in promoting regeneration of the destructed periodontal tissues in advanced cases. On the other hand, periodontal surgery, in particular, regenerative periodontal surgical procedures, aims not only to eliminate pockets but also to restore a new attachment apparatus and reconstructs the lost periodontal component to the previously existing ordinary physiological parameters.(2)

Bone grafting materials are basically categorized into four kinds which are an autograft, allograft, xenograft, and alloplastic graft. A bone graft that is passed in the same person from a site to another is called autograft and is considered as the gold standard since it offers a good scaffold for osteoconduction and includes growth factors for osteoinduction in addition to progenitor cells for osteogenesis. Yet, risking the donor area injury and the possible restriction of graft availability are major disadvantages of autograft procedures. Allografts (from genetically alike individuals of a matching species) and xenografts (from other species) jeopardize disease transmission and an immunologic reaction may be triggered. So, the consideration of using alloplastic (synthetic) grafting materials is increased because of these complications.(4)

Autogenous bone grafts have been referred to as the gold standard and have offered the greatest potential for success in regenerative procedures. This ensures osseous regeneration because it can bear osteogenic, osteoinductive, and osteoconductive properties associated with preosteoblastic cells residing in the graft. It is, however, unfavorable to patients and surgeons because it requires additional surgical sites and also has several disadvantages including limited availability, patient morbidity, and irregular resorption rate, which deter general application in clinical practice. Hence various allogenic bone substitutes have been developed as alternative candidates for osteoblast migration and proliferation. They still, however, have provoked the fear of disease transmission and immunologic reaction. These possible defects of allogenic grafts have led the development of alternative graft materials including xenografts.(82)

Xenografts have clear advantages, as they can be mass-produced in large quantities at relatively affordable processing costs.(6) Deproteinized bovine hydroxyapatite has been documented to be more effective than synthetic alloplasts for promoting new bone formation. Hence, bovine bone mineral has been extensively studied and is widely used in clinics. Despite the deproteinization process of bovine bone substitute for preventing possible immunologic reaction and disease transmission, debate continues over the outbreak of bovine spongiform encephalopathy. Therefore, a need is felt for an alternative type of donor that does not have this risk. Considering the safety of xenogenic material, an equine-derived bone is proposed to be an alternative xenogenic bone substitute material.(82)

Proper diagnosis is a prerequisite for successful treatment in the dental field.(9) Diagnosis of periodontal disease generally depends on clinical examination and radiography, which is important in evaluating the bone loss and the amount of destruction.(10) Two-dimensional (2D) conventional radiographic technologies cannot provide as adequate information regarding periodontal intrabony and furcation defects that are undergoing morphologic changes in three dimensions (3D).(11) Therefore, three-dimensional radiography such as Cone beam CT provides better quantitative and diagnostic data on periodontal bone levels than two-dimensional conventional radiography.(12)

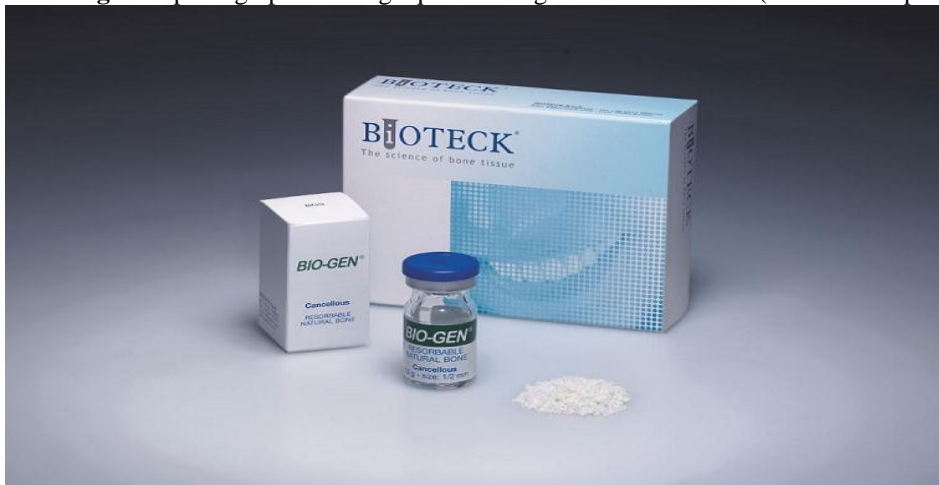Bio-Gen® (Bioteck-Italy) bone material was used in this study, which is considered a xenograft and consist of cancellous-cortical particles of horse femur. Bio-Gen MIX granules is indicated in patients with cases such as periodontal defects, peri-implant defects, post extractive sockets and in sinus lifting surgeries. Although many studies on this material were conducted in the USA and Europe, a limited number of studies were available about its use in treating periodontal intrabony defects in the Middle East, therefore this study was conducted to evaluate the effectiveness of Bio-Gen in treating a sample of Egyptian population patients with periodontal intrabony defects.

### **Subjects and Methods:-**

A total of fifteen subjects from those attending the Department of Oral Medicine and Periodontology Clinic, Faculty of Dentistry, Mansoura University were included in the study. The study was based on a split-mouth design as follow: (Control site): included fifteen periodontal intrabony defects which were treated with open flap debridement

(OFD) and (Study site): included fifteen periodontal intrabony defects which were treated with OFD with bone graft material (BIO-GEN MIX Granules) [Figure 1].

**Fig 1:-**A photograph showing equine Xenograft bone substitute (BIO-GEN® product).



#### **Study design:**

Phase 1 therapy was performed to all patients, which included scaling and root planning, oral hygiene instructions in the form of tooth brushing instructions and the use of chlorhexidine mouthwash and an occlusal adjustment when indicated.

#### **Clinical examination:**

Complete medical and dental histories were taken from all patients. A full periodontal evaluation was made for each patient before, 3 and 6 months after the periodontal surgery including the following clinical parameters:

1. Gingival index (GI) (Löe & Sillness 1963).(13)
2. Plaque index (PI) (Sillness & Löe 1964).(14)
3. Bleeding on probing index (BOP) (Mühlemann 1977).(15)
4. Probing pocket depth (PPD) (Ramfjord 1967).(16)
5. Clinical attachment level (CAL) (Ramfjord 1967).(16)

#### **Radiographic examination:**

1. Preoperative bone defect measurement (at baseline):
2. Initial radiographic assessment using panoramic radiograph.
3. Advanced radiographic assessment: the distance from cemento-enamel junction (CEJ) to the base of the bone defect was measured using CBCT.
4. Postoperative bone fills (after 6 months): the distance from cemento-enamel junction (CEJ) to the base of the new bone level was measured using CBCT.

#### **Surgical procedure:**

Following adequate local anesthesia, buccal and lingual intrasulcular incisions were made using blade no.15 and a full-thickness flap was reflected to expose the intrabony defects with care to preserve the interdental papilla. After debridement of the bone defects, the root surfaces were properly scaled and root planned with Gracey curettes.

Equine bone granules (Bio-Gen) were mixed with drops of sterile saline then carried by a spoon like instrument to be placed into the defect site and condensed gently with a sterile smooth condenser. The graft material was placed in the intrabony defect incrementally to avoid the presence of large voids between the particles of the material and the bony walls of the defect.

Suturing of the flap with 4-0 vicryl suture and the atraumatic curved needle was used. All patients received postoperative instructions and medications, including rinsing with 0.12% chlorhexidine mouthwash (twice daily for two weeks), Augmentin antibiotic 1gm tablet once daily for one week and Ibuprofen anti-inflammatory medication

600mg twice a day for 5 days. Patients were recalled after 6 months post-surgically for clinical and radiographic evaluation.

### Statistical analysis of the data:

The used tests were: (1) Student t test: for parametric quantitative variables, to compare between two studied groups, (2) Mann Whitney U test: for non-parametric variables, (3) Repeated Measures (ANOVA): for parametric quantitative variables, to compare between more than two studied periods with post Hoc LSD for within group's comparison (pairwise comparison), (4) Friedman test: for non-parametric quantitative variables, to compare between more than two studied periods with Wilcoxon signed Rank test to compare every 2 periods.

### Results:-

A statistically significant reduction in the median values of GI, PI and BOP were noticed 6 months following the surgery in both sites [Table 1,2]. However, when comparing between both sites a non-significant change was noticed 6 months after surgery [Table 3,4,5]. Regarding PPD and CAL, both sites showed a significant PPD reduction and CAL gain 3 and 6 after surgery when compared to the baseline [Table 1,2], also the grafted site showed a significantly better results regarding PPD and CAL when compared to the non-grafted site only 6 months after surgery [Table 6,7]. Concerning radiographic changes, an increase in BL was significantly shown in the two sites [Table 1,2], nevertheless BL was significantly higher in the grafted site when compared to the non-grafted site 6 months postoperatively [Table 8].

**Table 1:-**Comparison of changing indices through follow up in control site.

Control site	At baseline	3 Months after the surgery	6 Months after the surgery	Test of sig.
Gingival index Median(Min-max)	1.0(0.5-2.0) <sup>ab</sup>	0.25(0.0-1.0) <sup>a</sup>	0.0(0.0-0.5) <sup>b</sup>	Freidman test p=0.009*
Plaque index Median(Min-max)	1.0(0.75-1.0) <sup>ab</sup>	0.5(0.25-0.50) <sup>ac</sup>	0.0(0.0-0.25) <sup>bc</sup>	Freidman test p=0.007*
Bleeding on probing index Median(Min-max)	2.0(1.0-2.0) <sup>ab</sup>	0.5(0.0-1.0) <sup>a</sup>	0.25(0.0-0.25) <sup>b</sup>	Freidman test p=0.009*
Probing pocket depth Mean±SD	4.57±0.57 <sup>ab</sup>	4.20±0.55 <sup>a</sup>	3.85±0.59 <sup>b</sup>	F=2.7 P=0.03*
Attachment level Mean±SD	5.24±0.25 <sup>ab</sup>	4.74±0.46 <sup>a</sup>	4.33±0.59 <sup>b</sup>	F=2.04 P=0.04*
Bone level Mean±SD	4.97±0.25 <sup>a</sup>		4.57±0.27 <sup>a</sup>	F=4.3 P=0.043

**Table 2:-**Comparison of changing indices through follow up in study site.

Control site	At baseline	3 Months after the surgery	6 Months after the Surgery	Test of sig.
Gingival index Median(Min-max)	1.0(0.5-2.0) <sup>ab</sup>	0.25(0.0-1.0) <sup>a</sup>	0.0(0.0-0.5) <sup>b</sup>	Freidman test p=0.009*
Plaque index Median(Min-max)	1.0(0.75-1.0) <sup>ab</sup>	0.5(0.25-0.50) <sup>ac</sup>	0.0(0.0-0.25) <sup>bc</sup>	Freidman test p=0.007*
Bleeding on probing index Median(Min-max)	2.0(1.0-2.0) <sup>ab</sup>	0.5(0.0-1.0) <sup>a</sup>	0.25(0.0-0.25) <sup>b</sup>	Freidman test p=0.009*

Probing pocket depth Mean±SD	4.57±0.57 <sup>ab</sup>	4.20±0.55 <sup>a</sup>	3.85±0.59 <sup>b</sup>	F=2.7 P=0.03*
Attachment level Mean±SD	5.24±0.25 <sup>ab</sup>	4.74±0.46 <sup>a</sup>	4.33±0.59 <sup>b</sup>	F=2.04 P=0.04*
Bone level Mean±SD	4.97±0.25 <sup>a</sup>		4.57±0.27 <sup>a</sup>	F=4.3 P=0.043

**Table 1:-**The mean value of probing pocket depth at three different periods

	Probing pocket depth			
	At baseline	3 months after surgery	6 months after surgery	P
<b>Control site</b>				
Min. – Max.	4.23 – 5.2	2.33 – 4.8	2 – 4.5	P=0.03*
Mean ± SD.	4.57±0.57	4.20±0.55	3.85±0.59	
Sig. bet. Periods	p <sub>1</sub> =0.03*, p <sub>2</sub> =0.03*, p <sub>3</sub> >0.05			
<b>Study Site</b>				
Min. – Max.	4.2 – 5.1	2.25 – 4	1.66 – 3.2	P<0.05*
Mean ± SD.	4.36±0.69	3.94±0.86	2.16±0.56	
Sig. bet. Periods	p <sub>1</sub> =0.001*, p <sub>2</sub> =0.001*, p <sub>3</sub> =0.001*			
P	0.61	0.26	0.002*	

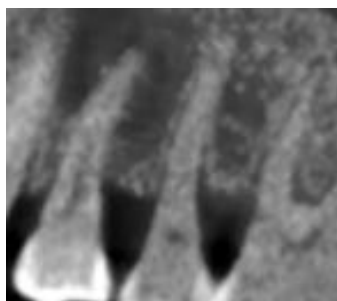
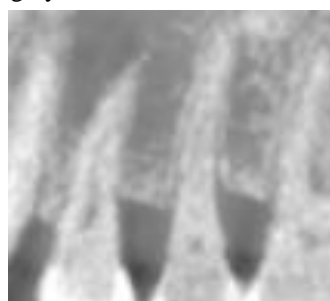
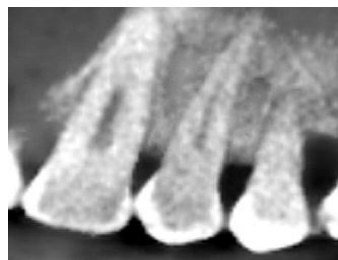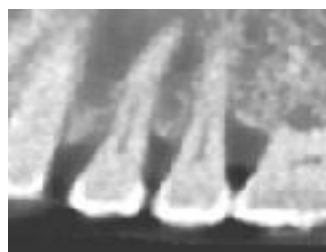**Table 2:-**The mean value of clinical attachment level at three different periods

	Clinical attachment level			
	At baseline	3 months after surgery	6 months after surgery	P
<b>Control site</b>				
Min. – Max.	4.2–5.2	3.5–4.7	3.3–4.6	P=0.04*
Mean ± SD.	5.24±0.25	4.74±0.46	4.33±0.59	
Sig. bet. Periods	p <sub>1</sub> =0.04*, p <sub>2</sub> =0.03*, p <sub>3</sub> >0.05			
<b>Study Site</b>				
Min. – Max.	4–6.4	2.08– 5.5	1.99– 5.05	P<0.05*
Mean ± SD.	4.64±0.49	3.99±1.3	2.92±0.58	
Sig. bet. Periods	p <sub>1</sub> =0.001*, p <sub>2</sub> =0.001*, p <sub>3</sub> =0.001*			

P	0.80	0.26	0.005*	
---	------	------	--------	--

**Table 3:-**The mean value of bone level at two different periods

	Bone level		
	At baseline	6 months after surgery	P <sub>1</sub>
<b>Control site</b>			
Min. – Max.	3.8–5.07	3.5–4.6	P=0.043*
Mean ± SD.	4.97±0.25	4.5±0.27	
<b>Study Site</b>			
Min. – Max.	4–7.36	2.1–4.9	P<0.05*
Mean ± SD.	4.62±0.40	2.66±0.44	
P	0.23	0.001	

**Fig 2:-**A Cone beam for measurement of the bone level of the defect treated with OFD alone at baseline and 6 months after surgery.**Baseline****6 Months postoperatively****Fig 3:-** A Cone beam for measurement of the bone level of the defect treated with OFD and BIO-GEN at baseline and 6 months after surgery.**Baseline****6 Months postoperatively****Discussion:-**

The ultimate goal of periodontal therapy is the regeneration of periodontal supporting tissues that have been lost as a consequence of periodontitis. The key to tissue regeneration is to stimulate a cascade of healing events which, if coordinated, can result in completion of integrated tissue formation. The various treatment modalities include the

use of autografts, allografts, xenografts and alloplastic materials. Bone grafting is a dynamic process. It is a unique scientific attempt employed to incorporate four desired properties-Osteogenesis, Osteoinduction, Osteoconduction and Osteointegration.(17)

The outcomes of treating intrabony defects using OFD with equine bone graft (Bio-Gen®) is superior than treating with OFD alone as shown in the results of this study. In clinical and radiographic parameters a statistically significant enhancement was shown favoring OFD with xenograft group. For regeneration, Bio-Gen® material which is taken from the femur bone of the horse has shown favorable results. The product is easy in handling, osteoconductive, and capable of promoting periodontal ligament cell proliferation. Bio-Gen® is a biocompatible osteoconductive xenograft that is structurally similar to human bone. It is known to be directly bonded chemically to the bone when grafted. In order to permit bone ingrowth and deposition, a scaffold is provided by the osteoconductive properties of the material and thus support to achieve a significant improvement in clinical PPD and CAL. Besides, the apical proliferation of junctional epithelium is prevented by bone grafts, thereby causing actual gain in clinical attachment after the surgery.

When comparing between baseline, 3 and 6 months postoperatively in both sites the plaque index was significantly improved in this study which may be explained by maintaining a good oral hygiene by patients, regulation of follow-up appointments scheduled by the operator, and reinforcing the oral hygiene instructions to the patients by the dentist through the study period. Similar findings were reported by Oreamuno et al. (18)

When comparing between baseline, 3 and 6 months postoperatively in both sites GI and BOP was significantly improved in this study. This may be because the patients were motivated to have a good oral hygiene after scaling and root planning before surgery, the return of the gingival tissues from a diseased state to health after resolution of inflammation, regular supportive treatment delivered postoperatively, and, and also may be. Yukna et al (19), Park et al (20), and Demir et al agreed with these results.(21) Regarding GI, BOP and PI when comparing between both sites at baseline, 3 and 6 months postoperatively no significant difference was found. Mengel et al (22)and Sculean et al also agreed with these findings. (23)

In this study when comparing between both sites at baseline, 3 and 6 months postoperatively PPD and CAL was significantly reduced favoring the results of sites where bone graft was used, which is in consistent with Fatima et al (24) who used inorganic bovine-derived hydroxyapatite matrix/cell binding peptide as a bone graft material in the treatment of human periodontal infrabony defects. Similarly Gokhale, et al (25) had the same results when using Bio-Oss™ in treating infrabony periodontal defects. Also, they think that in order to establish a good understanding of the periodontium regeneration, additional long-term clinical studies with histologic evaluation of the results are required. On the other hand Gojkov Vukelic et al (26) disagree with these findings as thier results did not show any significant reduction in PPD and improvement in CAL when comparing between the two sites.

In the present study the sites where xenograft material was placed showed significantly better radiographic results when compared with the non-grafted sites 6 months after the surgeries regarding new bone level, this may be caused by defect characteristics, good defect debridement, gentle placement of graft particles and reasonable time of follow up. Similar results were found by Attia (27) who used porcine xenograft in the treatment of periodontal intrabony defects, also Jangid (28) had same results in his clinical and radiographic study on treating periodontal intrabony defects with alloplastic fisiograft.

#### **Concerning control site treated with open flap debridement without bone graft:**

In this study PPD and CAL were significantly improved at 3 and 6 months postoperatively when compared to the baseline. In agree with these results, studies done by Graziani et al (29), Kasaj et al (30) . After resolving the inflammation, healing at the base of the pocket may reduce PPD and gain in CAL. Additionally, it could be explained by the regular presurgical plaque control, postoperative supportive program as well as modality of the treatment all contribute in PPD reduction and CAL gain.

On radiographic examination the amount of defect fill 6 months after the surgery was significant different from baseline. In agreement with our results a study by Score (31) showed similar results regarding non-grafted site. In addition similar findings were seen in a study made by Slotte (32) comparing the treatment of periodontal intrabony defects through open flap surgery with and without adjunct bovine bone mineral. Pietruska et al (33) , Heinz et al

(34) and Nasr et al (35) also agreed with these results as their studies revealed that OFD procedures alone without using bone graft materials in treating periodontal intrabony defects have shown to produce 10-30% osseous fill.

#### **Concerning study site treated by OFD with Bio-Gen®:**

In our study PPD and CAL were significantly improved at 3 and 6 months postoperatively when compared to baseline. In agreement with our study results, researches about bovine-derived xenograft by Needleman et al (36) and Sculean et al (37) were conducted which resulted in reduced PPD by 2-5mm and increased in CAL by 2-4 mm.

When comparing between baseline and 6 months after the surgery a significant increase in bone level was detected. Effective xenograft preparation may play an important role in the increase bone level, because its structure is similar to the human bone, and the time of resorption in these biomaterials permit the osteogenesis in the system of pores with a gradual replacement with the recipient's bone. Śmieszek-Wilczewska et al (38) used biogen xenograft in treating alveolar processes of mandible and maxilla and agreed with our results. The results of our study were support by Golam et al (39) whom revealed in thier study the effect of biogen on bone formation. A study by Choi (40) was made to evaluate artificially created infrabony defects, comparing measurements made using periapical radiographs and CBCT reported that higher precision and accuracy were obtained using CBCT.

Results of this study showed that using xenogenic equine bone graft Bio-Gen with OFD has improved the treatment outcome clinically and radiographically more than OFD alone.

#### **Conclusions:-**

BIO-GEN MIX bone graft material has a good result and has the ability to reduce pocket depth, improve clinical attachment levels and promote defect fill.

#### **References:-**

1. Mariotti A, Hefti AF. Defining periodontal health. BMC Oral Health. 2015;1(15):1-18.
2. Jangid MR, Rakhewar P, Nayyar AS, Cholepatil AR. Comparative evaluation of fisiograft (polylactic and polyglycolic acid co-polymer) with open flap debridement (OFD) versus open flap debridement (OFD) alone in the treatment of periodontal intra-bony defects: A clinical and radiographic study. Journal of Clinical Sciences. 2017;14(1):42-8.
3. Graziani F, Karapetsa D, Alonso B, Herrera D. Nonsurgical and surgical treatment of periodontitis: how many options for one disease? Periodontology 2000. 2017;75(1):152-88.
4. Dewi AH, Ana ID. The use of hydroxyapatite bone substitute grafting for alveolar ridge preservation, sinus augmentation, and periodontal bone defect: A systematic review. Heliyon. 2018;4(10):800-84.
5. Jamjoom A, Cohen R. Grafts for ridge preservation. Journal of Functional Biomaterials. 2015;6(3):833-48.
6. Lee JH, Yi GS, Lee JW, Kim DJ. Physicochemical characterization of porcine bone-derived grafting material and comparison with bovine xenografts for dental applications. Journal of Periodontal & Implant Science. 2017;47(6):388-401.
7. Zhang J. The structural stability of wild-type horse prion protein. Journal of Biomolecular Structure and Dynamics. 2011;29(2):369-77.
8. Lo Giudice R, Rizzo G, Centofanti A, Favalaro A, Rizzo D, Cervino G, et al. Steam Sterilization of Equine Bone Block: Morphological and Collagen Analysis. BioMed Research International. 2018;9853765.
9. du Bois A, Kardachi B, Bartold P. Is there a role for the use of volumetric cone beam computed tomography in periodontics? Australian Dental Journal. 2012;1(57):103-8.
10. Hirschmann P. Radiographic interpretation of chronic periodontitis. International Dental Journal. 1987;37(1):3-9.
11. Kim DM, Bassir SH. When is cone-beam computed tomography imaging appropriate for diagnostic inquiry in the management of inflammatory periodontitis? An American Academy of Periodontology best evidence review. Journal of Periodontology. 2017;88(10):978-98.
12. Vandenberghe B, Jacobs R, Yang J. Diagnostic validity (or acuity) of 2D CCD versus 3D CBCT-images for assessing periodontal breakdown. Oral Surgery, Oral Medicine, Oral Pathology, Oral Radiology, and Endodontology. 2007;104(3):395-401.
13. Løe H, Silness J. Periodontal disease in pregnancy I. Prevalence and severity. Acta odontologica scandinavica. 1963;21(6):533-51.



14. Silness J, Loe H. Periodontal disease in pregnancy II. Correlation between oral hygiene and periodontal condition. *Acta odontologica scandinavica*. 1964;22(1):121-35.
15. Mühlemann H. Psychological and chemical mediators of gingival health. *The Journal of preventive dentistry*. 1977;4(4):6.
16. Ramfjord SP. The periodontal disease index (PDI). *The Journal of Periodontology*. 1967;38(6):602-10.
17. Mahajan A, Kedige S. Periodontal bone regeneration in intrabony defects using osteoconductive bone graft versus combination of osteoconductive and osteostimulative bone graft; A comparative study. *Dental Research Journal*. 2015;12(1):25-30.
18. Oreamuno S, Lekovic V, Kenney EB, Carranza Jr FA, Takei HH, Prokic B. Comparative clinical study of porous hydroxyapatite and decalcified freeze-dried bone in human periodontal defects. *Journal of Periodontology*. 1990;61(7):399-404.
19. Yukna RA, Callan DP, Krauser JT, Evans GH, Aichelmann-Reidy ME, Moore K, et al. Multi-center clinical evaluation of combination anorganic bovine-derived hydroxyapatite matrix (ABM)/cell binding peptide (P-15) as a bone replacement graft material in human periodontal osseous defects. 6-month results. *Journal of Periodontology*. 1998;69(6):655-63.
20. Park J-S, Suh J-J, Choi S-H, Moon I-S, Cho K-S, Kim C-K, et al. Effects of pretreatment clinical parameters on bioactive glass implantation in intrabony periodontal defects. *Journal of Periodontology*. 2001;72(6):730-40.
21. Demir B, Şengün D, Berberoğlu A. Clinical evaluation of platelet-rich plasma and bioactive glass in the treatment of intra-bony defects. *Journal of Clinical Periodontology*. 2007;34(8):709-15.
22. Mengel R, Schreiber D, Flores-de-Jacoby L. Bioabsorbable membrane and bioactive glass in the treatment of intrabony defects in patients with generalized aggressive periodontitis: results of a 5-year clinical and radiological study. *Journal of Periodontology*. 2006;77(10):1781-7.
23. Sculean A, Pietruska M, Schwarz F, Willershausen B, Arweiler NB, Auschill TM. Healing of human intrabony defects following regenerative periodontal therapy with an enamel matrix protein derivative alone or combined with a bioactive glass: a controlled clinical study. *Journal of Clinical Periodontology*. 2005;32(1):111-7.
24. Fatima G, Shivamurthy R, Thakur S, Baseer M. Evaluation of anorganic bovine-derived hydroxyapatite matrix/cell binding peptide as a bone graft material in the treatment of human periodontal infrabony defects: A clinico-radiographic study. *Journal of Indian Society of Periodontology*. 2015;19(6):651-8.
25. Gokhale ST, Dwarakanath C. The use of a natural osteoconductive porous bone mineral (Bio-Oss™) in infrabony periodontal defects. *Journal of Indian Society of Periodontology*. 2012;16(2):247.
26. Gojkovic Vukelic M, Hadzic S, Pasic E. Evaluation of Efficacy of Surgical Periodontal Therapy with the Use of Bone Graft in the Treatment of Periodontal Intrabony Defects. *Medical Archives*. 2017;71(3):208-11.
27. Attia AM. Clinical and radiographic evaluation of cortico-cancellous bone mix xenograft (Osteobiol Gen-Os®) in the treatment of human periodontal intrabony defects. *Dental Journal*. 2017;63:1.
28. Jangid MR, Rakhewar P, Nayyar AS, Cholepatil AR. Comparative evaluation of fisiograft (polylactic and polyglycolic acid co-polymer) with open flap debridement (OFD) versus open flap debridement (OFD) alone in the treatment of periodontal intra-bony defects; A clinical and radiographic study. *Journal of Clinical Sciences*. 2017;14(1):42-8.
29. Graziani F, Gennai S, Cei S, Cairo F, Baggiani A, Miccoli M, et al. Clinical performance of access flap surgery in the treatment of the intrabony defect. A systematic review and meta-analysis of randomized clinical trials. *Journal of Clinical Periodontology*. 2012;39(2):145-56.
30. Kasaj A, Röhrig B, Zafiropoulos GG, Willershausen B. Clinical evaluation of nanocrystalline hydroxyapatite paste in the treatment of human periodontal bony defects—a randomized controlled clinical trial: 6-month results. *Journal of Periodontology*. 2008;79(3):394-400.
31. Score SB, Score DSP. Use of Fisiograft in Intrabony Defects-A Clinical and Radiological Study. *Journal of Clinical and Diagnostic Research*. 2013;7(10):2364-7.
32. Slotte C, Asklöv B, Sultan J, Norderyd O. A randomized study of open-flap surgery of 32 intrabony defects with and without adjunct bovine bone mineral treatment. *Journal of Periodontology*. 2012;83(8):999-1007.
33. Pietruska M, Skurska A, Pietruski J, Dolińska E, Arweiler N, Milewski R, et al. Clinical and radiographic evaluation of intrabony periodontal defect treatment by open flap debridement alone or in combination with nanocrystalline hydroxyapatite bone substitute. *Annals of Anatomy-Anatomischer Anzeiger*. 2012;194(6):533-7.
34. Heinz B, Kasaj A, Teich M, Jepsen S. Clinical effects of nanocrystalline hydroxyapatite paste in the treatment of intrabony periodontal defects: a randomized controlled clinical study. *Clinical Oral Investigations*. 2010;14(5):525-31.

35. Nasr HF, Aichelmann-Reidy ME, Yukna RA. Bone and bone substitutes. *Periodontology* 2000. 1999;19(1):74-86.
36. Needleman I, Tucker R, Giedrys-Leeper E, Worthington H. Guided tissue regeneration for periodontal intrabony defects—a Cochrane Systematic Review. *Periodontology* 2000. 2005;37(1):106-23.
37. Sculean A, Chiantella GC, Windisch P, Arweiler NB, Brex M, Gera I. Healing of intra-bony defects following treatment with a composite bovine-derived xenograft (Bio-Oss Collagen) in combination with a collagen membrane (Bio-Gide PERIO). *Journal of Clinical Periodontology*. 2005;32(7):720-4.
38. Smieszek-Wilczewska J, Koszowski R, Pajak J. Comparison of postoperation bone defects healing of alveolar processes of maxilla and mandible with the use of Bio-Gen and Bio-Oss. *Journal of Clinical and Experimental Dentistry*. 2010;2(2):60-6.
39. Golami G-A, Tehrani M, Hooshmand B, Ghanavati F, Mashhadi Abbas F, Akbarzadeh A, et al. Effect of Bio-Gen and Bio-Oss with and without Alendronate on bone formation by “Guided Bone Regeneration”: A histomorphometric study in dogs. *Shahid Beheshti University Dental Journal*. 2011;28(4):185-93.
40. Choi IGG, Cortes ARG, Arita ES, Georgetti MAP. Comparison of conventional imaging techniques and CBCT for periodontal evaluation: A systematic review. *Imaging Science in Dentistry*. 2018;48(2):79-86.