

 <p>ISSN NO. 2320-5407</p>	<p>Journal Homepage: -www.journalijar.com</p> <p>INTERNATIONAL JOURNAL OF ADVANCED RESEARCH (IJAR)</p> <p>Article DOI:10.21474/IJAR01/8527 DOI URL: http://dx.doi.org/10.21474/IJAR01/8527</p>	
---	---	---

RESEARCH ARTICLE

SURGICAL REMOVAL OF IMPACTED CANINE FOLLOWED BY IMMEDIATE IMPLANT PLACEMENT ALONG WITH GUIDED BONE REGENERATION- A SIMULTANEOUS APPROACH.

Kumari Deepika¹, Ankita Singh², Shankar Singh³, Atul Bhatnagar⁴ and Aprajita Verma⁵.

1. Junior Resident, Prosthodontic unit, Faculty of Dental Sciences, IMS, BHU, Varanasi, U.P., INDIA.
2. Associate Professor, Prosthodontic unit, Faculty of Dental Sciences, IMS, BHU, Varanasi, U.P., INDIA.
3. Medical Officer, Government of Rajasthan.
4. Professor, Prosthodontic unit, Faculty of Dental Sciences, IMS, BHU, Varanasi, U.P., INDIA.
5. Senior Resident, AIIMS, Raipur.

Manuscript Info

Manuscript History

Received: 06 December 2018
Final Accepted: 08 January 2019
Published: February 2019

Key words:-

Impacted maxillary canine, Immediate implant, Guided bone regeneration.

Abstract

It is always not possible to extrude impacted canine by orthodontic traction, then extraction is the only option available followed by implant placement. This is a challenge due to a large bone defect created with complex tooth extraction that often necessitates bone grafting. In such cases immediate dental implant placement appears to be the adequate strategy to replace missing tooth along with bone grafting or GBR (Guided bone regeneration)- simultaneous approach. Here, in this case report 25 year old male patient with chief complaint of missing tooth in anterior region having esthetic concerns reported to our department for artificial replacement of that tooth. Radiographically, impacted canine 13 was found and managed by surgical removal of impacted tooth followed by immediate implant placement along with GBR-simultaneous approach.

Copy Right, IJAR, 2019,. All rights reserved.

Introduction:-

Impaction is defined as the failed eruption of a permanent tooth with a completely developed root. Maxillary canines are the second most frequently impacted teeth after the third molars, with a prevalence ranging from 0.9 to 5 %¹ and the palatally impacted canine is more frequent than the labial one². Palatally impacted canines are mostly angulated in horizontal or oblique direction whereas labially impacted are vertically angulated that is easy to retrieve orthodontically in oral cavity. The most common causes for canine impactions are usually localized including tooth size-arch length discrepancies, prolonged retention or early loss of the deciduous canine, abnormal position of the tooth bud, cleft palate, ankylosis, cystic or neoplastic formation and iatrogenic or idiopathic cause.³ The management of impacted canines is one of the most complicated aspects of dento-alveolar surgery. It is also sometimes difficult to extrude impacted canine orthodontically.⁴ The prognosis for orthodontic movement of a palatally impacted tooth depends on a variety of factors, such as the position of the impacted tooth relative to adjacent teeth, its angulation, the distance the tooth has to be moved, and the presence of ankylosis. In general, horizontally impacted or ankylosed canines are the most difficult to manage and have the poorest prognosis.⁵ On the other hand, if traction is not possible or the patient refuses orthodontic treatment due to longer treatment period required, an alternative solution is to remove the impacted tooth and immediately place an implant.⁶ The main advantage being no need of second surgical procedure and less treatment time. In the case of an impacted maxillary canine, the possibility of immediate implant placement after extraction depends on the presence of adequate residual bone to achieve good

Corresponding Author:-Ankita Singh.

Address:- Associate professor, Prosthodontic unit, Faculty of Dental Sciences, Institute of Medical Sciences, Banaras Hindu University, Varanasi-221005, U.P., INDIA.

primary stability.⁸ Here, in this case report, horizontally & palatally impacted canine was managed by immediate implant placement along with GBR following surgical removal of tooth.

Case report:-

A 25 year old male patient reported to our department of Prosthodontics of Faculty of Dental Sciences with chief complaint of missing tooth in right front region of the upper jaw. (Figure 1) On clinical examination, 13 was found missing. Past dental history revealed extraction of 53 (right deciduous canine) 2 years back. An IOPA (intra-oral peri-apical) radiographic examination of missing tooth region was done in which horizontally impacted canine was found w.r.t. root apex of 12 & 14. Upper occlusal radiograph was also done to locate the position of impacted canine.

Thereafter, treatment planning regarding removal of impacted canine followed by implant placement was done & explained to patient. Informed consent was taken for this. After that 64- slice 3-D dentascanner was done to know about available bone for implant placement and position of impacted canine. This radiographic examination revealed horizontal & palatally oriented impacted canine. (Figure 2)

Before undergoing surgical intervention, oral prophylaxis was done. After 1 week, surgical procedure was done under aseptic condition. Local anesthesia (2% Lidocaine with 1:80,000 adrenaline) was administered at the time of surgery. Surgery began with a mid-crestal incision in edentulous area along with vertical releasing incision, a full-thickness flap was elevated and the crestal ridge was exposed upto the inferior border of nasal floor. After that a window was made in labial aspect above the root apices of 11 to 14 to expose the impacted canine. The tooth was removed in 2 sections. (Figure 3a).

The osteotomy was prepared according to ADIN surgical guidelines, starting from pilot drill upto 3.2mm diameter drill to place implant of 3.3mm diameter & 13 mm length. (Figure 3b) The apex of the implant was within the window defect prepared for removal of impacted canine. To cover the defect area and exposed implant thread Geistlich Bio-oss® (bovine bone graft) was used in the form of sticky bone i.e. formed by mixing I-PRF (Injectable-platelet rich fibrinogen) made at 700 rpm for 3 minute and A-PRF (Advanced or PRF enriched leukocytes) membrane made by centrifugation at 1300 rpm for 7 minute in Choukroun PRF (DUO) centrifuge system, placed in the form of membrane, above that resorbable barrier Periocol (synthetic collagen membrane) was placed in double layer technique and stabilised. The flap was replaced and sutured into place. (Figure 4 & 5) Post-operative & oral hygiene instructions were given to patient. Antibiotic regimes & anti-inflammatory analgesics were prescribed for 5 days. Patient was instructed to have a soft diet for atleast 3 months. Sutures were removed after 1 week and an IOPAR examination was done. (Figure 6a) Second stage surgery was done after 6 month of implant placement and healing abutment was placed after an IOPAR examination that revealed bone formation. (Figure 6 b)

After 2 weeks an implant level open-tray impression was made using polyvinyl siloxane (Addition silicone) and send to the lab for fabrication of prosthesis. Before prosthesis, implant stability was checked using RFA (Resonance Frequency Analyser: osstell mentor). ISQ (Implant Stability Quotient) measured was 75, adequate for loading. Cement retained Zirconia crown with implant protected occlusion was given as definitive restoration. (Figure 7) Patient was instructed about soft diet for initial 3 months after loading and oral hygiene maintenance. At follow up after 3 months of loading, implant site was examined clinically and radiographically. The implant was fully osseointegrated, presenting satisfactory functional and esthetic outcome.

Discussion:-

Prosthodontic management of impacted canine is challenging when either patients unwilling to accept orthodontic treatment or when orthodontic traction is not possible due to impacted tooth position. In such cases, treatment of choice is surgical removal of impacted canine followed by the implant placement.

Here in this case report, prolonged retention of deciduous canine was found to be the cause of impaction of permanent canine. Due to horizontal & palatal orientation of the impacted canine, orthodontic traction was difficult to perform. Therefore, impacted canine was surgically removed followed by immediate implant placement in conjunction with bovine bone graft in the form of sticky bone. Biological A-PRF and alloplastic absorbable collagen barrier membrane was placed to secure graft in place. GBR becomes necessary to maintain ridge bone as a large defect created in the process of surgical removal of impacted tooth. The concept of fabricating growth factors-enriched bone graft matrix, known as "sticky bone" or mineralized plasmatic matrix (MPM), using autologous fibrin glue (AGF) provides stabilization of bone graft in the defect as it prevents micro and macro movement of grafted bone. It entraps platelets and leukocytes in its fibrin network, and therefore, accelerates tissue healing and minimizes

bone loss.⁹ Barrier membrane is necessary to secure bone graft and to impede invasion of soft tissue or non-osteogenic cell population into the osseous defect from surrounding area. After GBR procedures, bone regeneration follows a specific sequence of events. Within the first 24 hours after a bone graft, the graft material/barrier created space is filled with the blood clot which releases growth factors (e.g., platelet derived growth factor) and cytokines (e.g., IL-8) to attract neutrophils and macrophages. The clot is absorbed and replaced with granulation tissue which is rich in newly formed blood vessels. Through these blood vessels, nutrients and mesenchymal stem cells capable of osteogenic differentiation can be transported and contribute to osteoid formation. Mineralization of osteoid forms woven bone, which later serves as a template for the apposition of lamellar bone. These events occur 3 to 4 months postsurgery.^{10,11} Prosthetic procedure was performed after 6 months of implant placement as GBR procedure takes time for bone regeneration. Implant stability was also checked using RFA (Resonance Frequency Analysis); Osstell mentor before loading to ensure good stability. Resonance frequency analyser is a device based on vibration and structural principle analysis in which a transducer is attached to implant body & hand held probe that stimulates it magnetically. Resonance frequency values were recorded as ISQ (Implant Stability Quotient) ranges from (0- 100) in bucco-lingual & mesio-distal direction and average of two values was taken as ISQ value. ISQ (Implant Stability Quotient) value was found to be adequate for loading. According to the manufacturer's guidelines, a successful implant typically has an ISQ >65 and an ISQ <50 may indicate failure or increased risk of failure.¹² The success of immediately placed implants in extraction sites of maxillary impacted canine have been found similar to implants placed in healed sites.^{13,14}

Figure 1:-Intra-oral photograph showing missing right maxillary canine.

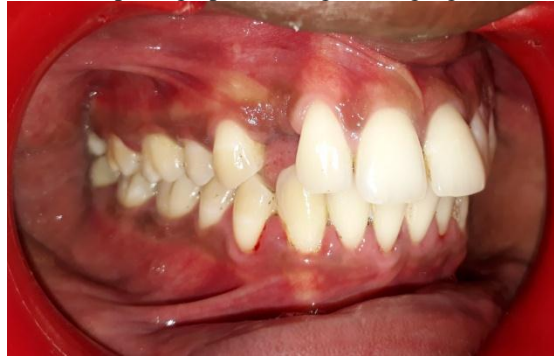

Figure 2:-64 Slice 3-D Dentascan image showing position of impacted canine & available bone below impacted canine.

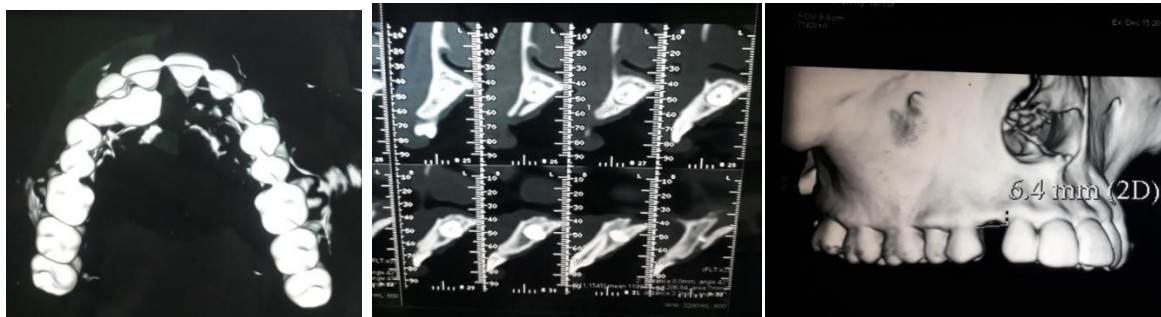


Figure 3:-(a) Full thickness flap reflected & window was made to expose impacted canine & tooth was removed in sections (b) after making osteotomy in crestal region implant was placed.

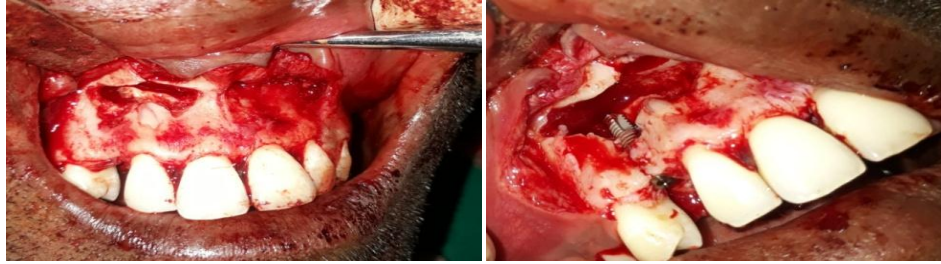

Figure 4:-Sticky bone (Bio-oss graft+I-PRF) & A-PRF formation.

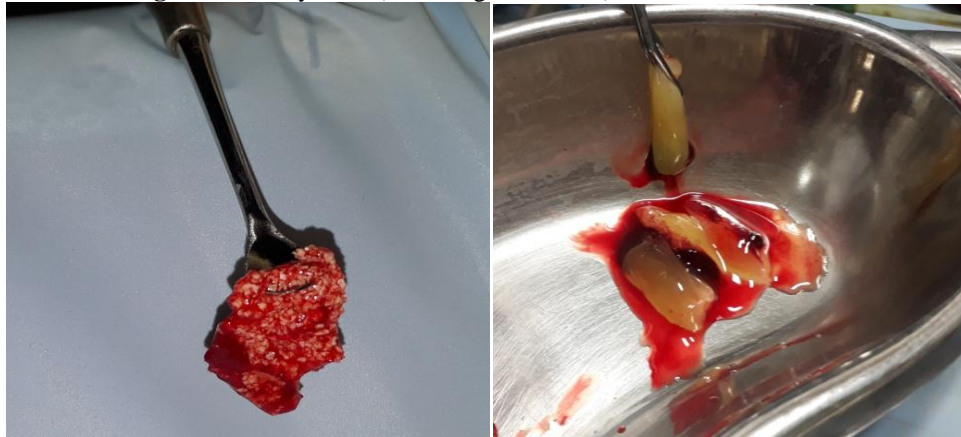

Figure5:-(a) Bone graft and A-PRF membrane was placed to cover the bone defect & exposed implant thread (b) Periocol (Synthetic Collagen membrane) was placed in double layer technique.

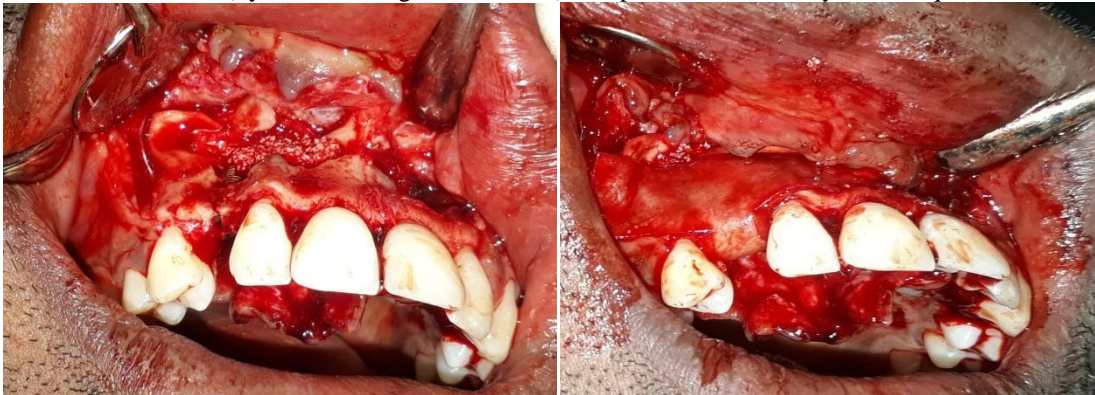


Figure 6:-(a) IOPAR examination was done after 1 week of implant placement (arrow showing radiolucency after removal of impacted canine) (b) IOPAR after 6 months (arrow showing bone formation).

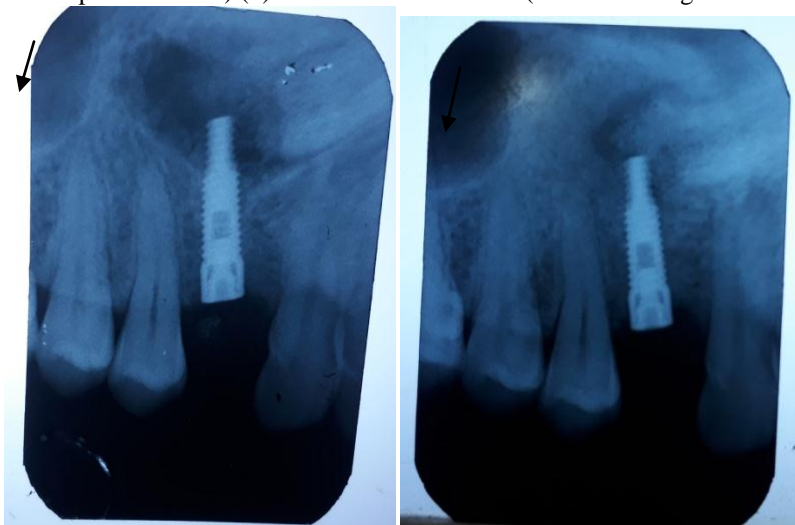
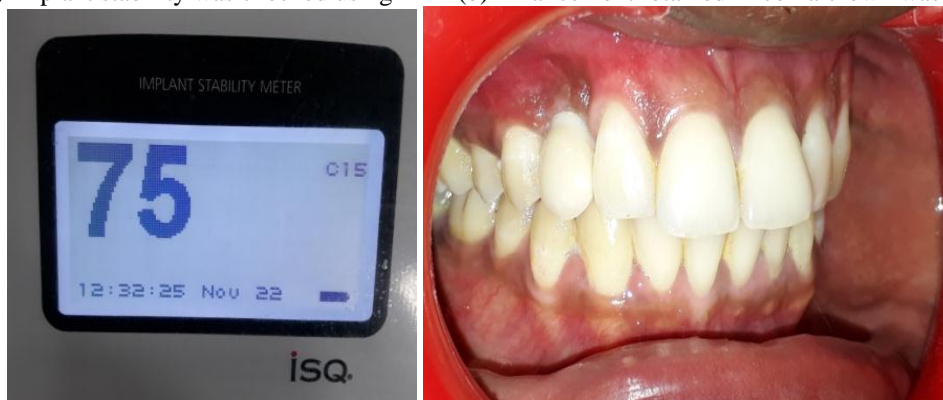


Figure 7:-(a) Implant stability was checked using RFA (b) Final cement retained zirconia crown was placed.



Conclusion:-

Immediate implant placement after surgical removal of impacted canine along with GBR provides a better treatment modality when orthodontic treatment is not possible. GBR- simultaneous approach will be the better option where good primary implant stability can be achieved. This treatment modality is good alternative for patients as it also reduces the total treatment time needed for prosthetic phase.

References:-

1. Dalessandri D, Parrini S, Rubiano R, Gallone D, Migliorati M. Impacted and transmigrant mandibular canines incidence, aetiology, and treatment: a systematic review. *Eur J Orthod* 2016; 1-9.
2. Silva AC, Capistrano A, Almeida-pedrin RR, et al. Root length and alveolar bone level of impacted canines and adjacent teeth after orthodontic traction: a long-term evaluation. *J Appl Oral Sci* 2017; 25(1): 75-81.
3. Bishara SE . Impacted maxillary canines: A review. (*AM J Orthod Dentofacial Orthop* 1992; 101:159-71.)
4. Alberto PL (2007) Management of the impacted canine and second molar. *Oral Maxillofac Surg Clin North Am* 19(1): 59-68.
5. Kuftinec MM, Shapira Y. The impacted maxillary canine: II. Surgical consideration and management. *Quintessence Int* 1984; 13(9):895-7.
6. Demarosi F, Varoni E, Rimondini L, Carrassi A, Leghissa GC. Immediate implant placement after removal of maxillary impacted canine teeth: A technical note. *Int J Oral Maxillofac Implants* 2016; 31(1): 191-194.
7. Chrcanovic BR, Albrektsson T, Wennerberg A. Dental implants inserted in fresh extraction sockets versus healed sites: a systematic review and meta-analysis. *J Dent* 2016; 43(1): 16-41.
8. Peñarrocha M, Peñarrocha M, García-Mira B, Larrazabal C. Extraction of impacted maxillary canine with simultaneous implant placement. *J Oral Maxillofac Surg* 2007; 65(11): 2336-2339.
9. Dong-SeokSohn, Bingzhen Huang, Jin Kim, W. Eric Park, Charles C. Park. Utilization of Autologous Concentrated Growth Factors (CGF) Enriched Bone Graft Matrix (Sticky Bone) and CGF-Enriched Fibrin Membrane in Implant Dentistry. *The Journal of Implant & Advanced Clinical Dentistry*. 2015;7(10):11-28
10. Schenk RK, Buser D, Hardwick WR, et al. Healing pattern of bone regeneration in membrane-protected defects: a histologic study in the canine mandible. *Int J Oral Maxillofac Impl* 1994; 9: 13-29.
11. Buser D. 20 years of guided bone regeneration in implant dentistry. 2nd ed. Chicago: Quintessence Pub. Co; 2009.
12. Nedir R, Bischof M, Szmukler-Moncler S, Bernard JP, Samson J. Predicting osseointegration by means of implant primary stability. A resonance-frequency analysis study with delayed and immediately loaded ITI SLA implants. *Clin Oral Implants Res* 2004; 15: 520-528.
13. Mazor Z, Peleg M, Redlich M (1999) Immediate placement of implants in extraction sites of maxillary impacted canines. *J Am Dent Assoc* 130(12): 1767-1770.
14. Falcon GB. Immediate Implant Post-Extraction of Impacted Maxillary Canine: Systematic Review. *J Dental Sci* 2017, 2(2): 000130.