

REVIEW ARTICLES

DOI: 10.5281/zenodo.2590020
UDC: 616.831.8-009.17



Lambert-Eaton myasthenic syndrome – a misdiagnosed condition

^{1,2}Paula Fala, MD; ²Ina Cojocaru, MD; ²Larisa Chetrari, MD;
^{*1,2}Pavel Gavriluc, MD, PhD Applicant; ^{1,2}Marina Sangheli, MD, PhD, Associate Professor;
^{1,2}Vitalie Lisnic, MD, PhD, Professor

¹Department of Neurology No 1, Nicolae Testemitsanu State University of Medicine and Pharmacy

²Department of Neuromuscular Disorders and Polyneuropathies, Institute of Neurology and Neurosurgery
Chisinau, the Republic of Moldova

*Corresponding author: gavrilucpavel@gmail.com

Manuscript received December 18, 2018; revised manuscript February 05, 2019

Abstract

Background: Lambert-Eaton myasthenic syndrome (LEMS) is a rare disorder of the neuromuscular junction. Clinical features include proximal muscle weakness, markedly in the lower limbs, reduced deep tendon reflexes that can increase after exercise, and autonomic disturbances. The clinical picture as well as knowledge of the laboratory test that accompany LEMS will permit early recognition of the disease, that is crucial because it is often associated with malignancy, especially small cell lung cancer (SCLC). In this article we present a patient with proximal muscle weakness and typical changes on repetitive nerve stimulation, as well as a short literature review on the topic.

Conclusions: The diagnosis of LEMS is usually made on clinical grounds. The diagnosis is confirmed by electrophysiological testing, main features including decrement response on slow repetitive nerves stimulation (3Hz), and an increment of more than 100% in CMAP amplitude after brief exercise, or high frequency repetitive stimulation (30-50 Hz). Immunological panel assay with positive P/Q-type VGCC antibody is strongly suggestive of LEMS. While symptomatic treatment with 3,4 – diaminopyridine is available, one of the main priorities is evaluation for underlying malignancies in these patients, the most common being SCLC. Evaluation of patients with LEMS and no known cancer should start with CT of the chest, abdomen and pelvis. Brain imaging is recommended if focal neurological signs are present. If the initial evaluation of the patient is negative, repeated screening for malignancy after 6 months and up to two years is recommended.

Key words: Lambert-Eaton myasthenic syndrome, cancer, weakness, increment.

Introduction

The neuromuscular junction (NMJ) disorders are often seen in the clinical practice of general neurologists and other specialists. The prevalence of myasthenia gravis (MG), the most common NMJ disorder is 1:10.000 inhabitants [1]. At the same time, the spectrum of diseases affecting neuromuscular transmission at the synapse level is wide. If the classical postsynaptic disorder like MG is easily diagnosed, the presynaptic one is often misinterpreted. The presynaptic NMJ disorder like the Lambert-Eaton myasthenic syndrome (LEMS) is rare. It is an idiopathic or paraneoplastic autoimmune disorder of the presynaptic nerve terminal of the NMJ transmission. The relation between patients with LEMS and MG is 1:10 [2]. At the same time, the establishment of the correct diagnosis could lead to the search of the malignancy when the last is at the treatable stage.

LEMS is a rare condition with the main clinical manifestation of skeletal muscular weakness, reduced reflexes and autonomic involvement. Specific clinical picture, laboratory and electrophysiological studies allow for early diagnosis, which is important as this syndrome is strongly associated with small cell lung cancer (SCLC) [3].

Pathophysiology of LEMS includes antibodies against

P/Q-type voltage gated calcium channels (VGCC) that reduce the amount of acetylcholine (ACh) released in the synaptic cleft [4].

We present a typical Lambert-Eaton syndrome.

A 58 year-old male, a truck driver, complaining of proximal muscle weakness and progressive gait disturbance (requiring a cane for walking at first presentation) for 2 months. Upon admission he had as well dry mouth, hypohidrosis. The patient noticed that he could stand up with difficulties in the cabin of the car. He complained of low back pain and his family physician diagnosed him with radiculopathy. He received treatment with Dexamethasone 8 mg and NSAIDs for 5 days consecutively with no significant improvement.

The patient's history is remarkable as he is a heavy smoker (138 pack-years, 60 cigarettes per day). The patient also suffers from a mild diabetes mellitus, arterial hypertension, and hepatic steatosis. At clinical examination he had a blood pressure 130/80 mmHg on antihypertensive medications, heart rate 75 beats per minute, in sinus rhythm, respiratory frequency 18 per min, and a BMI – 39.1 that qualifies as obesity class 2. Neurological examination revealed decreased muscle strength on MRC scale 4/5 in all limbs, but with a 3/5 in proximal muscle groups. He hardly could stand up from sitting position and had decreased deep tendon

reflexes, which improved after exercise. The sensory disturbances were suggestive of polyneuropathy with hypoesthesia in “gloves and socks” distribution and segmental L5 – S1 hypoesthesia. Neither pathological signs nor sphincter disturbances were found. Cerebellar tests were normal. Meningeal and elongation signs were negative.

MRI of the lumbar spine was performed that revealed intervertebral discs protrusions at the L2 – L3, L3 – L4, L5 – S1 levels.

Routine nerve conduction studies were performed which were within normal range. On EMG with slow (3Hz) repetitive nerve stimulation (RNS), decrement of 21% (fig. 1) was noted at rest, at the first examination, with a compound muscle action potential (CMAP) increase of more than 100% in amplitude after isotonic exercise for 30 seconds (fig. 2).

The history and physical examination of the patient, with proximal muscle weakness, increase in deep tendon reflexes after exercise, as well as increase of amplitude of more than 100% on repetitive nerve stimulation after isometric contraction, lead to the idea of a presynaptic disorder [5]. Given the history of the patient being a heavy smoker and clinical and electrophysiological changes suggesting a presynaptic disorder, the presumption of Lambert-Eaton myasthenic syndrome was made.

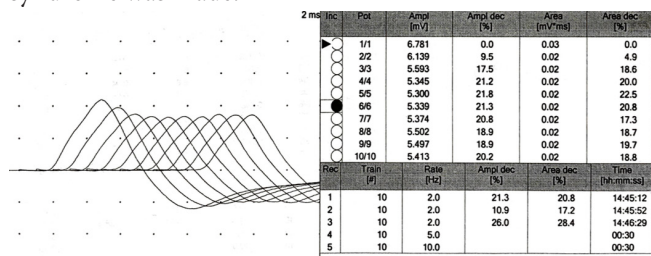


Fig. 1. Decrement of 21% at rest during slow (3 Hz) repetitive nerve stimulation of the left ulnar nerve.

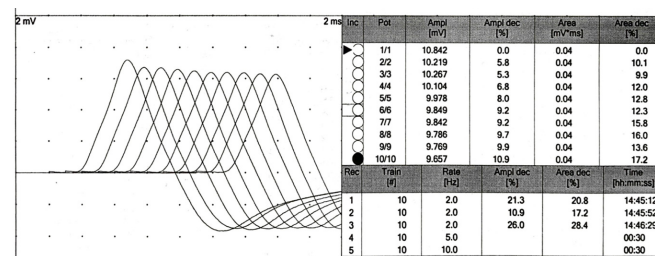


Fig. 2. Increment of more than 100% in CMAP amplitude following a 30 seconds isotonic exercise in the left ulnar nerve.

Computer tomography (CT) of the lungs was ordered to rule out neoplastic formations, and serological testing for specific antibodies was carried out.

The malignancy workup including CT of the lungs (fig. 3), oncological markers for CEA, PSA, CA 19-9 came back negative, while immunologic assay for anti VGCC antibodies came positive for both type N and PQ (tab. 1) that further confirmed our suspicions of Lambert-Eaton myasthenic syndrome.

During admission, plasma exchange was initiated with mild improvement of symptoms. When the immunologic

results for anti VGCC came positive, treatment with Prednisone and Azathioprine was started to control the immune response, while 3,4-diaminopyridine was recommended for symptoms control.

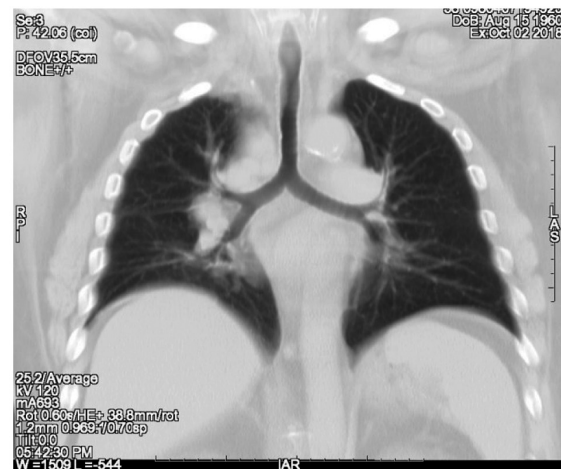


Fig. 3. Lung CT without pathological changes.

Table 1

Immunologic assay for anti VGCC (type N and PQ)			
Type N	20,9	Index	< 10
Type PQ	248,9	pmol/L	< 40

Discussion

Our patient addressed the first time for low back pain, and that remained his chief complaint even 2 months later after the initial episode, in spite of progressive weakness and difficulties in walking and getting up from a chair.

The most common causes of low back pain are degenerative disc disease, spondylosis, spinal stenosis, radiculopathy, and fractures. These mechanical conditions account for about 90% of cases in low back pain patients. Non-mechanical causes may include myopathy, myelopathy, plexopathies, neuropathies, neoplasms, vascular, gastrointestinal, and genitourinary infections [6].

The history and physical examination revealed proximal weakness greater than distal. The most common neuromuscular disorders causing this pattern of weakness include myopathies, acute/chronic inflammatory demyelinating polyradiculoneuropathy such as Guillain-Barre syndrome or diabetic plexopathy, disorders of the neuromuscular junction, and forms of Spinal Muscular Atrophy, most common Type III (Kugelberg-Welander disease). The differential diagnosis for neuromuscular junction disorders includes the most common post-synaptic disorders, MG and pre-synaptic disorders such as LEMS and botulism.

In our patient, back pain can be explained by the sequelae of LEMS. The proximal weakness and weakness of the supporting structures of the spine and more prominent in the lower back, contributed to an over stress of the lower spine that resulted in low back pain [7].

LEMS is a rare condition which results from an autoimmune attack against voltage-gated calcium channels at the presynaptic motor nerve terminal [8]. It is the second most

common neuromuscular junction disorder. This causes an abnormality of acetylcholine release at the neuromuscular junction. In LEMS the number of Ach quanta released from the presynaptic membrane is reduced, despite normal amount of Ach vesicles, normal presynaptic concentration, and normal postsynaptic Ach receptors. Lambert and Elmqvist described the unique features of this condition with normal miniature endplate potential amplitude, demonstrating normal postsynaptic sensitivity to acetylcholine and markedly reduced evoked endplate potential amplitude, suggesting a significant reduction in Ach release [9]. Ach release is increased by increasing calcium concentration but not potassium-induced depolarization.

LEMS is an autoimmune disorder with autoantibodies directed against voltage-gated calcium channels (VGCC). VGCC is a large transmembrane protein with many subunits and is the target of the antibodies. These antibodies interfere with normal function of the VGCC, thus reducing the normal flux of calcium required for release of acetylcholine [8].

Typical age of onset is of 50 years or more and is characterized by leg and/or general weakness, rarely muscle pain, arm weakness, diplopia and dysarthria [10]. Autonomic dysfunction such as xerostomia, hypohidrosis, blurred vision; constipation and orthostatic hypotension have been frequently observed [11]. Post exercise facilitation is another distinctive feature and is characterized by increase of the deep tendon reflexes and muscular strength after exercise. Cranial nerves are usually spared [12]. Respiratory symptoms may occur [13, 14].

There are two major forms of LEMS: paraneoplastic and non-paraneoplastic. It is most commonly associated with small cell lung cancer (SCLC) especially in heavy smokers, more frequently in males than in females [15, 16].

Electrophysiological testing includes routine motor and sensory nerve conduction studies, high-frequency repetitive nerve stimulation (RNS) and/or exercise testing that shows changes suggesting dysfunction of the presynaptic membrane in LEMS [17]. Needle electromyography is done to exclude motor neuron disease, and in selected patients, single fiber electromyography is performed as it is very sensitive for neuromuscular junction disorders, but not specific for a presynaptic localization [18].

Routine motor and sensory nerve conduction studies should be performed in at least two nerves, CMAP amplitudes usually are diffusely low or borderline, with normal latencies and conduction velocities. This response may increase after brief exercise [18].

RNS and exercise testing is done by either high-frequency (30-50Hz) RNS or slow (2-3 Hz) RNS stimulation and brief, 10 seconds, exercise. Exercise testing is better tolerated by the patients and is preferable to fast RNS unless the patient can not cooperate. An increment greater than 40% is abnormal. Most patients with LEMS will have an increment greater than 100%. Any increment between 40 and 100% is a sign of presynaptic disorder. Slow RNS (3Hz) may elicit a decremental response, however, after brief exercise, the baseline CMAP is significantly larger compared to pre-exercise CMAP [5, 19]. This peculiarity was registered at our patient.

Needle electromyography is usually normal in LEMS, but the action potential may be unstable and of low amplitude, sometimes polyphasic with normal or early recruitment pattern [18, 20].

Single-fiber EMG may be performed, and changes will be consistent with a neuromuscular junction disorder, like increased jitter and blocking, but it cannot differentiate LEMS from other disorders of the neuromuscular junction [21, 22, 23]. Serologic panel should contain P/Q calcium channel antibodies, creatine kinase and paraneoplastic markers [4, 24].

Differential diagnose should be made with MG [12], myopathies [25] and motor neuron disease [26]. MG involves the ocular and bulbar muscles to a greater extent whereas in LEMS the proximal lower extremities are primarily affected. In motor neuron disease muscle atrophy, hyperreflexia and pathological signs are the prominent features in contrast to LEMS where these clinical signs are not present. Electrophysiological and serological testing will differentiate from myasthenia gravis, myopathy or motor neuron disease.

Main priority in a patient with LEMS is to evaluate for malignancy that is found in about 50% of cases [27, 28]. In many patients, treatment of the underlying malignancy will improve the neurological symptoms. The most common tumor associated with LEMS is small cell lung cancer, especially among smoking patients which are 50 years or older [27]. Other malignancies associated with LEMS are Hodgkin lymphoma [29, 6], and rarely atypical carcinoid [30], thymic neuroendocrine carcinoma [31], malignant thymoma [32], and neuroblastoma [33].

Evaluation of patients diagnosed with LEMS and no known cancer, should start with CT of the chest, abdomen and pelvis. Brain imaging is recommended if focal neurological signs are present. If the initial evaluation of the patient is negative, repeated screening for malignancy after 6 months is recommended. Evaluations should be repeated until at least 2 years if no cancer is found [34].

Patients with paraneoplastic LEMS have a shortened life expectancy because of the progression of the associated neoplasm. Survival is correlated with the stage of the disease at presentation. A longer survival was observed in patients with SCLC that developed LEMS, the last one representing an independent predictor of prolonged survival [34].

Patients with non-paraneoplastic LEMS may have a normal or almost normal life expectancy, although a minority may remain disabled. Most of the deaths were not caused by LEMS but they might be related to complications of glucocorticoid therapy.

First line treatment in LEMS is 3,4 - diaminopyridine (3,4 - DAP) [35] that blocks the presynaptic voltage-gated potassium channels increase obtaining in result the release of ACh into the synaptic cleft. Long term immunosuppressive treatment with prednisone and azathioprine, plasma exchange or IVIg help ameliorate the symptoms. However, the aggressive immune suppression can lead to immunologic suppression of tumor growth and in this case, it is up to the physician whether aggressive therapy is safe [34].

At our patient the search for a malignancy didn't give an

indication of an underlying cancer. In spite of the fact that the patient is a heavy smoker we didn't get evidence of a SCLC. We will repeat the investigations, including chest CT, 3-6 months later. Treatment with azathioprine and corticosteroids slightly improved his condition.

Conclusions

LEMS is an acquired paraneoplastic or idiopathic disorder of the pre-synaptic membrane of the NMJ. Autoantibodies directed against voltage-gated calcium channels located on the pre-synaptic membrane lead to a decrease in release of acetylcholine in to the synaptic cleft. Clinical features include proximal muscle weakness, markedly in the lower limbs, reduced deep tendon reflexes that can increase after exercise, and autonomic disturbances. In about 50% of cases LEMS is associated with small cell lung cancer. Electrophysiological testing is important in the diagnostics of LEMS, main features including decrement response on slow repetitive nerves stimulation (3Hz), and an increment of more than 100% in CMAP amplitude after brief exercise, or high frequency repetitive stimulation (30-50 Hz). Immunological assay for antibodies directed against voltage-gated calcium channels P/Q or N type has a high specificity and is confirmatory of LEMS when present. Symptomatic Treatment includes 3,4 – diaminopyridine (3,4 – DAP) and immunosuppression, with intensive monitoring for malignancy, especially small cell lung cancer.

References

1. Mahadeva B, Phillips LH 2nd, Juel VC. Autoimmune disorders of neuromuscular transmission. *Semin Neurol*. 2008;28(2):212-27.
2. Nicolle MW. Myasthenia Gravis and Lambert-Eaton Myasthenic Syndrome. *Continuum (Minneapolis)*. 2016;22(6, Muscle and Neuromuscular Junction Disorders):1978-2005.
3. Sanders DB, Gupitill JT. Myasthenia gravis and Lambert-Eaton myasthenic syndrome. *Continuum (Minneapolis)*. 2014;20(5 Peripheral Nervous System Disorders):1413-25.
4. Motomura M, Johnston I, Lang B, et al. An improved diagnostic assay for Lambert-Eaton myasthenic syndrome. *J Neurol Neurosurg Psychiatry*. 1995;58(1):85-7.
5. AAEM Quality Assurance Committee. American Association of Electrodiagnostic Medicine. Practice parameter for repetitive nerve stimulation and single fiber EMG evaluation of adults with suspected myasthenia gravis or Lambert-Eaton myasthenic syndrome: summary statement. *Muscle Nerve*. 2001;24(9):1236-8.
6. Lemal R, Chaletix C, Minard P, Roche C, Bay JO, Tournilhac O, Lamy T. Large granular lymphocytic leukemia associated with Lambert-Eaton Myasthenic Syndrome: a case report. *Leuk Res Rep*. 2013 Apr 2;2(1):32-3.
7. Keesey JC. Clinical evaluation and management of myasthenia gravis. *Muscle Nerve*. 2004;29(4):484-505.
8. Lang B, Newsom-Davis J, Wray D, Vincent A, Murray N. Autoimmune aetiology for myasthenic (Eaton-Lambert) syndrome. *Lancet*. 1981;2(8240):224-6.
9. Lambert EH, Elmqvist D. Quantal components of end-plate potentials in the myasthenic syndrome. *Ann N Y Acad Sci*. 1971;183:183-99.
10. O'Neill JH, Murray NM, Newsom-Davis J. The Lambert-Eaton myasthenic syndrome. A review of 50 cases. *Brain*. 1988;111 (Pt 3):577-96.
11. Clark CV, Newsom-Davis J, Sanders MD. Ocular autonomic nerve function in Lambert-Eaton myasthenic syndrome. *Eye (Lond)*. 1990;4 (Pt 3):473-81.
12. Wirtz PW, Sotodeh M, Nijhuis M, Van Doorn PA, Van Engelen BG, Hintzen RQ, De Kort PL, Kuks JB, Twijnstra A, De Visser M, Visser LH, Wokke JH, Wintzen AR, Verschuuren JJ. Difference in distribution of muscle weakness between myasthenia gravis and the Lambert-Eaton myasthenic syndrome. *J Neurol Neurosurg Psychiatry*. 2002;73(6):766-8.
13. Titulaer MJ, Wirtz PW, Kuks JB, Schelhaas HJ, van der Kooij AJ, Faber CG, van der Pol WL, de Visser M, Sillevius Smitt PA, Verschuuren JJ. The Lambert-Eaton myasthenic syndrome 1988-2008: a clinical picture in 97 patients. *J Neuroimmunol*. 2008;201-202:153-8.
14. Laroche CM, Mier AK, Spiro SG, Newsom-Davis J, Moxham J, Green M. Respiratory muscle weakness in the Lambert-Eaton myasthenic syndrome. *Thorax*. 1989;44(11):913-8.
15. Benatar M, Blaes F, Johnston I, Wilson K, Vincent A, Beeson D, Lang B. Presynaptic neuronal antigens expressed by a small cell lung carcinoma cell line. *J Neuroimmunol*. 2001;113(1):153-62.
16. Lennon VA, Lambert EH, Whittingham S, Fairbanks V. Autoimmunity in the Lambert-Eaton myasthenic syndrome. *Muscle Nerve*. 1982;5(9S):S21-5.
17. Oh SJ, Kim DE, Kuruoglu R, Brooks J, Claussen G. Electrophysiological and clinical correlations in the Lambert-Eaton myasthenic syndrome. *Muscle Nerve*. 1996;19(7):903-6.
18. Preston DC, Shapiro BE. Neuromuscular junction disorders. In: *Electromyography and neuromuscular disorders: Clinical-electrophysiologic correlations*. 3rd ed. New York: Elsevier; 2013. p. 529.
19. Dumitru D, Amato AA. Neuromuscular junction disorders. In: Dumitru D, Amato AA, Zwarts MJ, editors. *Electrodiagnostic medicine*. 2nd ed. Philadelphia, PA: Hanley & Belfus; 2002. p. 1179-80.
20. Crone C, Christiansen I, Vissing J. Myopathic EMG findings and type II muscle fiber atrophy in patients with Lambert-Eaton myasthenic syndrome. *Clin Neurophysiol*. 2013 Sep;124(9):1889-92. Epub 2013 May 3.
21. Trontelj JV, Stalberg E. Single motor end-plates in myasthenia gravis and LEMS at different firing rates. *Muscle Nerve*. 1991;14(3):226-32.
22. Chaudhry V, Watson DF, Bird SJ, Cornblath DR. Stimulated single-fiber electromyography in Lambert-Eaton myasthenic syndrome. *Muscle Nerve*. 1991;14(12):1227-30.
23. Oh SJ, Ohira M. Single-fiber EMG and clinical correlation in Lambert-Eaton myasthenic syndrome. *Muscle Nerve*. 2013 May;47(5):664-7. Epub 2013 Mar 16.
24. Nakao YK, Motomura M, Fukudome T, Fukuda T, Shiraishi H, Yoshimura T, Tsujihata M, Eguchi K. Seronegative Lambert-Eaton myasthenic syndrome: study of 110 Japanese patients. *Neurology*. 2002;59(11):1773-5.
25. So YT. Immune-mediated neuropathies. *Continuum (Minneapolis)*. 2012 Feb;18(1):85-105.
26. Kim WK, Liu X, Sandner J, Pasmantier M, Andrews J, Rowland LP, Mitsumoto H. Study of 962 patients indicates progressive muscular atrophy is a form of ALS. *Neurology*. 2009;73(20):1686-92.
27. Payne M, Bradbury P, Lang B, Vincent A, Han C, Newsom-Davis J, Talbot D. Prospective study into the incidence of Lambert Eaton myasthenic syndrome in small cell lung cancer. *J Thorac Oncol*. 2010;5(1):34-8.
28. Wirtz PW, Lang B, Graus F, van den Maagdenberg AM, Saiz A, de Koning Gans PA, Twijnstra A, Verschuuren JJ. P/Q-type calcium channel antibodies, Lambert-Eaton myasthenic syndrome and survival in small cell lung cancer. *J Neuroimmunol*. 2005;164(1-2):161-5.
29. Argov Z, Shapira Y, Averbuch-Heller L, Wirguin I. Lambert-Eaton myasthenic syndrome (LEMS) in association with lymphoproliferative disorders. *Muscle Nerve*. 1995;18(7):715-9.
30. Gutmann L, Phillips LH 2nd, Gutmann L. Trends in the association of Lambert-Eaton myasthenic syndrome with carcinoma. *Neurology*. 1992;42(4):848-50.
31. Nalbantoglu M, Kose L, Uzun N, Gunduz A, Hallac M, Kiziltan ME, Akalin MA. Lambert-Eaton myasthenic syndrome associated with thymic neuroendocrine carcinoma. *Muscle Nerve*. 2015;51(6):936-8. Epub 2015 Mar 14.
32. Lauritzen M, Smith T, Fischer-Hansen B, Sparup J, Olesen J. Eaton-Lambert syndrome and malignant thymoma. *Neurology*. 1980;30(6):634-8.
33. Hajjar M, Markowitz J, Darras BT, Kissel JT, Srinivasan J, Jones HR. Lambert-Eaton syndrome, an unrecognized treatable pediatric neuromuscular disorder: three patients and literature review. *Pediatr Neurol*. 2014;50(1):11-7.
34. Titulaer MJ, Soffietti R, Dalmau J, Gilhus NE, Giometto B, Graus F, Grisold W, Honnorat J, Sillevius Smitt PA, Tanasescu R, Vedeler CA, Voltz R, Verschuuren JJ; European Federation of Neurological Societies. Screening for tumours in paraneoplastic syndromes: report of an EFNS task force. *Eur J Neurol*. 2011;18(1):19-e3.
35. Wirtz PW, Verschuuren JJ, van Dijk JG, de Kam ML, Schoemaker RC, van Hasselt JG, Titulaer MJ, Tjaden UR, den Hartigh J, van Gerven JM. Efficacy of 3,4-diaminopyridine and pyridostigmine in the treatment of Lambert-Eaton myasthenic syndrome: a randomized, double-blind, placebo-controlled, crossover study. *Clin Pharmacol Ther*. 2009;86(1):44-8. Epub 2009 Apr 8.