World Inventia Publishers

Journal of Pharma Research

http://www.jprinfo.com/

Vol. 7, Issue 12, 2018 ISSN: 2319-5622 USA CODEN: JPROK3

Research Article

HESPERIDIN (HDN) AN ANTIOXIDANT FLAVONOID PREVENTS CARBON TETRACHLORIDE (CCl4) - INDUCED HEPATIC TOXICITY IN MALE ALBINO RATS

Asmaa Abdulaziz Ahmeedah Rabee * and Hassen A.H. Bennasir

Department of Pharmacology & Toxicology, Faculty of Pharmacy & Medicine, Omar-Al-Mukthar University, Derna, LIBYA.

Received on: 11-11-2018; Revised and Accepted on: 29-12-2018

ABSTRACT

Background: *Through this research work, an experimental study was conducted to evaluate the protective effects of an antioxidant (Hesperidin) on carbon tetrachloride-induced hepatic toxicity. This effect was evaluated through assessment of liver functions as well as histopathological changes in livers of rats exposed to Hesperidin prior to carbon tetrachloride.*

Materials and Methods: *Thirty two male albino rats (160-200 gm) were chosen as an animal model for this study and distributed to four equal groups each of 8 rats.* ***Group I*** *(Negative control group, i.e., No CCL_4 or HDN).* ***Group II*** *(Positive control group): received vehicle (Carboxymethyl Cellulose) for 10 days and were challenged with CCl_4 2 ml/kg/SC (40% v/v in olive oil) on 8th day.* ***Group III*** *(HDN: 100 mg/kg): rats received HDN continuously for 8 days. On 8th day, they received CCl_4 2ml/kg/SC in olive oil. HDN was further continued for 2 more days.* ***Group IV*** *(HDN: 200 mg/kg): rats received HDN continuously for 8 days. On 8th day, they received CCl_4 2ml/kg/SC in olive oil. HDN was further continued for 2 more days. After ten days of treatment, the following were assessed: liver enzymes, tumour necrosis factor –alpha, oxidant parameters as malondialdehyde and antioxidant parameters as glutathione, superoxide dismutase, and total antioxidant capacity. Histopathological examination of the liver tissues was conducted.*

Results: *Hesperidin in the dose of 100 and 200 mg/kg produced a significant decrease in the levels of liver enzymes, alanine aminotransferase (ALT) and aspartate aminotransferase (AST),tumour necrosis factor–alpha(TNF-α), and oxidant parameters as malondialdehyde (MDA). Antioxidant parameters as glutathione (GSH), superoxide dismutase (SOD), and total antioxidant capacity (T-AOC), also have shown significant increase. These findings were confirmatory to histopathology.*

Conclusion: *Hesperidin in a dose of 100 and 200 mg/kg offers significant protection against hepatotoxicity produced by CCl_4 in albino rats, but this protection is dose-dependent.*

KEYWORDS: *Hesperidin (HDN), Antioxidants, Hepatic Toxicity and CCl4.*

INTRODUCTION

The liver is the main organ involved in metabolism of biological toxins and medicinal agents. Such metabolism is associated with disturbance of hepatocyte biochemistry and generation of reactive oxygen species (**ROS**) **(Fernandez-Checa, and Kaplowitz, 2005).**

Oxidative stress, resulting from an imbalance in generation of free radicals and antioxidant defense molecules, affects biological macromolecules causing their structural alterations that lead to cell damage and death **(Ryter, *et al*., 2007).** This phenomenon is considered a major factor in the pathogenesis of a variety of liver diseases. In this regard, reduction of oxidative stress may be a good target for prevention and treatment of hepatic and renal toxicity **(Flora, 2007).**

This study aims at the investigation of the ability of Hesperidin (HDN) as antioxidant to retard development of acute hepatic and renal toxicity induced by CCL_4 in rat. In addition to histopathological examination, the following will be evaluated: liver enzymes, TNF-α, T-AOC in serum, markers of oxidative stress (oxidants and antioxidants) as MDA, GSH, and SOD in liver homogenate.

***Corresponding author:**

Dr. Asmaa Abdulaziz Ahmeedah Rabee

Department of Pharmacology & Toxicology,
Faculty of Pharmacy & Medicine,
Omar-Al-Mukthar University, Derna, LIBYA.
** E-Mail: draqmir@gmail.com*

DOI:

MATERIALS AND METHODS

Materials:

Experimental Animals: This study was conducted on 32 male albino rats. Their weight ranged between 160-200 gm. Rats were housed as 4 groups with 8 rats each in clean capacious macrolane cages under standard laboratory conditions.

Drugs: CCL_4 (*El-Nasser Pharmaceuticals chemical company, Egypt*) and Hesperidin (HDN: *Sigma, Aldrich*).

Chemicals: Saline (*El-Nasser Pharmaceuticals chemical company, Egypt*), Phosphate buffered saline (*Hi-media- Lab. Pvt. Inc., USA*), SOD, MDA and GSH reduced kits (*Biochemical Enterprise, Italy*), ALT/AST kits (*Centronic_Gmbh, Germany*) TNF-α, ELISA kit *(Ray Biotech, Inc., USA*), T-AOC assay kit, *(Cayman Chemical Company, USA).*

Experimental Design:

Animals were divided into (4) groups, each consisted of (8) rats. Animals were fed on commercial pellet food, water was supplied freely.

Group-I (Control negative): rats received 5% carboxymethyl cellulose orally (as a vehicle) for 10 days and were injected by olive oil subcutaneously in the 8th day **(Tirkey, *et al*., 2005).**

Group-II (Control positive): These animals received 5% carboxymethyl cellulose orally for 10 days and were challenged with CCl_4, 2 ml/kg/SC (40 % v/v in olive oil) on 8th day **(Mandal, *et al*., 2002).**

© 2012, JPR. All Rights Reserved

Group-III (HDN 100): These rats received HDN 100 mg/kg/PO daily for 10 days. On the 8th day they received CCl_4 2ml/kg/SC in olive oil once. HDN was further continued for 2 more days **(Tirkey, *et al.*, 2005).**

Group-IV (HDN 200): These rats received HDN 200 mg/kg/PO daily for 10 days. On the 8th day they received CCl_4 2ml/kg/SC in olive oil once. HDN was further continued for 2 more days **(Tirkey, *et al.*, 2005).**

Procedures:

Blood sampling: At the end of the experiment, rats were sacrificed and blood samples were collected from the retro-orbital vein of each animal, under light anaesthesia by diethyl ether, according to the method of **Cocchetto, and Bjornsson, (1983)**. Blood samples were then centrifuged and the serum from each animal was kept in epindorff tubes in the deep freezer at (**-20°C**) until analyzed for liver functions, TNF-α, and T-AOC.

Preparation of Liver homogenate: Animals were sacrificed; livers were immediately excised, rinsed from blood in ice cold saline and blotted dry by filter papers. Small piece of each liver was fixed in 10% phosphate-buffered formalin for histological examination. About 0.5 gm of each liver was homogenized by ultrasonic homogenizer in 5 ml ice-cold phosphate buffered saline (PBS) to obtain ultimately10% (w/v) whole liver homogenate **(Ezz, *et al.*, 2011).** The homogenate was centrifuged at 3000 rpm for 15 min and the resultant supernatant was stored at (**-20°C**) until used for determination of reduced Glutathione (GSH), Malondialdehyde (MDA), Superoxide dismutase (SOD).

Determination of liver function: Commercial kit Purchased from *(Centronic_Gmbh, Germany)* based on the method described by **Thomas, (1998)** was used for determination of ALT & AST activity.

Determination of serum tumor necrosis factor alpha (Pg /ml) by using rat specific ELISA kit (Cat#: ELR-TNFalpha-001)

Determination of serum total antioxidant capacity (µmol/l) by Koracevic, *et al.* (2001). The determination of T-AOC is performed by the action of antioxidants in the sample with a defined amount of exogenously provide hydrogen peroxide (H_2O_2).The antioxidants in the sample eliminate a certain amount of the provided H_2O_2.The residual H_2O_2 is determined calorimetrically by an enzymatic reaction with involves the conversion of 3,5,dichloro-2-hydroxy benzensulphonate to a colored product The absorbance were recorded spectro-photometrically immediately at 505 nm.

Determination of hepatic reduced glutathione (mg/g tissue): the method based on the reduction of 5, 5' dithiobis (2-nitrobenzoic acid) (DTNB) with glutathione (GSH) to produce a yellow compound. The reduced chromogen directly proportional to GSH concentration and its absorbance can be measured at 405 nm **(Beutler, *et al.,* 1963).**

Determination of hepatic superoxide dismutase activity (U/g tissue): this assay relies on the ability of the enzyme to inhibit the phenazine methosulphate-mediated reduction of nitroblue tetrazolium dye **(Nishikimi , *et al.,* 1972)**.

Determination of hepatic lipid peroxide (Malondialdehyde) (nmol/g tissue): it was determined colorimetrically according to **Ohkawa, *et al.*, (1979)**.

RESULTS

Serum levels of liver enzymes (AST and ALT) and TNF-α were significantly increased in group-II, but when treated with HDN (100 mg/kg/day) there was a significant decreased in activity of the two enzymes, The decrease in activities of the two enzymes was significant in rats treated with an increase HDN dose (200 mg/kg/day). Also hesperidin (100, 200 mg / kg/day) exerted a significant decrease TNF-α, Malondialdehyde level was increased significantly in rats treated with CCl_4 (group-II) and decreased significantly in rats treated with HDN (200 mg/kg/day). Glutathione, Superoxide dismutase, and total antioxidant capacity were decreased significantly in group-II and increased significantly in rats treated with HDN (100, 200 mg/ kg/ day) (table 1 and fig. 1).

Both doses of HDN have prominent prevention of hepatic damage which was assessed microscopically, but this prevention is dose dependent (fig. 4 and 5).

Table No. 1: Showing Comparison of Results of Biochemical Tests Among Groups (I, II, III and IV)

Groups / Parameters	**Group (I)** Control negative No CCL_4 No HDN n = 8	**Group (II)** Control positive CCL_4 NO HDN n = 8	**Group (III)** HDN (100 mg/kg) n = 8	**Group (IV)** HDN (200 mg/kg) n = 8
Malondialdehyde (nmol/gm tissue)	49.013 ± 1.03	82.763 ± 0.91	81.625 ± 0.68*	##50.2 ± 0.38
Glutathione (mg/gm tissue)	5.088 ± 0.06	2.88 ± 0.048	3.09 ± 0.067*	##5.025 ± 0.072
Superoxide dismutase (U/gm tissue)	107.888 ± 0.56	89.688 ± 0.45	90.863 ± 0.26*	##107.013 ± 1.77
AST (Aspartate aminotransferase) (IU/L)	48.725 ± 0.47	163.875 ± 2.99	#111.375 ± 1.78**	##71.375 ± 1.71*
ALT (Alanine aminotransferase) (IU/L)	38.5 ± 0.76	87.875 ± 1.46	#57.375 ± 1.28**	##46.5 ± 0.94*
TNF-α (Tumor necrosis factor-α) Pg /ml	35.75 ± 1.816	131.417 ± 3.150	#81.766 ±2.994**	#73.666 ±2.689**
T-AOC (Total antioxidant capacity) µmol/l	116.050 ± 2.024	35.400 ± 1.864	#56.566 ± 5.587**	##70.166 ± 2.734**

** means statistical significance at P < 0.05 as compared to group (I); n = number of rats; # means statistical significance at P < 0.05 as compared to group (II); ** means P < 0.001 which indicates high significance as compared to group (I); ## means P < 0.001 which indicates high significance as compared to group (II)*

© 2012, JPR. All Rights Reserved

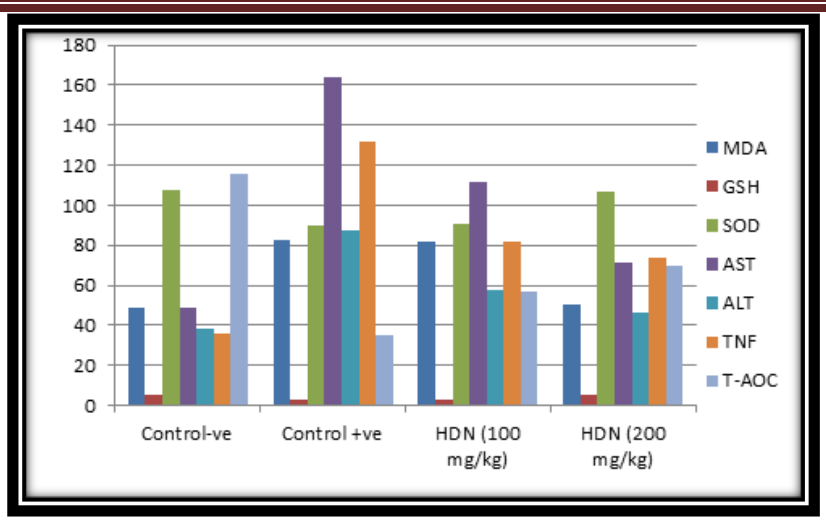

Fig. 1: Showing Comparison of Results of Biochemical Tests Among Groups (I, II, III and IV)

Histopathological Results:

Group (I) Control negative: were fed on 5% Carboxymethyl cellulose (as a vehicle) only for 10 days & were injected by olive oil S.C in the 8th day.

Normal (liver tissue, architecture, rows, cellular appearance and apparent nuclei) No "Inflammatory cell infiltrate" (Fig. 2).

Group (II) Control positive: fed on 5% Carboxymethyl cellulose (as a vehicle) only for 10 days & were injected by CCl_4 in olive oil (2 ml/kg) SC in the 8th day. Extensive damage, very severe vaculation, inflammatory cell infiltration, disruption of the lattice nature of hepatocytes and damaged hepatocyte cell membrane, irregular architecture (damaged sinusoids, rows and disintegrated central vein) & degenerated nuclei (Fg. 3).

Group (III)*:* treated with HDN as 100 mg/kg in the vehicle for 10 days and were injected by CCl_4 in olive oil (2 ml/kg) SC in the 8th day. Vaculation occurs but less than Control positive group, more eosinophilic infiltration than Control positive group (Fig. 4).

Better viability and less damage than Control positive group, nuclei are healthier than Positive Control group, less disruption of the lattice nature of hepatocytes and less damaged hepatocyte cell membrane, more regular architecture and rows than Control positive.

Group (IV): treated with HDN as 200 mg/kg in the vehicle for 10 days and were injected by CCl_4 in olive oil (2 ml/kg) SC in the 8th day.
Faded vaculation (very mild), architecture and rows are so close to normal, normal viability, less infiltration by the inflammatory cells than treated groups by (HDN100), normal nuclei and cell membranes, normal central vein and sinusoids (Fig.5).

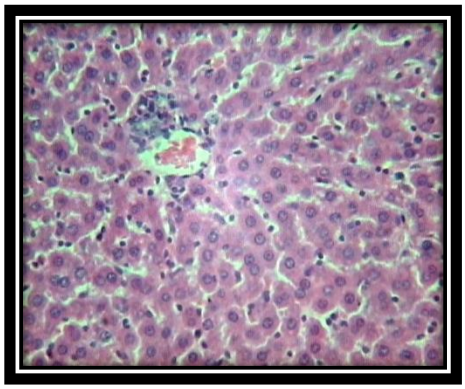

Fig. 2: Liver tissue of group (I: **Control negative)**

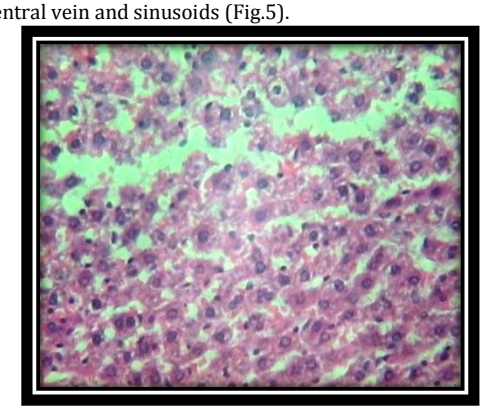

Fig. 3: Liver tissue of Group (II: Control **positive)**

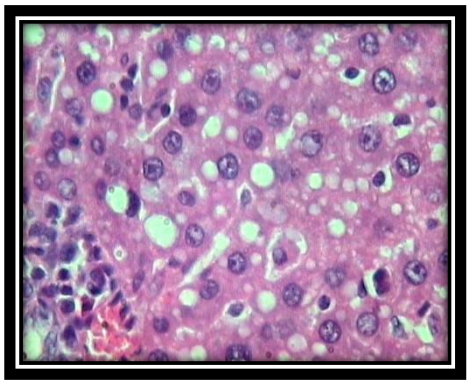

Fig. 4: Liver tissue of Group (III) treated with HDN (100 mg/kg)

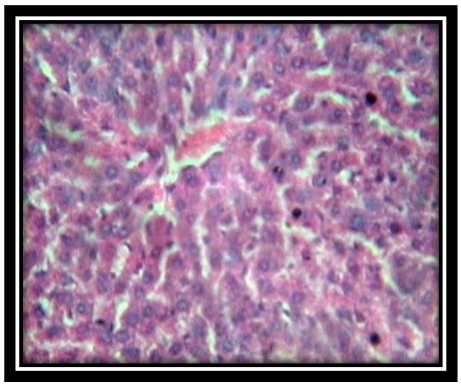

Fig. 5: Liver tissue of Group (IV) treated with HDN(200 mg/kg)

© 2012, JPR. All Rights Reserved

DISCUSSION

Hepatotoxicity Implies chemical-driven liver damage induced by certain medicinal agents and other chemical agents **(Ostapowicz, *et al*., 2002)**. Drug-induced liver injury is responsible for 5% of all hospital admissions and 50% of all acute liver failure **(Ostapowicz, *et al*., 2002 & McNally and Peter, 2006).**

There are increasing evidences that free radicals and reactive oxygen species play a crucial role in the various steps that initiate and regulate the progression of liver diseases independently of the agent in its origin **(Vitaglione , *et al*., 2004).**

Oxidative stress in hepatotoxicity, resulting from increased generation of reactive oxygen species (ROS) and other reactive intermediates as well as by decreased efficiency of antioxidant defences, actively contributes to excessive tissue remodeling **(Ismail, and Pinzani, 2009).**

In the present study, induction of acute hepatic toxicity in Wister male albino rats was done by SC injection of CCl_4 2 ml/kg (40% v/v in olive oil) characterized model for acute hepatic toxicity has been extensively performed and revealed microscopically in the liver as extensive damage, very severe vaculation, inflammatory cells infiltration, irregular architecture (damaged sinusoids, rows and disintegrated central vein) and degenerated nuclei (**Mandal, *et al*., 2002**).

These results are in agreement with the results obtained by **Al-Qarawi, *et al*., (2004)**, who reported the histopathological changes in acute hepatic toxicity by **Montilla, *et al*., (1990)**, who proved CCl_4 hepatotoxicity by 2 mL/kg/SC (LD50) of CCl_4, the modification of Nembutal-induced sleep, the action on bile flow, serum transaminase and hepatic fatty acids levels and a histopathological study of liver tissue**. Kodama, *et al*., (1990)** and **Prakash, *et al*., (2008),** have reported similar results to present study on the effect of CCl_4 on hepatic architecture**.** CCl_4, an industrial solvent, is a well-established hepatotoxin, **(Abraham, *et al*., 1999 & Gulmez, *et al*., 2003**) through free radical generation **(Gonzalez, *et al*., 1987**).

The mechanism of hepatotoxicity undergoes two phases. The first resulted from its metabolic conversion to trichloromethyl free radical (CCl_3^+) by cytochrome P450 mainly (CYP2E1 and CYP2B1) which react very rapidly with oxygen to produce more reactive trichloro-methylperoxy (CCL_3OO) free radical **(Vulimiri, *et al*., 2011)**. These free radicals attack microsomal lipids, DNA and proteins in the endoplasmic reticulum leading to initiating a chain of lipid peroxidation, cell necrosis and liver fibrosis **(Fang, *et al*., 2008**). CCl_4 not only initiates lipid peroxidation but also depletes tissue GSH and SOD **(Augustyniak, *et al*., 2005).**

Antioxidants such as vitamin E has been shown to be hepatoprotective molecules in animal models of acute toxicity where inflammation and fibrosis are primarily involved **(Galicia-Moreno, 2009)**, but might not be efficient on early signs of toxicity.

In the present study, CCl_4 induces a severe hepatic damage as represented by markedly elevated levels of ALT and AST. These results are in agreement with the studies **of Alam, *et al*., (2000); Mousa, *et al*., (2004) and Prakash, *et al*., (2008)** that reported administration of CCl_4 caused hepatotoxicity detected by increased levels of ALT and AST**.**

Usually, the extent of hepatic damage is assessed by increased level of cytoplasmic enzymes (ALT and AST). This was associated with massive centrilobular necrosis, ballooning degeneration and cellular infiltration of the liver **(Shankar, *et al*., 2012).**

According to **Abdel-sttar , *et al*., (2017)** a significant increase in serum tumor necrosis factor alpha (TNF-α) level. That is in harmony with these results, in the present study, injection of the rats with CCl_4 decreased the antioxidant capacity of liver as evidenced by the decreased GSH level and activities of SOD, and T-AOC, which is harmony with the results obtained by **Abdalla, *et al., (*2013)**

The results of the present study have been showed that; subcutaneous injection of CCl_4 lead to increase Malondialdehyde (MDA) level. These results are in agreement with the studies done by **Manjrekar, *et al*., (2008)** who found that CCl_4 causes decreased hepatic GSH level and increased MDA level.

The results of the present study are in contrast to **(Stryjecka-Zimmer, *et al*., 2003)** reported no changes in SOD and glutathione peroxidase (GPX) activities were observed in the liver after CCl_4 administration and explained that by the ability of the liver to cope with oxidative stress.

Indeed, oxidative stress, presumably by favouring mitochondrial permeability transition, is able to promote hepatocyte death (necrotic and/or apoptotic). In some of clinically relevant conditions, generation of ROS within hepatocytes may represent a consequence of an altered metabolic state (like in NAFLD and NASH), with ROS being generated mainly by mitochondrial electron transport chain or through the involvement of selected cytochrome P450 isoforms like (CYP2E1) **(Tilg, and Hotamisligil, 2006).**

The results of the present study showed that oral administration of HDN (100 mg/kg) and (200 mg/kg) significantly decrease the ALT and AST in CCl_4-treated rat and in the group of the dose (200 mg/kg) produces more decrease in ALT and AST. Also decrease in serum (TNF-α) level is in agreement with the results of **Abdel-sttar, *et al*., (2017)**, and of **Abdel-Monium *et al.* (2011)** who discussed that decreased in elevated TNF-α by hesperidin and naringin in diabetic rats along with their blood glucose lowering effect suggests that the immunomodulatory properties of both flavonoids .

Feng *et al.* (2011) and **Wang *et al.* (2010)** who found that the different flavonoid-rich extracts have the ability to decrease oxidative stress by promoting T-AOC, that is agreement with this result, which indicate the antioxidant properties of HDN.

The results of the present study are similar to the study done by **Ahmad, *et al*., (2012)** who proved that HDN ameliorates the hepatotoxicity-induced by acetaminophen and this was detected by decrease in ALT and AST not only that but also he noticed that the acuity of toxicity is decreased gradually by increasing the dose of HDN similar to this results.

Balakrishnan, and Menon, (2007) reported that administration of HDN to nicotine-treated rats at different doses decreases these enzymes significantly but in dose-dependent manner.

Anandan, and Ramaswamy, (2012) reported protective effects of HDN (100 mg/kg) for 14 days against Gentamycin-induced hepatotoxicity (GEN 100 mg/kg) for 8 days detected by decrease in ALT and AST.

Park, *et al.* (2012) who reported that protective effects of "HDN + Curdlan (CDN 100 mg/kg)" for 7 days against γ-radiation-induced hepatotoxicity.

CCl_4 induced a severe hepatic damage as represented by markedly elevated levels of ALT and AST coupled with a marked hepatic oxidative stress (**Tirkey, *et al*., 2005)**. Oxidative stress in hepatotoxicity, resulting from increased generation of reactive oxygen species (ROS) and other reactive intermediates as well as by decreased efficiency of antioxidant defenses, actively contributes to excessive tissue remodeling **(Ismail, and Pinzani, 2009).**

Hesperidin in combination with diosmin shows a marked protective effect against inflammatory disorders, both in *vivo* and in *vitro*, possibly through a mechanism involving an inhibition of eicosanoid synthesis and/or antioxidant free radical scavenger activity **(Jean, and Bodinier, 1994)**.

The results of the present study showed that oral administration of HDN (100 mg/kg) causes insignificant decrease in MDA and insignificant increase in hepatic GSH and SOD levels.

The results of the present study are similar to the study done by **Tirkey, *et al*. (2005)** who proved that; oral administration of HDN (100 mg/kg) causes insignificant decrease in MDA and insignificant increased hepatic GSH and SOD levels.

The results of the present study are in contrast to the study done by **Park, et *al*., (2012)** who observed protective effects of "HDN + CDN 100 mg/kg" for 7 days against γ-radiation-induced hepatotoxicity, through significant decrease in MDA and significant increased hepatic GSH and SOD levels.

The results of the present study showed that oral administration of HDN (200 mg/kg) causes significant decrease in MDA and significant increased hepatic GSH and SOD levels.

The results of the present study are in agreement with the study done by **Xiao-min**, ***et al*.,** (**2011)** who reported significant decrease in MDA and significant increased hepatic GSH and SOD levels by studying the protective effect of HDN on hepatotoxicity-induced by Cisplatin.

Wei, and Jun, (2010) reported that HDN had protective effects on CCl_4-induced chemical liver injury. It was possibly related to removal of free radicals and inhibition of lipid peroxidation. HDN (250

© 2012, JPR. All Rights Reserved

and 500 mg/kg) could reduce the levels of MDA and significant increased hepatic SOD level. **Wei**, **and Jun, (2010)**, also observed certain cytokines as (IL-1 and TNF) are inhibited by HDN (250 and 500 mg/kg) through decreasing mRNA expression.

Xiao-min, *et al.*, (2011) reported that administration of HDN (300 mg/kg P.O.) for 7 consecutive days had a remarkable protective effect on hepatotoxicity-induced by Cisplatin (5 mg/kg, intraperitoneally for 5 consecutive days from the third day of HDN administration).

The protective effect of HDN was possibly related to removal of free radicals and inhibition of lipid peroxidation produced by Cisplatin intoxication. HDN (300 mg/kg) could reduce the levels of MDA, significant increased hepatic SOD level and significant increased GSH. Also, **Tirkey, *et al*. (2005) & Pradeep, *et al.*, (2008)** obtained similar results to this study on the effect of Hesperidin on oxidants and antioxidants parameters**.**

Ko, *et al.*, (1995) reported that certain natural extracts containing antioxidants protect against the CCl_4-induced increased lipid peroxide levels and impairment in hepatic GSH status.

Hepatic MDA levels were also highly significantly increased in CCl_4 treated group, showing an increased oxidative stress compared to control group. The increased MDA level suggests enhanced lipid peroxidation leading to tissue damage and failure of antioxidant defense mechanisms to prevent formation of excessive free radicals as described by **(Pereira-Filho, *et al.*, 2008)** and this is confirmed by **(Kim, *et al.*, 2010).**

Glutathione is an important intracellular antioxidant that also plays a role in the detoxification and elimination of potential carcinogens and toxins. Studies in animals have found that glutathione synthesis and tissue glutathione levels are significantly lower in aged animals than in younger animals, leading to decreased ability of aged animals to respond to oxidative stress or toxin exposure (**Hagen, *et al.*, 2000)**.

SOD catalyzes the destruction of the O_2^- free radical ($2O^{2-} + 2H^+ \rightarrow O_2 + H_2O_2$). It protects oxygen-metabolizing cells against harmful effects of superoxide free-radicals **(Petkau, *et al.*, 1975)**

CCl_4 challenge significantly decreased the levels of SOD and catalase in liver, by alteration in gene expression and depletion of SOD and catalase levels **(Stryjecka-Zimmer, *et al.*, 2003)**.

Antioxidants are agents that inhibit or neutralize potentially harmful elements known as free radicals **(Zielinska, *el al.*, 2001 & Galati, and O'brien, 2004).**

Flavonoids are naturally occurring polyphenolic compounds in plants that are thought to have positive effects on human health **(Wahsha, and Al-Jassabi, 2009)**.

Hesperidin administration ameliorates the increased level of lipid peroxidation after CCl_4 treatment, able to show improvement in the levels of endogenous antioxidant enzymes SOD and improvement of hepatic GSH levels in HDN-treated rats in comparison to CCl_4 intoxicated rats, thereby, this demonstrates the antioxidant effect of HDN (**Tirkey, *et al.,* 2005**).

Flavonoids are known to operate via direct scavenging of ROS, chelation of redox active transition metal ions, inhibition of enzymes involved in ROS production, regeneration of endogenous antioxidants **(Fitzgeorge, *et al.,* 1994 & Zielinska, *et al.,* 2001)**. It was found that HDN has an important antioxidant activity in humans, it enhances the integrity of the blood vessels and it is found in great quantity in citrus fruits (lemons and oranges) **(Tripoli, et al., 2007)**.

Hesperidin and Silymarin are polyphenolic compounds which play an important role as antioxidants; they can directly quench free radicals, inhibit the enzymes of oxygen reduction pathways and also prevent the sequestration of transient metal actions **(Chatterjee, *et al.*, 1999 & Berker, *et al.*, 2007).**

The radical scavenging power of flavonoids is thought to be related to their structure. Flavonoids in general, scavenge oxidizing radicals preferentially via their B-ring catechol; in particular the ortho-dihydroxy structure in the B-ring gives a higher stability during the formation of aroxyl radicals and participation in electron dislocation. The presence of the 3' and 5' OH functions together give a maximum radical -scavenging potential; this property is found in both Silymarin and Hesperidin **(Markham, 1982; Joshi, *et al.,* 2005 & Andersen, and Markham, 2006).**

The results of the present study showed that; oral administration of HDN (100 and 200 mg/kg) significantly improves hepatic architecture microscopically in a dose-dependent manner as the group of HDN administration (100 mg/kg) shows slight improvement while the group of HDN administration (200 mg/kg) show no difference with control normal group.

This result is in agreement with the study done by (**Balakrishnan, and Menon, 2007)** who observed that administration of HDN to nicotine-treated rats at different doses improves hepatic architecture significantly in dose-dependent manner even in high doses, he doesn't observe any morphological changes compared to normal.

Ahmad, *et al.*, (2012) observed that HDN alleviates acetaminophen-induced toxicity in a dose-dependent manner and in high doses he doesn't observe any morphological changes compared to normal.

Also **Bentli, *et al.*, (2013)** obtained similar results to present study on the effect of HDN on hepatic architecture**.**

CONCLUSION

The present study suggested that the imbalance between production of oxygen free radicals and the endogenous antioxidant defense system, as a result of the effect of CCl4, so antioxidant properties of HDN might be the main factor responsible for its strong protective action on CCl_4-induced hepatotoxicity, through its ability to inhibit the lipid peroxidation and increase the activity of cellular antioxidant enzymes. Based on this study HND at these doses are safe and effective antioxidant also has cytoprotective property in dose depended manner.

REFERENCES:

Abdalla O, Engy F, Risha E and Elshopakey G. Hepatoprotective and Antioxidant Effects of Artichoke against Carbon Tetrachloride- Toxicity in Rats. Life Sci J **2013**;10(2):1436-1444.

Abdel-Moneim A, Ashour MB, Mahmoud AM and Ahmed OM. Insulin sensitizing effects of hesperidin and naringin in experimental model of induced type 2 diabetes in rats: Focus on tumor necrosis factor-alpha and resistin. Nat Sci **2011**;9(10):134-141.

Abdel-sttar AR, Khalaf MM, Aboyoussef AM and Abosaif AA. A ameliorative effect of hesperidin on carbon tetrachloride induced liver fibrosis in rats. Int J Pharm Pharm Sci **2017**;9(7):975–1491.

Abraham P, Wilfred G and Cathrine. Oxidative damage to the lipids and proteins of the lungs, testis and kidney of rats during carbon tetrachloride intoxication. Clin Chim Acta **1999**;289:177-179.

Ahmad ST, Arjumand W, Nafees S, Seth A, Ali N and Rashid S. Hesperidin alleviates acetaminophen-induced toxicity in Wistar rats by abrogation of oxidative stress, apoptosis and inflammation. Toxicol Lett **2012**;208(2):149-61.

Alam K, Al-Shabanah OA, Nagi MN, Al-Rikabi AC and Al-Bekairi AM. Protective effect of aminoguanidine, a nitric oxide synthase inhibitor, against carbon tetrachloride-induced hepatotoxicity in mice. Life Scisaceq **2000**;66:265-270.

Al-Qarawi AA, Mousa HM, Ali BH, Abdel-Rahman H and El-Mougy SA. Protective Effect of Extracts from Dates (Phoenix dactylifera L.) on Carbon Tetrachloride–Induced Hepatotoxicity in Rats. Int J Appl Res Vet Med **2004**;2(3).

Anandan R and Ramaswamy P. Effects of hesperidinon the levels of circulatory lipid peroxidation products and liver marker enzymes in gentamicin treated rats. J Pharm Res **2012**;5:2114-2116.

Andersen OM and Markham KR. Flavonoids: chemistry, biochemistry and applications. CRC Press, Boca Raton **2006**;19-25.

Augustyniak M, Babczynska A, Migula P, Wilczek G and Laszczyca P. Joint effects of dimethoate and heavy metals on metabolic responses in a grasshopper (Chorthippus brunneus) from a heavy metals pollution gradient. Comp Biochem Physiol **2005**;141C:412–419.

Balakrishnan A and Menon VP. Antioxidant properties of hesperidinin nicotine-induced lung toxicity. Fundam Clin Pharmacol **2007**;21(5):535-546.

Bentli R, Ciftci O, Cetin A, Unlu M, Basak N and Cay M. Oral administration of hesperidine, a citrus flavonone, in rats

© 2012, JPR. All Rights Reserved

counteracts the oxidative stress, the inflammatory cytokine production and the hepatotoxicity-induced by the ingestion of 2, 3, 7, 8-tetrachlorodibenzo-p-dioxin (TCDD). Eur Cytokine Netw **2013**;24(2):91-6.

Berker K, Guclu K, Tor I and Apak R. Comparative evaluation of Fe (III) reducing power-based antioxidant capacity assays in the presence of phenanthroline, batho-phenanthroline, tripyridyltriazine (FRAP) and ferricyanide reagents. Talanta **2007**;72:1157–1165.

Beutler E, Duron O and Kelly MB. Improved method for the determination of blood glutathione. J Lab Clin Med **1963**;16:882.

Chatterjee ML, Katiyar SK, Mohan RR and Agarwal R. A Flavonoid Antioxidant, Silymarin, Affords Exceptionally High Protection against Tumor Promotion in the SENCAR Mouse Skin Tumorigenesis Model1. Cancer Res **1999**;59:622–632.

Cocchetto DM and Bjornsson TD. Methods for vascular access and collection of body fluids from laboratoty rat. J Pharm Sci **1983**;72:465-492.

Ezz M, Hamdy G and Abd-El-Atti M. The Synergistic Hepatoprotective Effect of Curcumin A and Ginger Against Carbon Tetrachloride Induced- Liver Fibrosis in Rats. Aust J Basic & Appl Sci **2011**;(9):1962-1971.

Fang HL, Strom SC, Ellis E, Duanmu Z, Fu J, Duniec-Dmuchowski Z and Falany CN. Positive and negative regulation of human hepatic hydroxysteroid sulfo-transferase (SULT2A1) gene transcription by rifampicin: roles of hepatocyte nuclear factor 4alpha and pregnane X receptor. J Pharmacol Exp Ther **2008**;323:586-598.

Feng LJ, Yu CH, Ying KJ, Hua J. and Dai XY. Hypolipidemic and antioxidant effects of total flavonoids of Perilla Frutescens leavesin hyperlipidemia rats induced by high-fat diet. Food Res Int **2011**;(44):404–409.

Fernandez-Checa JC and Kaplowitz N. Hepaticmitochondrial glutathione: Transport and role in disease and toxicity. Toxicol Appl Pharm **2005**;204:263-273.

Fitzgeorge RB, Fitzgeorge SA and Keevil CW. Routes of intoxication. In: G.A. Codd, T.M. Jefferies, C.W. Keevil and C. Potter, Editors, Detection methods for cyanobacterial toxins. Royal Society Chem **1994**;69–74.

Flora S. Role of free radicals and antioxidant in health and disease. Cell Mol Biol **2007**;(53):1-2.

Galati G and O'brien PJ. Flavonoids and Isoflavones (Phytoestrogens): Absorption, Metabolism, and Bioactivity. Free Radi Biol & Med **2004**;37(3):287–303.

Galicia-Moreno M. N-acetylcysteine prevents carbon tetrachloride-induced liver cirrhosis: role of liver transforming growth factor-beta and oxidative stress. Eur J Gastroenterol Hepatol **2009**;21(8):908-914.

Gonzalez L, Perez AJ, Courel M and Sobrado J. Acute renal failure after topical application of carbon tetrachloride. Lancet **1987**;1:515-516.

Gulmez M, Guven A and Guven A. The effect of kefir on the activities of GSH-PX, GST, CAT, GSH, and LPO levels in carbontetrachloride – induced mice tissues. J Vet Med B Infect Dis Vet Public Health **2003**;50:412–416.

Hagen TM, Vinarsky V, Wehr CM and Ames BN. (R)-alpha-lipoic acid reverses the age-associated increase in susceptibility of hepatocytes to tert-butylhydroperoxide both in vitro and in vivo. Antioxid Redox Signal Fall **2000**;2(3):473-83.

Ismail MH and Pinzani M. Reversal of liver fibrosis. Saudi J Gastroenterol **2009**;15(1):72-9.

Jean T and Bodinier MC. Mediators involved in inflammation: effects of Daflon 500 mg on their release. Angiol **1994**;45:554-9.

Joshi G, Sultana R, Tangpong J, Cole MP, St Clair DK. and Vore M. Free radical mediated oxidative stress and toxic side effects in brain induced by the anti-cancer drug adriamycin: Insight into chemobrain. Free Radical Res **2005**;39(11):1147–1154.

Kim HY, Kim JK, Choi JH, Jung JY, Oh WY, Kim DC. Hepatoprotective effect of pinoresinol on carbon tetrachloride-induced hepatic damage in mice. J Pharmacol Sci **2010**;112(1):105-112.

Ko KM, Ip SP, Poon MKT, Wu SS, Che CT and Ng KH. Effect of lignan enriched Fructus schisandrae extract on hepatic glutathione status in rats: protection against carbon tetrachloride toxicity. Planta Med **1995**;61:134-137.

Kodama K, Oguchi K and Tsuji M. Protective effect of S-adenosyl-L-methionine against CCl4-induced hepatotoxicity in cultured hepatocytes. Jpn J Pharmacol **1990**;52(2):209-14.

Koracevic D, Koracevic G, Djordjevic V, Andrejevic S and Cosic V. Method forthe measurement of antioxidant activity in human fluids. J Clin Pathol **2001**;54(5):356–361.

Mandal AK, Sinha J, Mandal S, Mukhopadhyay S and Das N. Targeting of liposomal flavonoid to liver in combating hepatocellular oxidative damage. Drug Deliv **2002**;9:181-185.

Manjrekar A, Jisha P, Bag V, Adhikary P, Pai B and Hegde M. Effect of Phyllanthus niruri Linn. Treatment on liver, kidney and testes in CCl4 induced hepatotoxic rats. Ind J Exp Biol **2008**;46(7):514-520.

Markham KR. Techniques of Flavonoid Identification. Academic Press, London, **1982**;15-31.

McNally and Peter F. (2006): GI/Liver Secrets: with Student Consult Access. Saint Louis: C.V. Mosby, p: 618-7.

Montilla MP, Cabo J, Navarro MC, Risco S, Jiménez J. and Aneiros J. The protective and curative action of Withania frutescens leaf extract against CCl4-induced hepatotoxicity. Physiother Res **1990**;(4):212–215.

Mousa HM, Al-Qarawi AA, Ali BA and El-Mougy SA. Protective effect of extracts from dates (Phoenix dactylifera L.) On carbon tetrachloride–induced hepatotoxicity in rats. Int J Appl Res Vet Med **2004**;2(3).

Nishikimi M, Roa NA and Yogi K. Measurement of superoxide dismutase. Biochem Bioph Res Common **1972**;46:849-854.

Ohkawa H, Ohishi N and Yagi K. Assay for lipid peroxides in animal tissues by thiobarbituric acid reaction. Anal Biochem **1979**;95:351–358.

Ostapowicz G, Fontana RJ, Schiodt FV, Larson A, Davron JT, Steven HB, Timothy M and Reish J. Results of a prospective study of acute liver failure at 17 tertiary care centers in the United States. Ann Int Med **2002**;137:947–954.

Park SH, Pradeep K, Ko KC, Choi MH, Kang JA and Chung YJ. Hesperidin and Curdlan treatment ameliorates γ-radiation induced cellular damage and oxidative stress in the liver of Sprague-Dawley rats. J Med Food **2012**;15(5):419-427.

Pereira-Filho G, Ferreira C, Schwengber A, Marroni C, Zettler C and Marroni N. Role of N-acetylcysteine on fibrosis and oxidative stress in cirrhotic rats. Arq Gastroenterol **2008**;45(2):156-162.

Petkau A, Chelack W, Pleskach S, Meeker B and Brady C. Radioprotection of Mice by Superoxide Dismutase. Biochem Biophys Res Commun **1975**;65:886.

Pradeep K, Park SH and Ko KC. Hesperidin a flavanoglycone protects against gamma-irradiation induced hepatocellular damage and oxidative stress in Sprague-Dawley rats. Eur J Pharmacol **2008**;10;587(1-3):273-280.

Prakash T, Fadadu SD, Sharma UR, Surendra V and Goli D. Hepatoprotective activity of leaves of Rhododendron arboreum in CCl4 induced hepatotoxicity in rats. J Med Plants Res **2008**;2(11):315–320.

Ryter E, Kim H, Hoetzel A, Park J, Nakahira K and Wang X. Mechanisms of cell death in oxidative stress. Antioxid Redox Signal **2007**;(9):49-89.

Shankar M, Gowrishankar NL, David Raj C, Ansar MD, Pranathi P and Raju G. Screening of Methanolic Extract of Eugenia Jambolana Leaves for its Hepatoprotective Activity in Carbon Tetrachloride Induced Rats. Int J Appl Res in Nat Prod **2012**;5(2):14-18.

Stryjecka-Zimmer M, Szymonik-Lesiuk S, Czechowska G, Słomka M, Madro A and Celiński K. Catalase, superoxide dismutase, and glutathione peroxidase activities in various rat tissues after carbon tetrachloride intoxication. J Hepatobiliary Pancreat Surg **2003**;10(4):309-15.

Thomas L. Alanine aminotransferase (ALT), Aspartate aminotransferase (AST). In: Thomas L., editor. Clinical Laboratory Diagnostic. 1st ed. Frankfurt: TH-Books veriagsgesellschaft, **1998**; P:55-65.

© 2012, JPR. All Rights Reserved

Tilg H and Hotamisligil GS. Nonalcoholic fatty liver disease: Cytokine-adipokine interplay and regulation of insulin resistance. Gastroenterol **2006**;131:934–945.

Tirkey N, Pilkhwal S, Kuhad A and Chopra K. Hesperidine, a citrus bioflavonoid, decreases the oxidative stress produced by carbon tetrachloride in rat liver and kidney. BMC Pharmacol **2005**;5:2.

Tripoli E, Guardia M, Giammanco S, Di Majo D and Giammanco M. Citrus flavonoids: Molecular structure, biological activity and nutritional properties: A review. Food Chem **2007**;104:466-479.

Vitaglione P, Morisco F, Caporaso N and Fogliano V. Dietary antioxidant compounds and liver health. Crit Rev Food Sci Nutr **2004**;44:575–586.

Vulimiri SV, Berger A and Sonawane B. The potential of metabolomic approaches for investigating mode(s) of action of xenobiotics. Case study with carbon tetrachloride. Mutat. Res **2011**;722:147–153.

Wahsha M and Al-Jassabi S. The role of Silymarin in the protection of mice liver damage against Microcystin-LR toxicity. Jord J Biol Sci **2009**;2(2):63–68.

Wang X, Hai CX, Liang X, Yu SX, Zhang W and Li YL. The protective effects of Acanthopanax senticosus Harms aqueous extracts against oxidative stress: Role of Nrf2 and antioxidant enzymes. J Ethnopharmacol **2010**;(127):424–432.

Wei L and Jun L. Protective Effects and Mechanisms of Hesperidin Against Acute Chemical Liver Injuries in Mice. China Papers **2010**;29.

Xiao-min Y, Jun-ge Q, Qing-zhi L, Hong-wei L, Guo-kang W and Quan-yi X. Comparative Effects of Baicalin and Hesperidin on Hepatotoxicity Induced by Cisplatin in Mice. J Liaoning Univ Trad Chin Med **2011**;6.

Zielinska M, Kostrzewa A, Ignatowicz E and Budzianowski J. The flavonoids, quercetine and isorhamnetin 3-O-acylglucosides diminish neutrophil oxidative metabolism and lipid peroxidation. Acta Biochimica Polonica **2001**;48(1):183–189.

How to cite this article:

Asmaa Abdulaziz Ahmeedah Rabee and Hassen A.H. Bennasir. HESPERIDIN (HDN) AN ANTIOXIDANT FLAVONOID PREVENTS CARBON TETRACHLORIDE (CCl4) - INDUCED HEPATIC TOXICITY IN MALE ALBINO RATS. J Pharm Res 2018;7(12):283-289.

Conflict of interest: The authors have declared that no conflict of interest exists.

Source of support: Nil

© 2012, JPR. All Rights Reserved