

## AGE CHANGES IN THE PUBIC BONE

### VI. THE INTERPRETATION OF VARIATIONS IN THE SYMPHYSEAL AREA

T. WINGATE TODD

*Anatomical Laboratory, Western Reserve University, Cleveland, Ohio*

#### CONTENTS

INTRODUCTION.....	407
HISTORICAL REVIEW.....	409
TYPES AND RANGE OF VARIATION.....	409
VARIATIONS IN TYPE OF SYMPHYSEAL METAMORPHOSIS	
The ventral rampart.....	410
The lower extremity.....	413
The upper extremity.....	414
VARIATIONS IN PRIMATE METAMORPHOSIS.....	415
VARIATIONS IN HUMAN AGE RELATIONSHIP.....	417
VARIATIONS IN PRIMATE AGE RELATIONSHIP.....	418
VARIATIONS IN SHAPE OF THE SYMPHYSEAL FACE.....	419
SUMMARY—SIGNIFICANCE OF VARIATIONS IN INTERPRETATION OF THE SYMPHYSEAL AREA.....	421

#### INTRODUCTION

At various stages in the demonstration of features characteristic of pubic metamorphosis, both in Man and in mammals generally, it has been necessary to call attention to the occurrence of variations from what I have defined as the normal. In the earlier part of the investigation before what one may term the typical manner of pubic metamorphosis and the normal order of sequence of its successive phases had become crystallized into definite form the number and variety of the variations themselves proved a constant source of discouragement and confusion. The disturbance which they repeatedly caused in the routine examination of specimens, the ever-recurring necessity of reverting to specimens already examined and recorded because of the doubt cast upon interpretation of observations by the appearance of another anomaly or variation, the delay of confidence in the final results occasioned by them, distressing as they all were, nevertheless ultimately gave point and assurance to the scheme finally evolved. This scheme

has been presented in former parts of this memoir. When I published the account of metamorphosis as illustrated by the male White pubis I drew attention to the occurrence of anomalies regarding both manner of pubic metamorphosis and time relationship (4 p. 315), but admitted that at that time no very clear explanation of the factors controlling pubic metamorphosis in either type or time had as yet presented itself to me. Further investigation was plainly necessary.

When I came to present the evidence for the male Negro-hybrid material I showed (5 p. 23) that anomalies in time relationship of pubic metamorphosis, whether of acceleration or of retardation, may in some cases be but one feature of a general anomalous time relationship common to the entire skeleton. I also showed that in certain instances the time anomaly was confined to the symphyseal area. A third type of cases occurs in which there are contradictory indications of skeletal age in the different parts of the skeleton. This was the natural development of the argument as originally foreshadowed in part I of the memoir. Further on I showed (5 pp. 36, 46) that the same anomalies in point of time present themselves in female pelvises of both White and Negro-hybrid Stocks. Scattered references to anomalies of shape are to be found in the discussions of both Stocks (4 p. 315; 5 pp. 61-63), but so far variation seemed to fall under the headings of time relationship and morphological shape only. As a matter of fact this was not the case. The importance of reviewing with equal care our mammalian material had already been impressed upon my mind by the occurrence of variations in actual building of the symphyseal outline. It appeared that these could be accounted for only after the conditions in at least the Anthropoids had been noted and viewed in the light of human metamorphosis. I therefore carefully refrained from bringing these cases into prominence until the whole evidence could be produced. To have brought them forward before would have been to cause confusion in the mind of the reader, comparable with that induced by these specimens in my own mind, without at the same time being able to supply the corrective of the more complete knowledge which living in the midst of the material permitted. Nevertheless I drew attention briefly to the variation in manner of building up the symphyseal outline in the discussion of phases IV, V, VI (4 pp. 306-308; 5 pp. 8-10).

The fact that pubic metamorphosis in the giant Anthropoids may follow one of two courses, especially in light of the typical Eutherian metamorphosis (6 pp. 388, 400) clearly gives the clue to the variation of human metamorphosis in respect of symphyseal outline. This will therefore be one of our chief concerns in the present paper.

## HISTORICAL REVIEW

As regards previous observations on variation of the symphyseal region in Man there is little to record. It is however profitable to refer briefly to the work by Aeby upon this subject (1).

In horizontal sections through the symphysis pubis Aeby noted the asymmetry of the symphyseal faces especially at the ventral margin. He suggests that description of these variations would be useless and unprofitable since they are governed by chance and not by rule. Aeby drew this conclusion because he saw the symphysis only in section. Had he been able to examine the entire symphyseal face it is probable that he would have recognized an underlying plan in the building up of the ventral margin.

Aeby refers to the description by Gurlt of complete or incomplete union at the symphysis pubis, the result of inflammatory reaction. This corresponds to our specimen No. 339 which has already been described (5 p. 59).

The effect of age and sex upon pubic metamorphosis cannot be included with our present knowledge under the heading of variations as Aeby included it. The fundamental importance of these factors in pubic metamorphosis has been sufficiently emphasized in previous sections of this work.

The three variations in shape of the symphyseal face noted by Aeby have been fully set forth (5 pp. 61-63) and it is unnecessary to do more than recall them. They are extreme vertical shortness of the symphyseal face, unequal height of the right and left faces, and difference in the sagittal curve of the surface, one face being convex in this direction and the other concave. We shall learn a little further on that these three variations are all phases of one type of anomaly.

The fact that the bony outline of the symphyseal face is formed of cancellous tissue in the young but covered by a compact shell in later years, as noted by Aeby (1 p. 10) cannot fall within the category of variations. This is a normal change which must occur in any bony surface on which there is even the slightest mobility of an adjoining tissue. It takes place in all cases of non-union of fractures and at the plane of demarcation between the two ossifications in such cases as os acromiale. Further discussion of this example of a general law of bone metamorphosis is unnecessary at this juncture.

## TYPES AND RANGE OF VARIATION

In previous statements relating to symphyseal variations age relationship and shape have been dwelt upon but as pointed out in the

introduction there is an equally important variation in type of the detail of metamorphosis which has been noted it is true but not clearly differentiated.

Again we have observed variation in age relationship at least in the Primates as well as in Man. These instances are recorded in Part V and are shown in the chart of age relationships which is reproduced once again in this article as Fig. 1.

We may then regard variations of the symphyseal region as separable into three classes:

Variations in type of metamorphosis.

Variations in age relationship of metamorphosis.

Variations in physical form of the symphyseal face.

No doubt examples of each of these classes could be identified throughout all mammalian orders had one sufficient material to draw upon. Here however we shall confine ourselves to Man and the Primates. Some examples would fall equally appropriately into more than one of the above classes.

#### VARIATIONS IN TYPE OF SYMPHYSEAL METAMORPHOSIS. THE VENTRAL RAMPART

There could be no better method of introducing the difference in type of symphyseal metamorphosis than by calling attention to the several features of Figs. 2 and 3. Fig. 2 illustrates the symphyseal area of No. 238, male, White, age 30. Fig. 3 portrays the same parts in No. 342, male, White, age 34. Both symphyses are in the same phase, namely VI for each shows the formation of a ventral margin but there is an essential difference between them. Whereas in No. 238 the ventral margin is growing by the gradual accretion of new bone to the site of the future margin, in No. 342 there is a definite rampart in course of development. This has been produced, as stated in previous sections of the work, by the extension of ossification from the upper and lower nodules aided by the appearance of independent ossicles along the line of the future ventral margin. In course of the formation of the ventral margin actual bony bridges are formed and under two of these on the left side pins have been thrust to demonstrate the fact that these are really bridges. It is the reason for the difference between these two types of metamorphosis that we are to investigate. As a matter of fact the type of No. 248 is much more common among examples of the White stock but the other type is by no means rare. All that one would say is that it is not so frequent as the second type.

In the description of the male White os pubis no marked distinction was drawn between these two types and both are well represented in Part I Plate III, which shows phase VI as found in the male White pubis. Indeed there are all manner of intermediate forms between extremes of the two types. One source of confusion at first was the tendency of those specimens possessing a well marked rampart in process of formation to be precocious. The ventral rampart, if it occurs, is very apt to form earlier than does the ventral margin in those cases in which the margin grows by simple accretion. At the moment however I desire to differentiate between the time relationship as such and the mode of formation of the ventral margin, leaving the former for discussion under the heading of variations in age relationship of metamorphosis.

A very striking example of rampart formation before the process is so far advanced as in Fig. 3 is shown in Fig. 4. This is a photograph from No. 764, male, Negro-hybrid, age 25. Again we dismiss the age relationship for the present. The extension of ossification from the extremities is clearly seen and there are independent ossifications along the line of the future rampart, already fusing with the symphyseal face.

Figs. 5, 6, 7. represent the condition of the ventral rampart after its fusion with the symphyseal face is complete.

Fig. 5 is from No. 635, male, White, age 32.

Fig. 6 is from No. 305, male, White, age 35.

Fig. 7 is from No. 459, male, White, age 50.

In these specimens there is no doubt whatever that the ventral margin has been formed by a rampart.

For an explanation of the occurrence of the ventral rampart we turn to Figs. 8 and 9 which are symphyseal face and ventral views respectively of No. 774, male, Negro-hybrid, age 22. As seen in Fig. 8 the ventral rampart is already completely formed and fused throughout with the symphyseal face which is still no further advanced than late phase II. The unusual character of this specimen has previously been commented upon (5 p. 17) but it remains now to emphasize its fundamental importance in interpretation of the ventral rampart. Fig. 9 shows how enormous is the upper nodule which extends outward to include the pubic tubercle. The size and shape of this upper nodule recall the features of the upper nodule in other Primates. In this regard the reader should compare this figure with Figs. 29 and 30 in Part V. The continuity of the ventral rampart with the epiphyseal ossification along the ischio-pubic ramus is also very clearly seen in spite of the constriction just beneath the symphyseal face. From this one would infer that

upper and lower nodule together with the ventral rampart are all morphologically comparable with the ischial epiphysis. They are certainly developed from ossific centers making their appearance in a single morphological plane. The ventral rampart and the extremities may therefore be regarded as epiphysial formations but when we begin to inquire further what is the nature of these epiphysial formations and what they are doing in this situation we launch ourselves upon a larger problem which must be postponed until a later page.

Undoubtedly the ventral rampart and extremities are epiphysial in nature and this explains why in their more perfect condition they tend to develop earlier than is typical of the phases with which they are respectively linked.

If this proposition is true, and there seems no valid reason to reject it, the ventral margin which develops by simple accretion of bony tissue is a retrogressive type of epiphysial formation. Also it follows that the more retrogressive it is the more tendency is there for it not to form at all. Now we have seen that quite frequently there is failure of the ventral margin to develop at the junction of its upper and middle thirds, and often the upper third including the upper nodule fails altogether to appear. All this is quite consistent and hangs together when it is correctly interpreted but if the connecting thread which runs through the entire series of variations has not been grasped and held securely there appears to be nothing but an unwieldy and chaotic mass of variations for which there is no significance.

Now let us pass one stage further and examine the nature of these epiphysial formations. It would be rather natural to regard a non-uniting symphysis with bilateral epiphysial centers of ossification as more primitive than a symphysis which fuses and presents a single median ossification, the median bar. That is to say one would be inclined to regard the human symphysis as more primitive than the fusing type of Anthropoid symphysis represented by Figs. 36 and 41 in Part V. From the history of the Eutherian symphysis as elucidated in Part V (6) we know that this is not the case. The human symphysis presents a reversion in its nonfusing character. And since the median bar is lost as such we must infer that the bilateral epiphysial ossification centers, from which develop the ventral margin and the extremities, represent this median bar once again resolved into its constituent parts. For, of course, it may be surmised that although the median bar is a single mass it ossifies from bilateral centers which quickly fuse in the more typical Eutherian mammal. For a full consideration of the principles

upon which this argument is built up one must refer the reader to the extended account of the mammalian symphysial area in Part V.

#### THE LOWER EXTREMITY

We have just noted that the ventral rampart and the extremities of the symphysial face are all epiphysial formations possessing a definite and important phylogenetic history. Our attention so far has been concentrated upon the ventral rampart. We must now examine the lower extremity in greater detail.

Figs. 10 and 11 show face and ventral views of No. 792, male, Negro-hybrid, age 23. No ventral rampart or margin has yet appeared. The shell of tissue which will form the upper nodule has not developed. But the lower extremity is present and is especially marked on the right side as shown by Fig. 10. The definite relationship of this lower extremity to the epiphysis of the ischio-pubic ramus is plainly demonstrated.

Figs. 12 and 13 illustrate the same point. They are corresponding views from No. 524, male, Negro-hybrid, age 24. The difference between this specimen and the last is that in this the epiphysial extension which forms the lower extremity is relatively greatly increased in size. Also the connection with the epiphysis is not nearly so clearly seen. The question as to whether the lower extremity is actually increased in this case or is relatively decreased in the last will be for the ensuing evidence to decide.

We have learned from Part V that the Primate symphysis probably early differentiated off from the typical Eutherian condition and that the main feature of this differentiation was the reduction in extent of the symphysis so that it became confined to the os pubis and probably not to the full length of that. In this process the lower nodule so typical of the generalized Eutherian symphysis was lost. It is not quite clear as to what happened to this nodule. That it was originally bilateral in nature is apparent and that it may readily revert sufficiently to retain for a long period the evidence of its bilateral nature is clear from Part V Plate III. Possibly it was lost altogether with the shortening of the symphysis, but it is probably safer to surmise simply that it disappeared as an entity and that the ordinary epiphysial formation along the ischio-pubic ramus took its place. In any event this epiphysis crept along the ramus until it encroached upon the os pubis and thus we find the lower extremity of all Primate symphysial faces completed by this epiphysis.

## THE UPPER EXTREMITY

The upper extremity of the symphysial face differs from the lower extremity in that it is much more erratic in the form of its development. In the later years of the second decade of life there may appear a bony nodule of epiphysial nature in the site afterward occupied by the upper extremity. In the early twenties this nodule fuses with the symphysial face but does not typically take on any marked growth until later in the third decade after the commencing delimitation of the lower extremity. But the method of formation of the upper extremity is exceedingly variable. Sometimes a very large nodule occurs, and when this happens the nodule is likely to proceed to form the upper extremity unusually early. In other cases there is no nodule formed but the upper extremity develops simply from accretion of bony tissue like the ventral margin. Again the upper extremity may never form at all. Such cases are more liable to occur in White than in Negroid stock.

Figs. 14 and 15 illustrate the large nodule. They are from No. 413, male, Negro-hybrid, age 22. The erratic nature of the nodule and its want of relationship to any other feature of the symphysial face are quite apparent in Fig. 14. In Fig. 15 the connection of the nodule with the epiphysial formations along the ischio-pubic ramus would never be suspected were it not for the preceding figures.

The problem of how to interpret the upper nodule when it occurs is not a difficult one. We have seen that the lower nodule was early lost in the Primate symphysis. This is the probable reason for never finding a corresponding large mass at the lower extremity of the symphysial face. The upper nodule like the ventral rampart represents a typical Eutherian structure. As the median bar becomes resolved into its bilateral elements so the upper nodule loses its single character and reverts to a bilateral structure. But whereas the loss of the lower nodule is characteristically a Primate feature the upper nodule tends to disappear in many orders. Thus in Carnivores, in Ungulates and in Rodents there is frequently absence of the upper nodule with consequent incomplete formation of the upper part of the symphysial area. In Man this incompleteness of formation is more characteristic of White than of Negro-hybrid stock.

Because of tendency to diminution or loss of the upper nodule there is an uncertainty about the time of its appearance or, what is the same in principle, irregularity in age relationship of the delimitation of the upper symphysial extremity. Hence the definition of the upper



extremity becomes a feature of symphyseal metamorphosis upon which no great confidence can be placed as regards age.

In the typical Eutherian mammal the lower nodule ossifies before the upper. But in the Primate the lower nodule is lost, nevertheless the lower extremity also typically commences to become defined first. The new character of the lower extremity together with the irregular nature of the upper nodule in its retrogression have somewhat confused the time relationships of delimitation of these two features. It is really surprising that they should be as reliable in relation to time as they actually are.

From the foregoing description we see that the only really permanent and constant features of the symphyseal face throughout the mammalian class are the dorsal margin and adjacent dorsal platform. One may therefore understand why these features present the most constant age relationships in pubic metamorphosis.

#### VARIATIONS IN PRIMATE METAMORPHOSIS

It may be the result of the relatively few observations upon the various orders of mammals compared with the large number possible upon Man that there seems to be a fair uniformity in type of symphyseal metamorphosis within each order. Yet in the body of Part V sufficient indication exists of differences in the orders Primates and Rodentia at least. The important consideration for explanation of these differences is the fact that in both of these orders the symphyseal area is undergoing retrogressive changes

So far as the Marsupials and the Carnivores are concerned the type of symphyseal metamorphosis is remarkably uniform. In these animals the symphyseal area probably closely resembles the primitive Eutherian type. In all Insectivora except the Menotyphla the symphyseal area is so specialized that the symphysis is either rudimentary or lost and therefore does not present itself for consideration. The Edentates again present a very specialized symphysis regarding which we have not enough evidence to form more than a speculative notion of its construction. It must also therefore be omitted from consideration. The symphysis of the Ungulates is peculiarly specialized and of no immediate service. Again, so far as the Artiodactyla and the Perissodactyla are concerned the type is practically uniform.

Among the Rodentia we meet with every type of symphysis from the typical Eutherian form represented by *Castor* and *Dolichotis* to complete absence of the symphysis as in certain species of *Microtus*. Interme-

diate in position is the Guinea-pig if the statement of Flower (3) that fusion does not occur at its symphysis be confirmed. If this is the case the Guinea-pig symphysis is in very much the same position as that of Man. We owe much to the work of Chapman (2) for information upon the really intermediate forms. In the Pocket Gophers (*Geomys*) and some few other Rodents some individuals possess a symphysis while others do not. Chapman found that all male specimens of *Geomys* have a "closed" pelvis whereas some females, but not all, have an "open" one. By this term it is meant that the two halves of the pelvis do not meet at a symphysis. The author states that he found no intermediate forms; either the bones met at the symphysis or the symphysis was entirely absent. From our point of view however the male specimens of *Geomys* (see Chapman's Fig. 4) are the real intermediate form, for in them the symphysis is reduced to an exceedingly small area. In spite of these marked differences in the Rodent symphysis we have not sufficient information upon the method of metamorphosis to deal in detail with variations in metamorphosis in the Rodentia although it is perfectly clear that the precise mode of formation must differ between, let us say, *Dolichotis* and *Microtus*.

There remains then the Primate symphysis for consideration. No distinction in type of metamorphosis is noted except the peculiarity shown by the Cercopithecidae (and *Hylobates*) in secondary approximation of the ischia, and the two forms of symphyseal formation found in the giant Anthropoids.

As regards secondary approximation of the ischia it has already been pointed out (6 pp. 376, 385, 392) that the involvement is a feature developing during post-natal life. It is so specialized a character that we need not refer further to it here.

The really important variation in metamorphosis among Primates is the difference in type among the giant Anthropoids. We find on the one hand a form of metamorphosis very similar to that typical of Man, and on the other a form which brings these animals into line with other and more typical Eutheria. The differences have been discussed in Part V. It now remains to associate them in their proper phylogenetic position. The more generalized form typified by *Gorilla* sp. B 624, Fig. 36 in Part V shows a median bar with large upper median nodule but no lower nodule. This last feature is explained by the loss of the lower nodule early in Primate evolution. This form of metamorphosis is exactly that shown by other Primates. From the study of such specimens as *Microcebus* B 434 it is apparent that both upper nodule

and median bar are formed from the union of bilateral centers of ossification. Sometimes as in *Gorilla* sp. B 239 (Part V, Plate 8, Fig. 39) the median bar is very short and on fusion of the symphyseal area all trace of it is lost. It may be that this is what has happened in Pan B 629 (Part V, Fig. 41). But in many instances no symphyseal fusion occurs and the symphyseal outline is built up precisely as in Man. In these cases there is no ventral rampart but the ventral margin is formed by simple accretion.

One can explain these two forms of metamorphosis only upon the ground that the second is more retrogressive or at least more specialized than the first. We have not so far seen any Anthropoid symphysis in which there is formed a ventral rampart such as occurs in Man but even in Man it is comparatively rarely that one finds plain indications of this, such as are figured in this article (Plate II). We possess only some twenty-five skeletons of giant Anthropoids but nearly eight hundred human skeletons. It is natural therefore that the range of variation in the Anthropoid pelves should not be so great or complete as in the human series. The second type of Anthropoid symphysis is unmistakably the same as the typical human form. The development of a ventral rampart in the human symphysis is equally clearly an effort to reproduce as closely as possible the first type of Anthropoid symphysis in which there develops a median bar.

#### VARIATIONS IN HUMAN AGE RELATIONSHIP

The previous sections have shown how intimately related to type of metamorphosis are the time relations of the several features. We have noted that the human symphyseal area is very different from the typical Eutherian area and is somewhat retrogressive. The oldest and least changed part is the dorsal margin and the surface immediately adjacent. These preserve the most constant time relations. Ventral rampart or margin and lower extremity are considerably changed and show therefore some variation in time relation especially marked in cases like No. 744 where the "epiphyseal" nature is particularly well retained. In such instances the character of the dorsal margin and area will prevent one being misled by the early appearance of the other features.

On the chart of mammalian age relationships (Fig. 1) I have marked with open circles the position of three of the more marked variations from the human normal, namely Nos. 267, 744 and 792. These are all examples of acceleration and like the corresponding examples of acceleration among other Primates they fall within or quite close to the range of Placental mammals.

The delay in commencement of pubic metamorphosis in Man is the only point in which he differs from other Primates and the fairly generalized (so far as their symphyseal region is concerned) Carnivores. There is at present no explanation of this except the quite vague one of lengthening out of childhood. The delay characterising human metamorphosis in the seventh and eighth phases may be more apparent than real. It may arise from the errors consequent upon the necessity of comparing a fused type of symphysis with one in which union does not occur. At least it is interesting and it is also quite significant that during phases IV, V and VI, namely the period of development of the ventral margin and extremities the curve of human metamorphosis should most closely follow that of other Primates. This fact materially strengthens the probability that the general interpretation of human pubic metamorphosis herein put forward is correct.

A series of photographs are presented to illustrate the precocity induced by retention of the ventral rampart. Figs. 16 and 17 are taken from No. 267, male, White, age 25. In them one sees the same features which are already recorded in No. 744 but much less clearly. Comparison of the two sets of photographs will at once demonstrate the similarity. Fig. 18 is from No. 495, female Negro-hybrid, age 25. Here again it is obvious that the development of a ventral rampart has resulted in unusually early completion of the symphyseal outline.

A less marked precocity with probably some stagnation of metamorphosis is exhibited in Fig. 19. This represents No. 360, male, White, age 30. The formation of the ventral rampart though incomplete has apparently ceased and the filling over of the cancellous tissue of the symphyseal face by a compact shell has also ceased.

This cessation of metamorphosis is still more distinctly shown in Figs. 20 and 21. These are from Nos. 307 and 210, male, White *cadavera* thirty-six and forty-eight years of age respectively. In spite of the occurrence of an upper nodule in both and the beginning of a ventral rampart in No. 307 all metamorphosis seems to have stopped. With cessation of metamorphosis there comes a waxy appearance over the symphyseal face. This appearance is quite characteristic and invariable. Its importance as a sign of non-activity will be constantly stressed in this series of investigations upon the skeleton.

#### VARIATIONS IN PRIMATE AGE RELATIONSHIP

We have seen in Part V that the same variations in time relationship are equally apparent in other Primates as in Man. The unusual pre-

cocity of our specimen of *Microcebus* B 434 has been remarked previously and there seems no legitimate reason for this acceleration. It does not appear that *Microcebus* should show much acceleration of metamorphosis over *Tarsius*. Yet because of the paucity of our material and the little known nature of both of these animals it is unprofitable to pursue this point further.

Again there seems at present no adequate reason for the acceleration of metamorphosis in the other examples shown on the chart (Fig. 1). These are *Lasiopyga* B 147, *Pygathrix* B 622, *Hylobates* B 160 and *Gorilla* B 626. In the *Gorilla* the acceleration cannot be set down to the type of symphyseal formation since no median bar is formed and no fusion takes place. The photograph (Part V, Fig. 34) shows marked vascularity of the symphyseal area but I have stated earlier in this memoir why one cannot accept Aeby's theory that such vascularity accelerates pubic metamorphosis.

A striking feature of the variation in age relationship in all Primates including Man is that when acceleration occurs it carries the time relationship no further than the bounds of the general Eutherian range. Likewise the retardations, which are not figured on the chart but may be found in the body of the memoir, only bring the individual mammalian symphysis closer in position on the chart to the curve for Man.

The subject of age relationship in the Mammalia generally has been touched upon several times before. At the moment I desire particularly to accentuate the intimate connection between acceleration of pubic metamorphosis, and phylogenetic history as indicated by variations in type of the metamorphosis itself.

#### VARIATIONS IN SHAPE OF THE SYMPHYSEAL FACE

We have now completed our survey of variations in type and in time relationship of metamorphosis but the series of observations would be incomplete were we to omit reference to variations in shape of the symphyseal face.

The normal shape of the symphyseal face in Man is very like that of other Eutheria in which marked specialization has not taken place. It is long and not very broad. Observations upon the relation of sex to the symphyseal shape are not in order at this juncture. In both sexes this elongated oval outline is quite characteristic but not invariable. In other mammals we have seen that as specialization towards reduction becomes more and more marked the symphyseal face shortens and broadens. In the *Artiodactyla* and the *Perissodactyla* the symphyseal

face presents an almost circular outline. We have learned that the human symphysis is specialized to a greater degree than that of any other Primate but by no means so far as the symphysis of many other Mammalia. We must expect therefore that anomalies of the human symphysis will occur which are further than usual from the typical Primate symphysis. These would be the antithesis of the variation in which a ventral rampart is formed. Since the human symphysis is plainly specialized towards reduction and separation of the constituent elements it is obvious that we must find anomalies in shape of the symphyseal face.

Fig. 22 shows the symphyseal face of No. 93, male, Negro-hybrid age 30. Instead of an elongated oval the face presents a rather reniform outline. This variety was very puzzling at first. It is not infrequent and it is always associated with acceleration in age relationship of metamorphosis. Actually however it is an early phase of the tendency to reduction in length and formation of a rounded symphyseal outline.

Fig. 23 is a photograph of No. 94, male, White, age 28. This time the extremely short and rounded symphyseal face is quite marked. Notwithstanding the smallness of the actual symphyseal articular area the original typical form of the symphysis still remains. Again there is acceleration in speed of metamorphosis. Both this and the foregoing specimen have been mentioned before (4 p. 315; 5 p. 63) but the essential significance of their shape could not be pointed out until after the evolution of the symphysis in the Mammalia had been presented.

Along with shortening of the symphysis there is also the tendency to failure of the pubic bones to meet in the middle line. We have noted that in *Galeopithecus*, *Gymnura* and other animals in which the symphysis is vestigial and the pubic surfaces do not meet the symphyseal faces are both rounded in outline and irregular in contour. Usually the contour of such specimens is convex, sometimes more so on one side than the other. We now turn to irregularities in contour as shown in human symphyses.

Fig. 24 shows the symphyseal faces of No. 226, female, Negro-hybrid, age 30. The elongated oval outline is still maintained although the symphyseal area is greatly reduced and metamorphosis has been accelerated. It is discussed in the section upon the female Negro-hybrid (5 p. 47). The left symphyseal face is convex in both directions whereas the right is concave.

This rare condition is again met with in No. 324, female, White, age 43. It is presented as Fig. 25. I have previously referred to it as a case of deformity (5 p. 33). Here the symphysis is not unduly shortened

and in consequence of the age one cannot discuss possible acceleration of metamorphosis. The right face again is concave and the left convex.

In continuation of the argument in the earlier paragraphs of this section we expect to find in some examples of the human symphyseal area evidence of specialization beyond that shown by the majority of specimens. It has been further shown that shortening with its associated acceleration of metamorphosis and irregularity of contour are related types of specialization not only in Man but in other mammals also.

#### RELATION OF SYMPHYSEAL VARIATION TO HUMAN STOCK

No attempt has been made in previous pages to indicate the percentage of different variations in the symphyseal region of Man. As a matter of fact this would be very difficult for there are fine gradations forming the intermediate stages between extreme conditions such as are figured in the present article. One could scarcely say where to draw any line of distinction between normal and abnormal.

Although there are many examples of relative short and broad symphysis in the reserve material the only strikingly variant specimens of this category are figured here. Similarly though there are numerous specimens which show evidence of a ventral rampart such as are presented here in Figs. 5, 6, 7, the sole examples in our collection which give clear and unmistakable proof of the morphological relationship of the ventral rampart are to be found in Plate II.

As to the frequency of these striking variations in different human stocks we have very little evidence. Actually they probably occur as often in the White as in the Negro-hybrid. Yet it is a fact that all the pronounced examples of ventral rampart occur in Negro-hybrids. In a former section of the memoir I have pointed out that the Negro-hybrid seems to differ from the White in that his symphyseal outline is always completed whereas in the White it is apt to be incomplete in the upper third of the ventral margin and the area of the upper extremity (5 p. 25). In these two respects the Negro-hybrid does, show in all probability, a tendency to retain a more typical Primate symphysis.

#### SUMMARY

##### THE SIGNIFICANCE OF VARIATIONS IN INTERPRETATION OF THE SYMPHYSEAL AREA

There is nothing new to add to what has already been stated in the foregoing pages. We have not considered all the varieties of the

symphysial region, human and mammalian, but we have taken note of those variations which, at this juncture in the investigation, plainly have some bearing upon the phylogeny and the present status of the human symphysis.

Variations in type of metamorphosis show the relation of the human symphysis to that of other Primates. Although no fusion ever occurs, except pathologically, and no median bar is ever formed in Man yet the ventral rampart and upper nodule clearly are derived from the Primate type of median bar.

The ventral rampart and the nodules, of the extremities, if they exist, are plainly epiphysial in nature but it is necessary to inquire further what is the nature of these ischio-pubic epiphyses. The answer to this query is given by the variations of symphysial metamorphosis themselves.

Variations in time relationship are closely related to variations in metamorphosis and, according to the type of metamorphosis, the variation in time relationship will bring the symphysial bone change into closer relationship with the typical Eutherian form or it will plainly show that there is a retrogression.

Variations in symphysial shape likewise fall into line with the other variations except that they naturally can only indicate the line of further retrogression which however is quite in harmony with the line which one would infer from a study of the mammalian symphysis in general.

As for any Stock-linked character in variations the evidence is not as yet very strong but there does seem to be some indication that the Negro-hybrid symphysis is apt to partake of a more typical Primate character.

Before ending this series of studies on the human and mammalian os pubis I desire to express my indebtedness to our prosecuting staff, Messrs Leonhart and Williams for the years of patient work in macerating and preparing skeletons by which such investigations as this are made possible. It is also fitting that I acknowledge to my colleague, Miss H. F. Harvey, my grateful appreciation of her tireless efforts and of the splendid results which she has achieved in this very special field of photography.

#### REFERENCES

1. Aeby (Ch.)—1858. Ueber die Symphyse ossium pubis des Menschen nebst Beiträgen zur Lehre von hyalinen Knorpel und seiner Verknöcherungen. *Z. f. ration. Med.*, Reihe 3, IV, 1-77.



2. Chapman (R. N.)—1919. A study of the Correlation of the Pelvic Structure and the Habits of Certain Burrowing Mammals. *Am. J. Anat.*, XXV, 185-208.
3. Flower (W. H.)—1885. *OSTEOLOGY OF THE MAMMALIA*. London, 3rd Ed.
4. Todd (T. W.)—1920. Age changes in the Pubic Bone. I. The Male White Pubis. *Am. J. Phys. Anthropol.*, III, 284-334.
5. Todd (T. W.)—1921. Age changes in the Pubic Bone; II, III, IV. *Am. J. Phys. Anthropol.*, IV, 1-69.
6. Todd (T. W.)—1921. Mammalian pubic metamorphosis; V. *Am. J. Phys. Anthropol.*, vol. IV, 333 *et. seq.*

#### LEGENDS

FIG. 1. Chart to show age relationships of symphyseal metamorphosis in various orders of mammals including Man. The black dots represent Primate specimens showing acceleration. The black circles indicate the extreme position of specimens showing acceleration in Man. This is also reproduced as Fig. 45, Part V.

#### PLATE I.

FIG. 2. No. 238, male, White, age 30. Usual type of human metamorphosis.

FIG. 3. No. 342, male, White, age 34. Formation of ventral rampart.

FIG. 4. No. 764, male, Negro-hybrid, age 25. An earlier stage of development of the ventral rampart.

FIG. 5. No. 635, male, White, age 32.

FIG. 6. No. 305, male, White, age 35.

FIG. 7. No. 459, male, White, age 40.

These three figures show the ventral rampart at various stages after completion.

#### PLATE II.

FIGS. 8, 9. No. 744, male, Negro-hybrid, age 22.

FIGS. 10, 11. No. 792, male, Negro-hybrid, age 23.

FIGS. 12, 13. No. 524, male, Negro-hybrid, age 24.

These figures show symphyseal face and ventral views of three pelves which clearly indicate the nature of the ventral rampart and lower extremity.

#### PLATE III.

FIGS. 14, 15. No. 413, male, Negro-hybrid, age 22.

These figures show how the upper extremity is related to the upper nodule characteristic of the Eutherian symphysis.

FIGS. 16, 17. No. 267, male, White, age 25.

FIG. 18. No. 495, female, Negro-hybrid, age 25.

FIG. 19. No. 360, male, White, age 30.

These four figures show how accelerated is metamorphosis when a ventral rampart develops.

#### PLATE IV.

FIG. 20. No. 307, male, White, age 36.

FIG. 21. No. 210, male, White, age 48.

These figures show stagnation of metamorphosis. Note the characteristic waxy appearance of the symphyseal face.

FIG. 22. No. 93, male, Negro-hybrid, age 30.

FIG. 23. No. 94, male, White, age 28.

These two figures show reniform and short symphyses, both forms of the same process.

FIG. 24. No. 226, female, Negro-hybrid, age 30.

FIG. 25. No. 324, female, White, age 43.

These two figures show irregularity in contour of the symphysial faces, a deformity closely linked in origin with symphysial shortening.

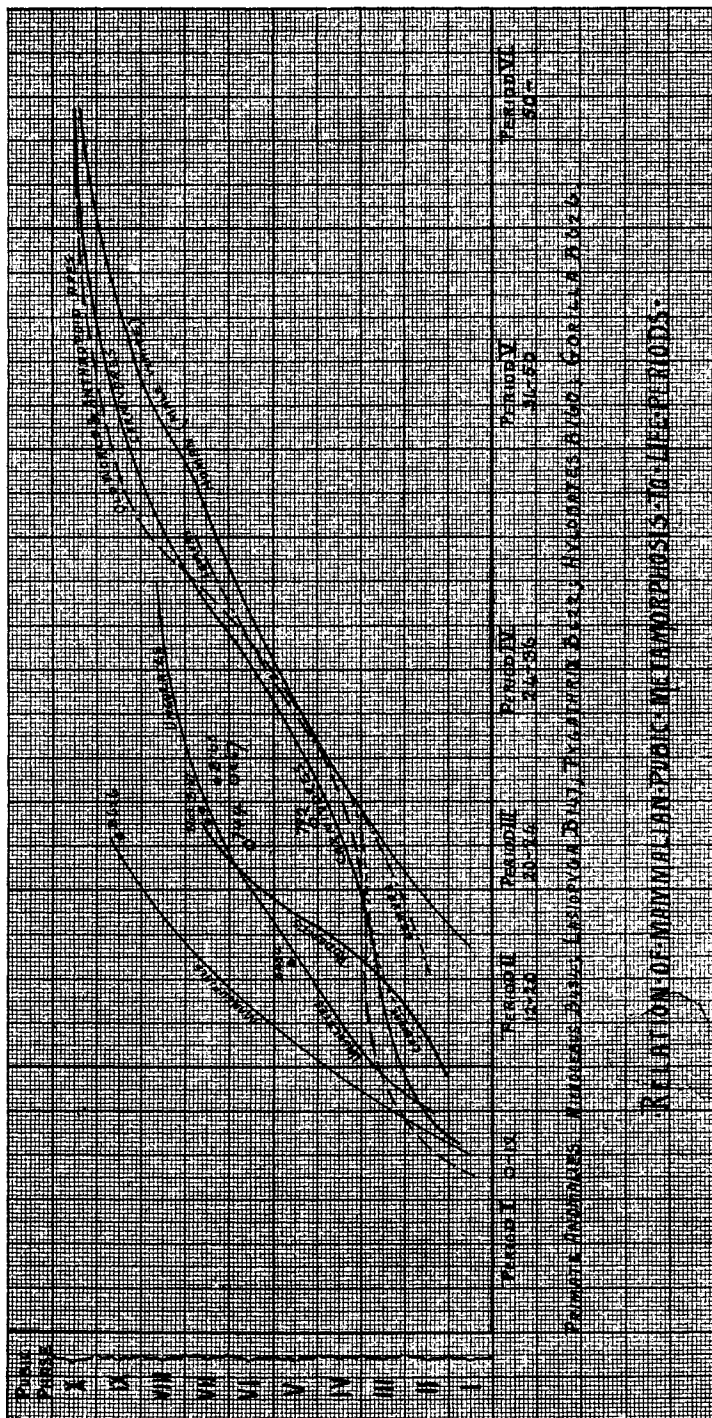


FIG. 1

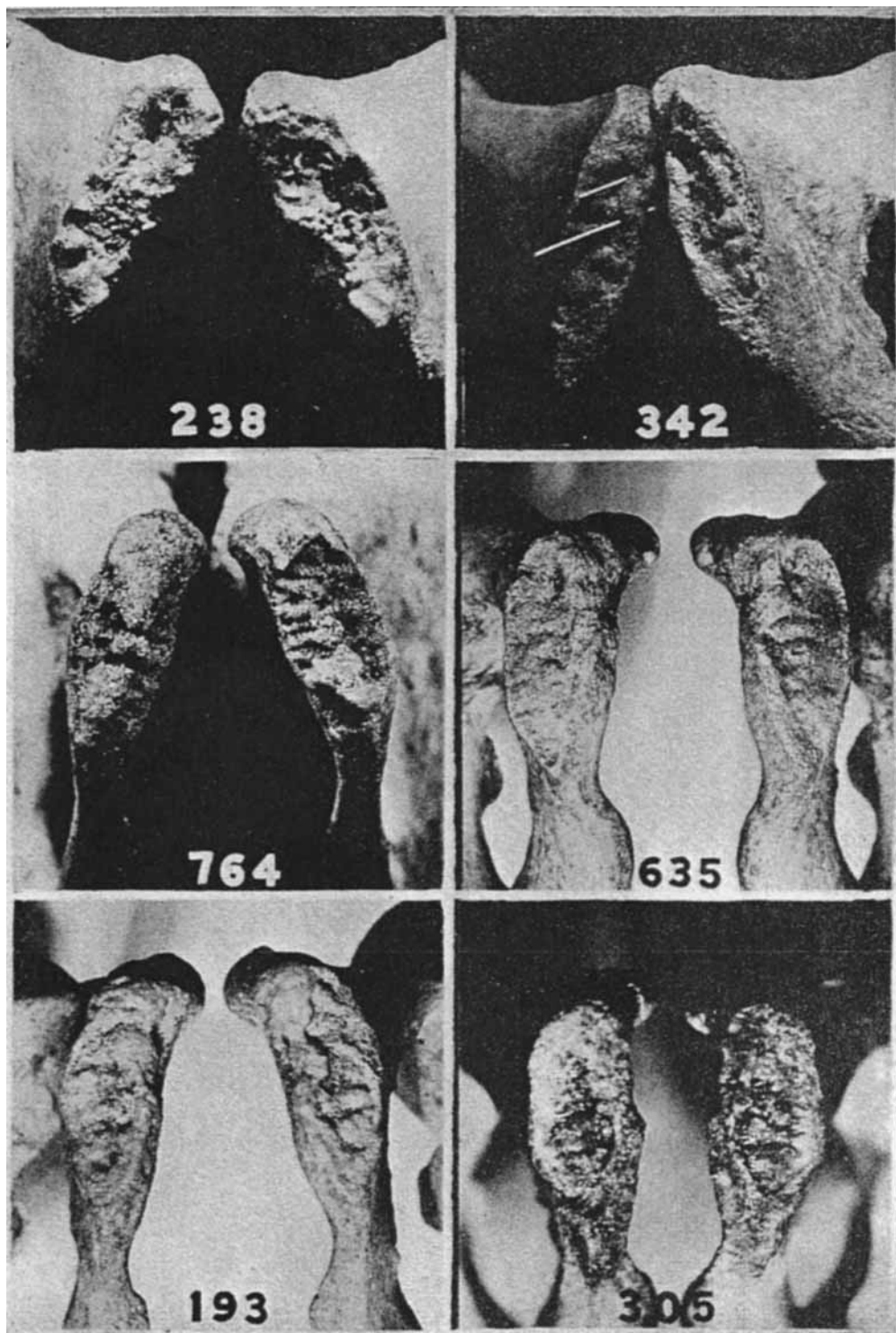
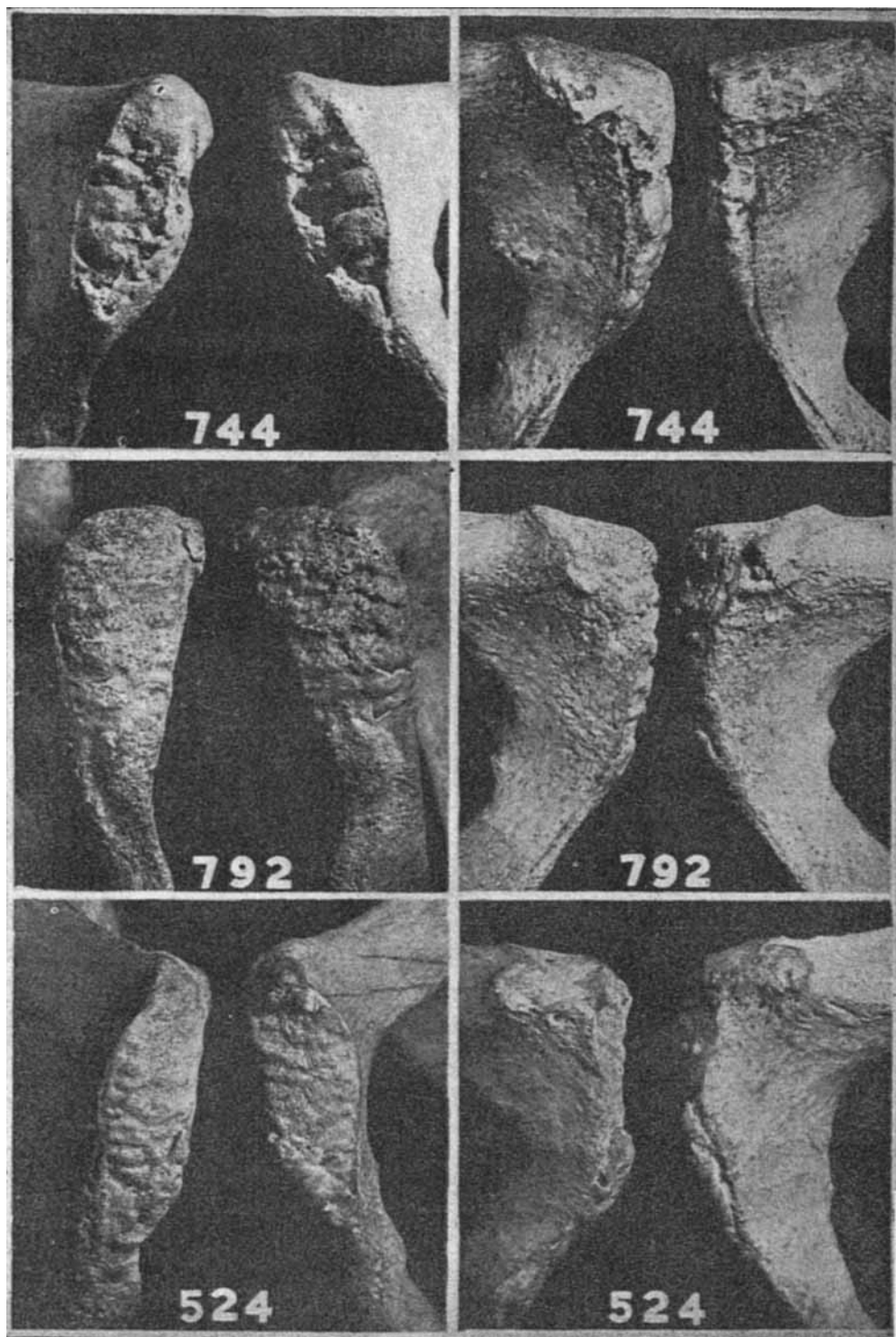


PLATE I

Top row, Figs. 2, 3.

Middle row, Figs. 4, 5.

Lowest row, Figs. 6, 7.

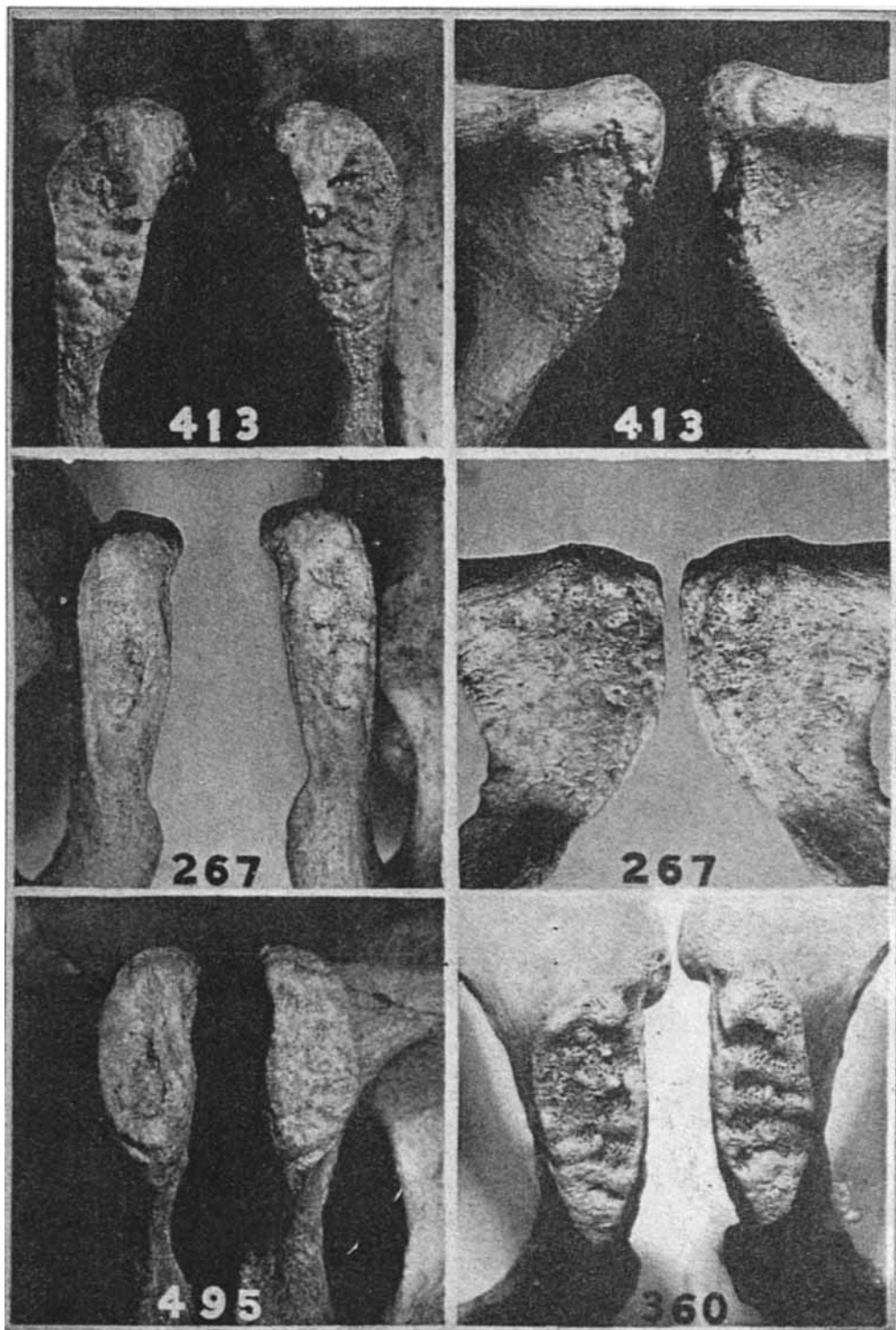


# PLATE II

Top row, Figs. 8, 9.

Middle row, Figs. 10, 11.

Lowest row, Figs. 12, 13.



### PLATE III

Top row, Figs. 14, 15.

Middle row, Figs. 16, 17.

Lowest row, Figs. 18, 19.

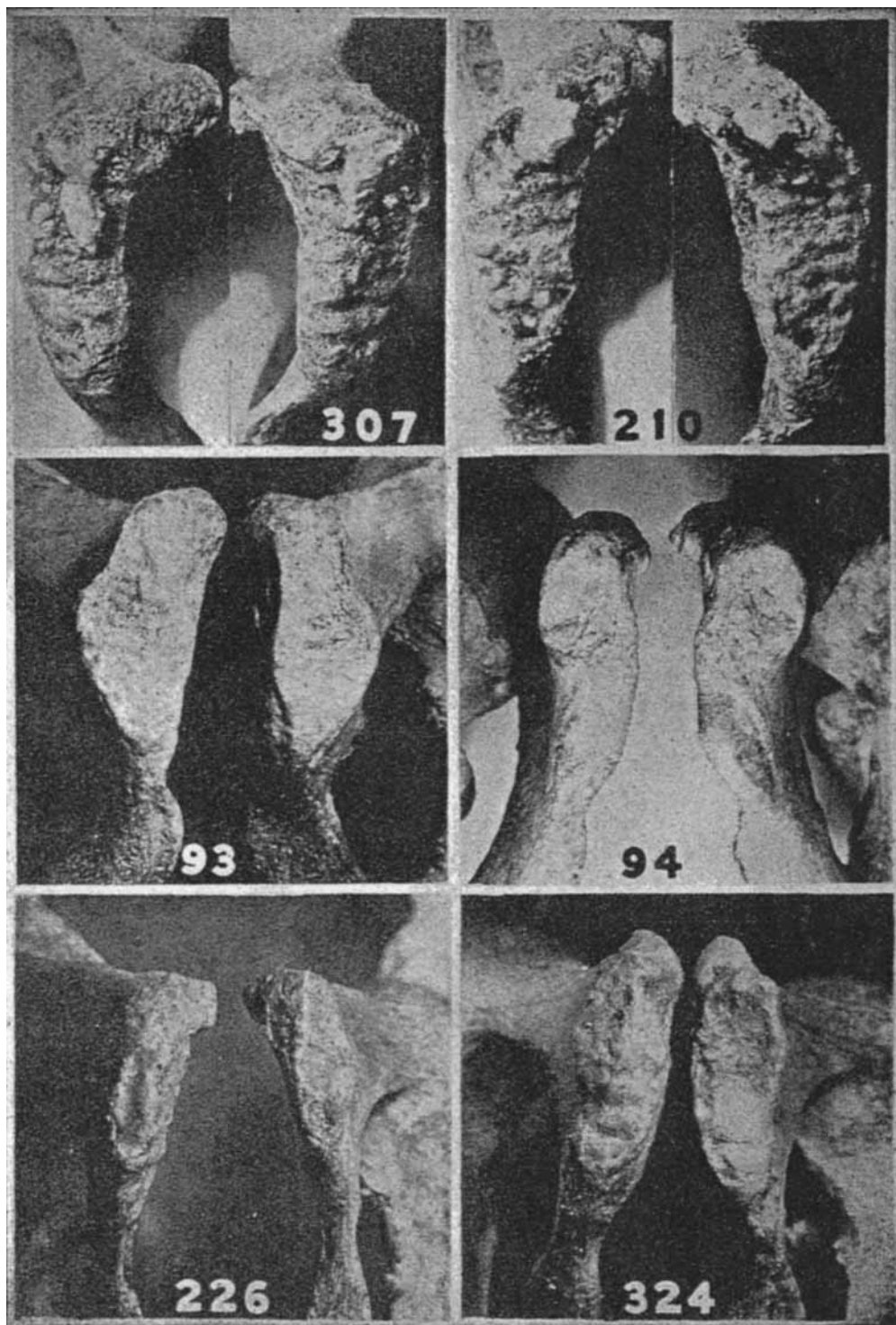


PLATE IV

Top row, Figs. 20, 21.  
 Middle row, Figs. 22, 23.  
 Lowest row, Figs. 24, 25.