

NCT02592655 Primary Outcome Tourniquet Study

Instructions to the outcome assessor:

You have been blinded to this study. The identity of the subject, the identity of intervention, and the sequence of the intervention have been intentionally concealed from you. Ultrasound images have been labeled with a four-digit blinding code. As the outcome assessor, you are asked to evaluate each ultrasound image as being indicative of the presence or absence of pulsatile arterial flow.

Below each image, you are asked to select one of the following options.

- FLOW, Pulsatile arterial flow is present.
- or
- OCCUSION, Pulsatile arterial flow is absent.

A free text box accompanies each image for optional comments.

Outcome Assessor Information and Signature

Signature: 
Ralph J. Perrico III MD (Jun 1, 2016)

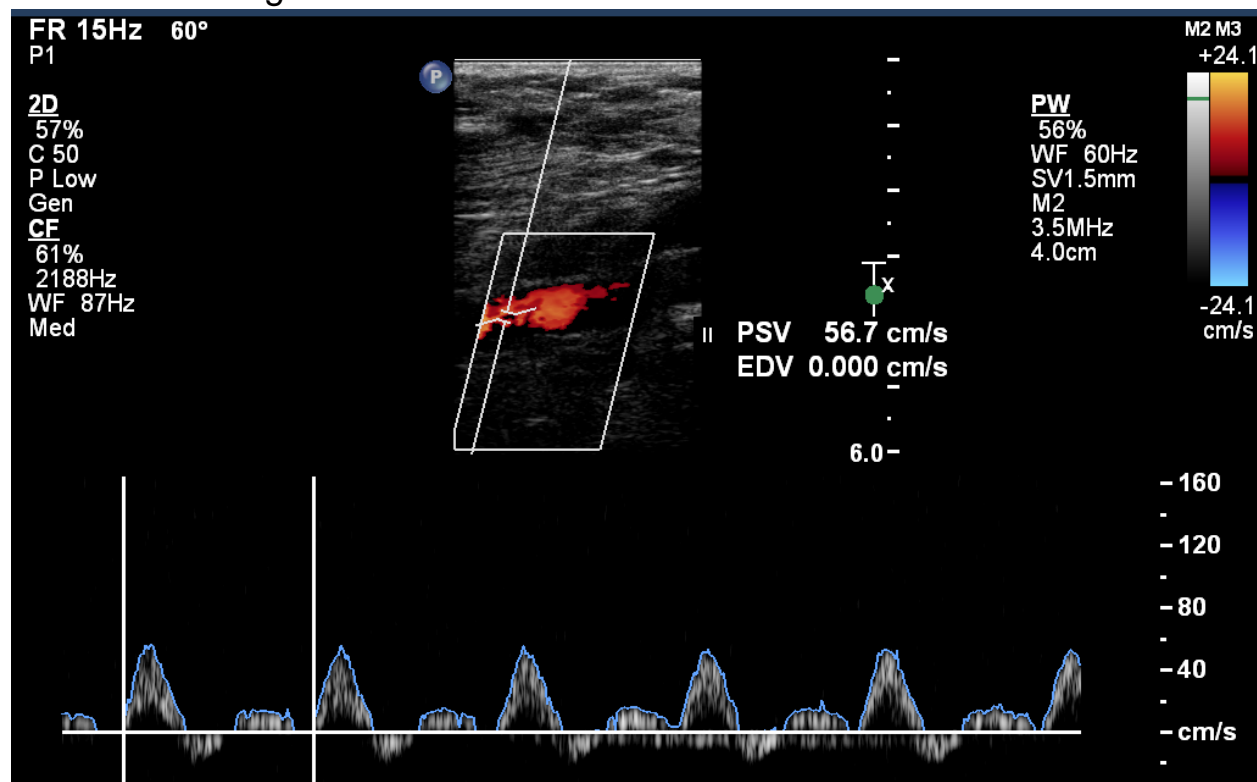
Email: rjp@neomed.edu

Ralph J Perrico III MD
E-signed 2016-06-01 04:10AM EDT
rjp@neomed.edu



Adobe Sign Transaction Number: CBJCHBCAABAAAdPZA3dC2kfL6y7HBiSEbMg2FU4tWDGN

Ultrasound Image 1008



Assessment for ultrasound image coded 1008

FLOW, Pulsatile arterial flow is present.

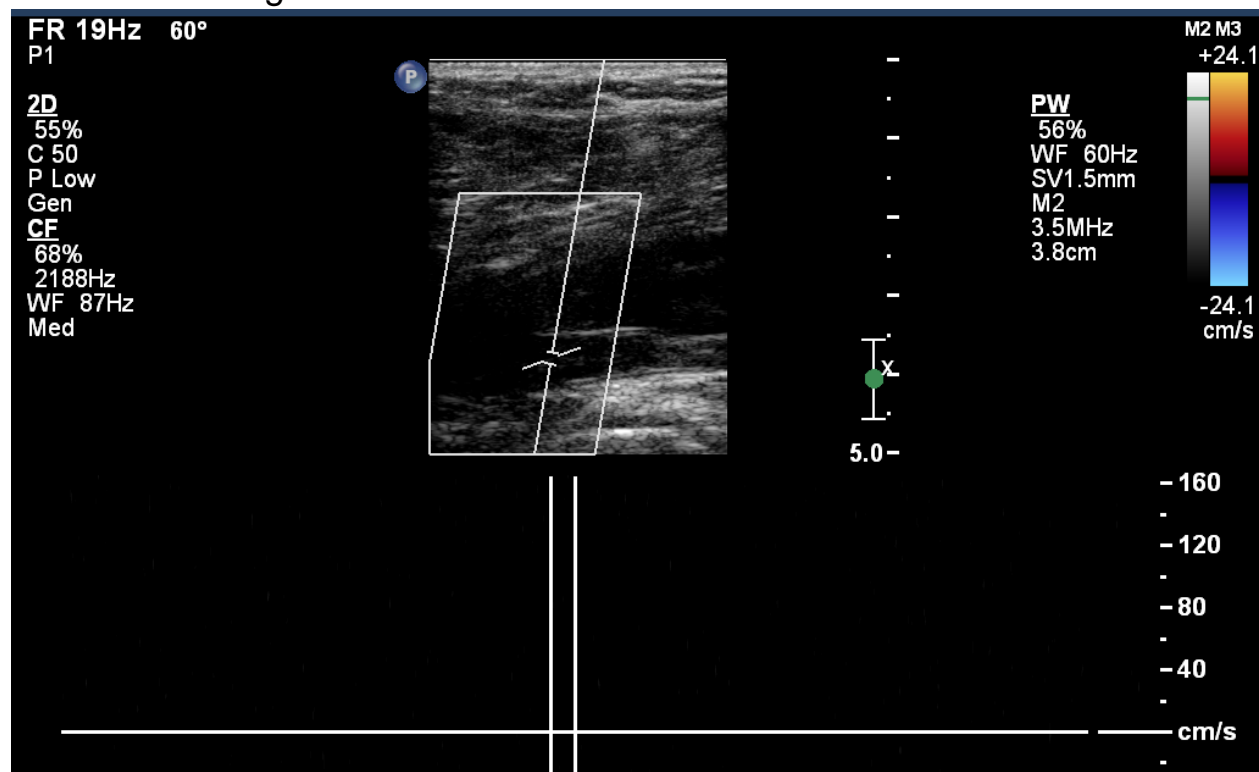
Ralph J Perrico III MD

E-signed 2016-06-01 04:10AM EDT

rjp@neomed.edu



Ultrasound Image 1184



Assessment for ultrasound image coded 1184

OCCLUSION, Pulsatile arterial flow is absent.

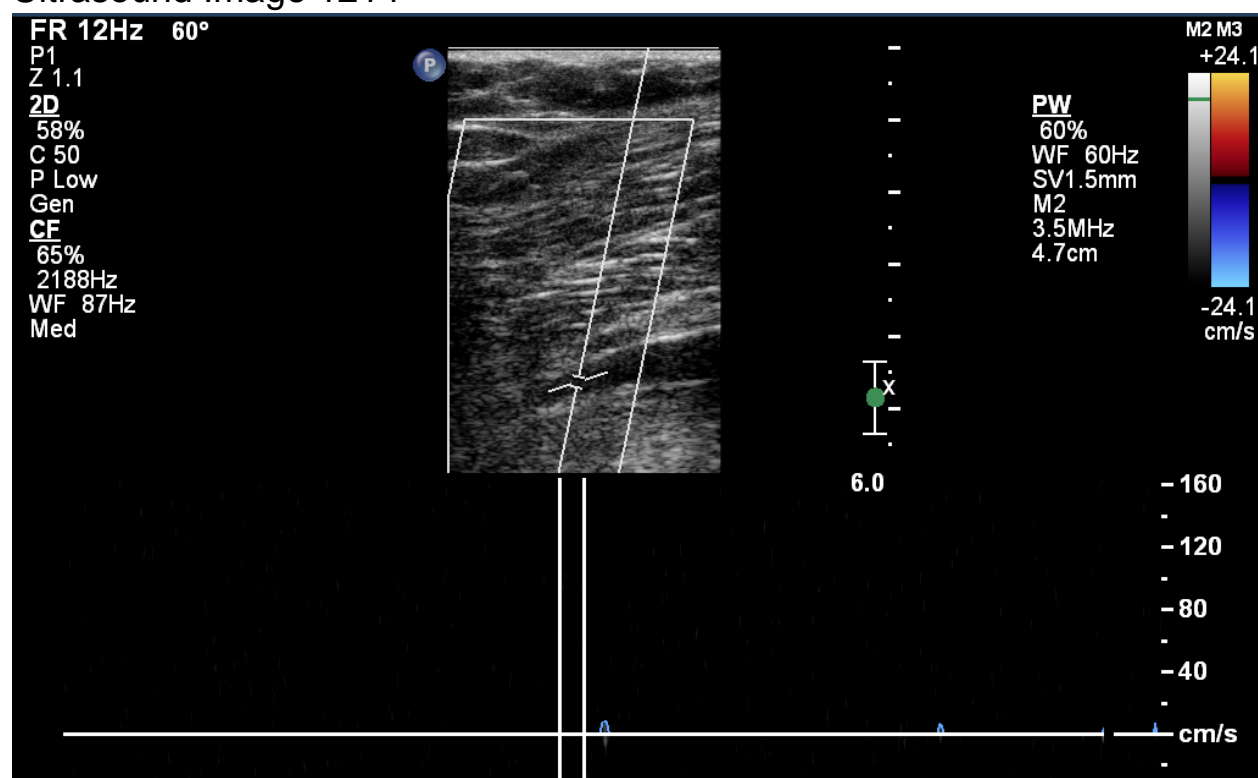
Ralph J Perrico III MD

E-signed 2016-06-01 04:10AM EDT

rjp@neomed.edu



Ultrasound Image 1214



Assessment for ultrasound image coded 1214

OCCLUSION, Pulsatile arterial flow is absent.

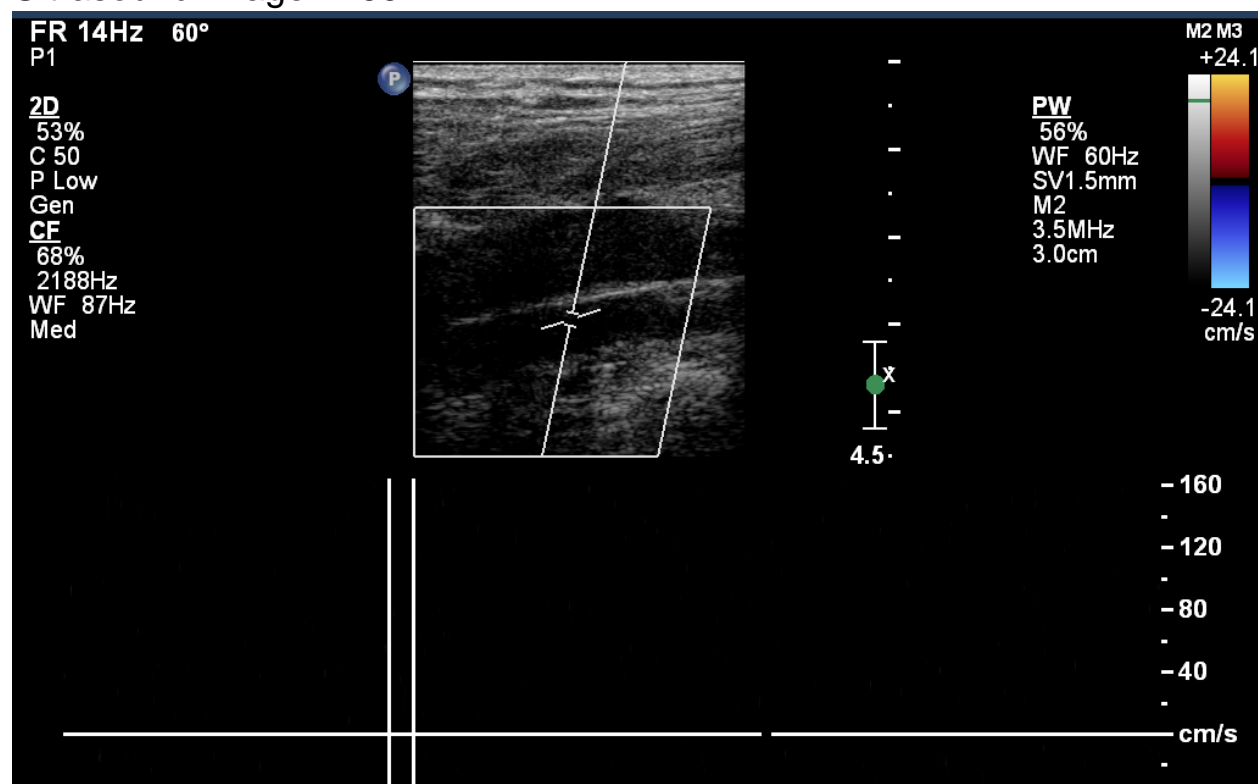
Ralph J Perrico III MD

E-signed 2016-06-01 04:10AM EDT

rjp@neomed.edu



Ultrasound Image 1266



Assessment for ultrasound image coded 1266

OCCLUSION, Pulsatile arterial flow is absent.

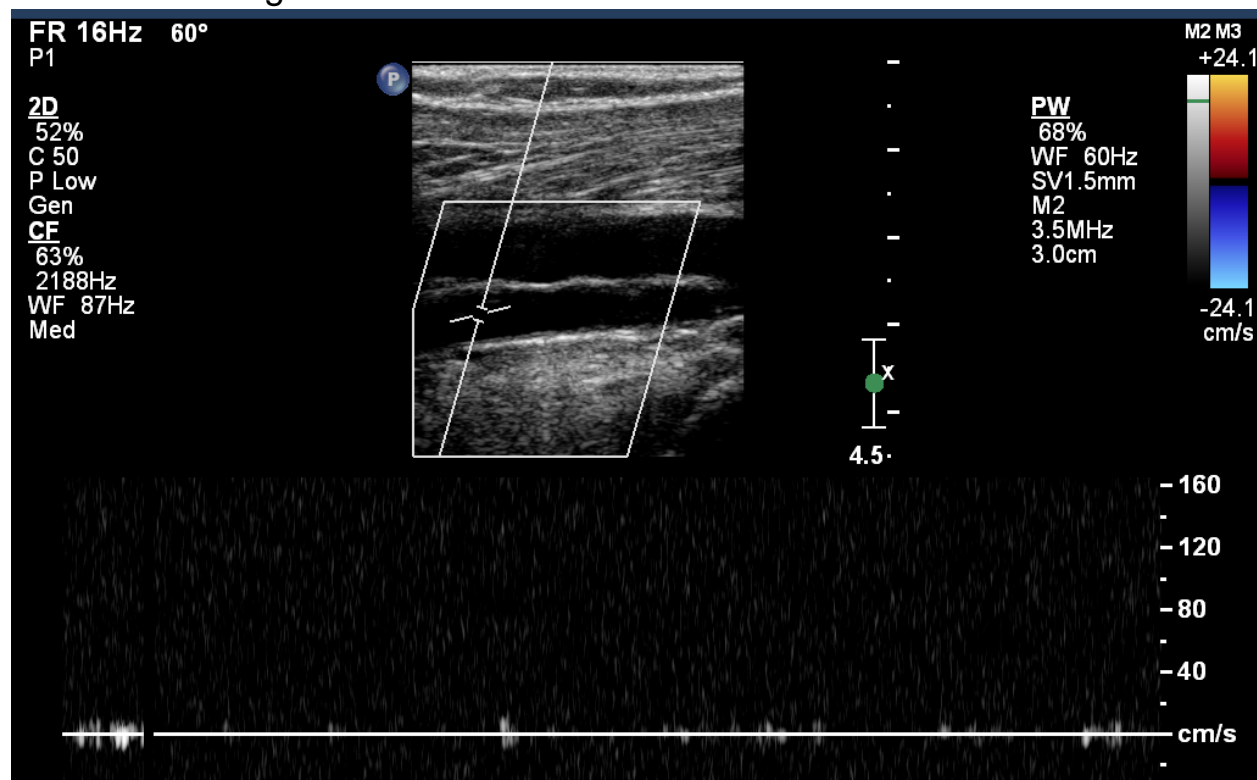
Ralph J Perrico III MD

E-signed 2016-06-01 04:10AM EDT

rjp@neomed.edu



Ultrasound Image 1392



Assessment for ultrasound image coded 1392

OCCLUSION, Pulsatile arterial flow is absent.

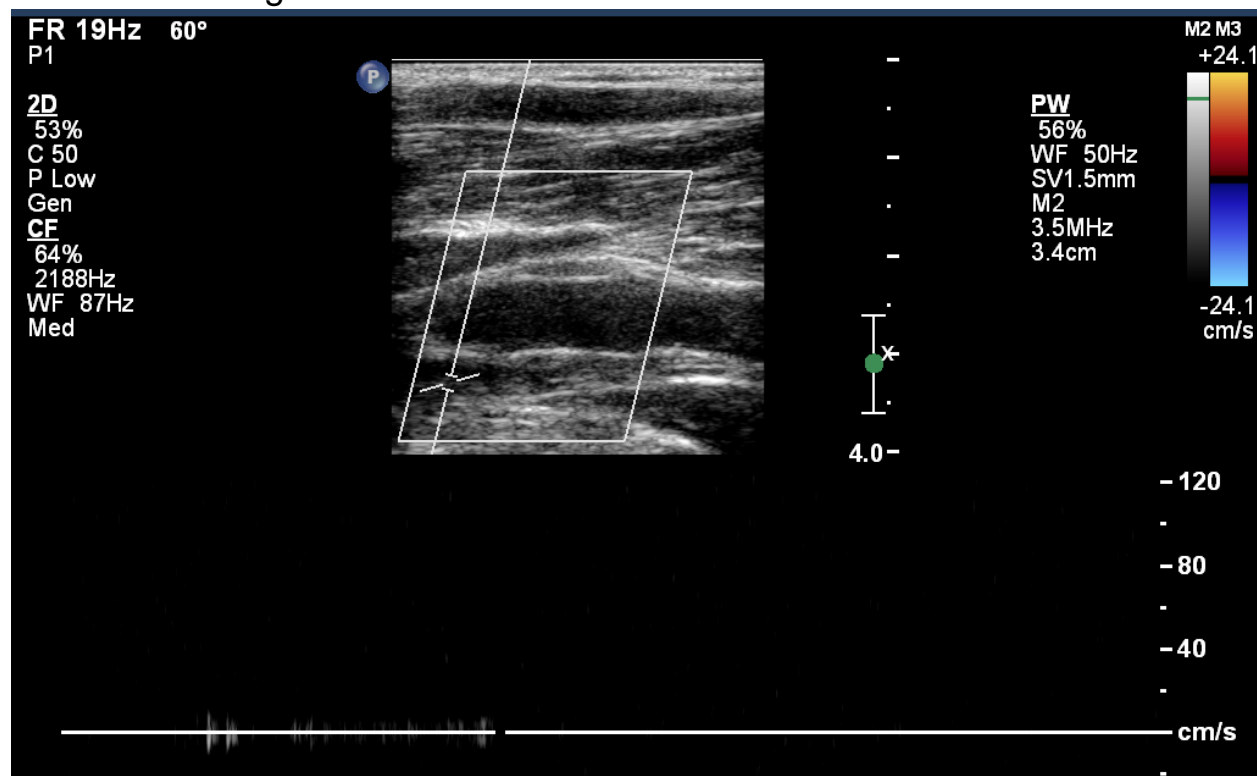
Ralph J Perrico III MD

E-signed 2016-06-01 04:10AM EDT

rjp@neomed.edu



Ultrasound Image 1423



Assessment for ultrasound image coded 1423

OCCLUSION, Pulsatile arterial flow is absent.

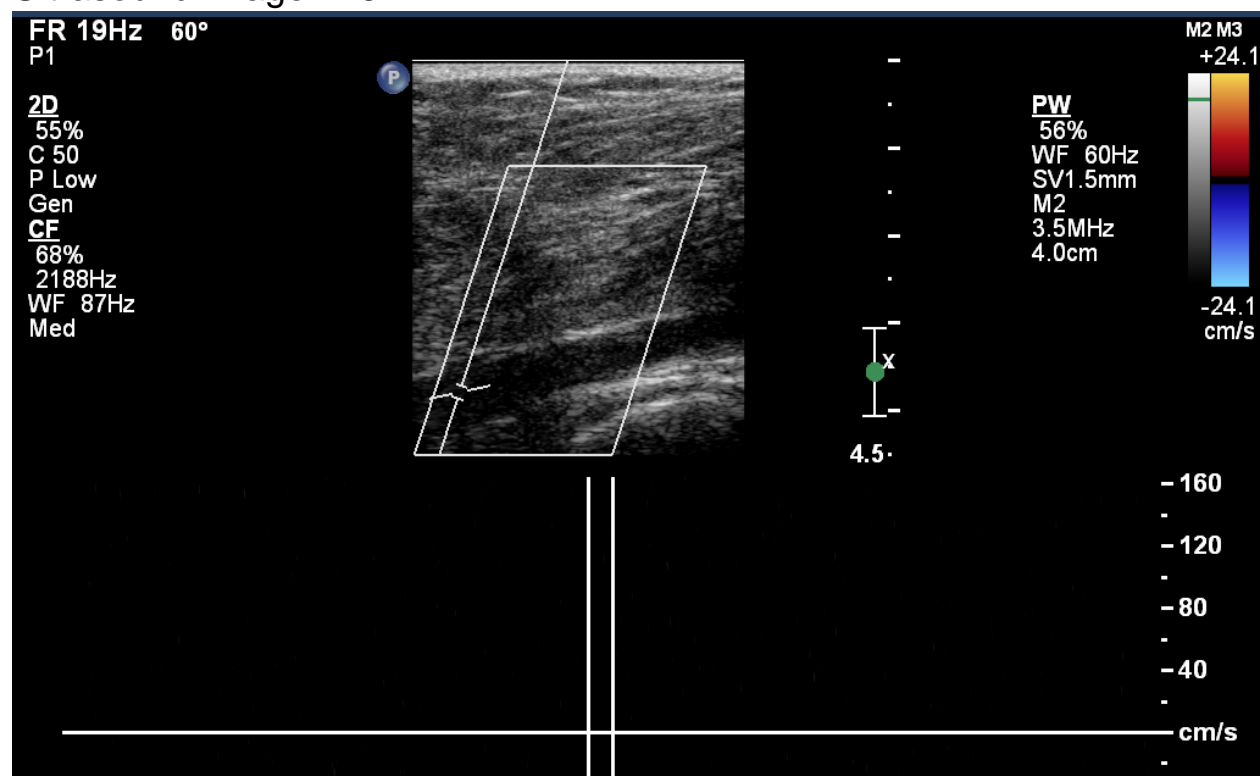
Ralph J Perrico III MD

E-signed 2016-06-01 04:10AM EDT

rjp@neomed.edu



Ultrasound Image 1434



Assessment for ultrasound image coded 1434

OCCLUSION, Pulsatile arterial flow is absent.

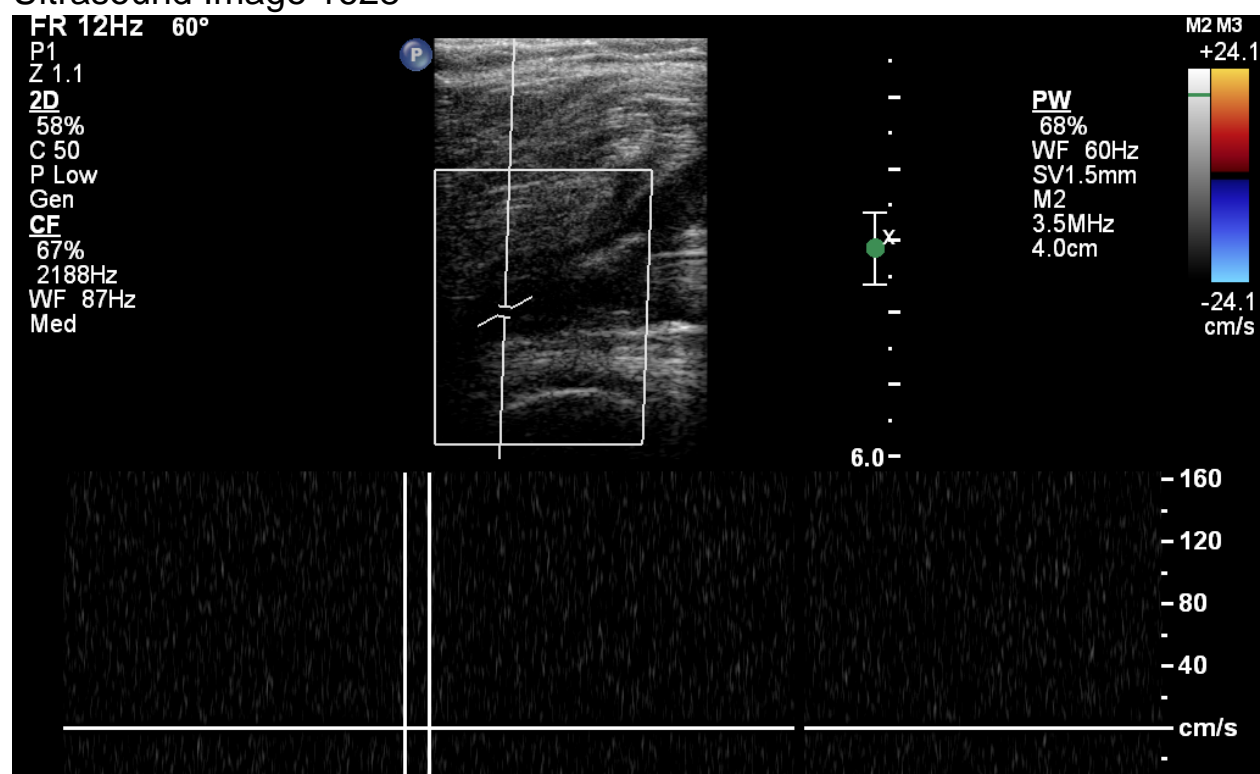
Ralph J Perrico III MD

E-signed 2016-06-01 04:10AM EDT

rjp@neomed.edu



Ultrasound Image 1628



Assessment for ultrasound image coded 1628

OCCLUSION, Pulsatile arterial flow is absent.

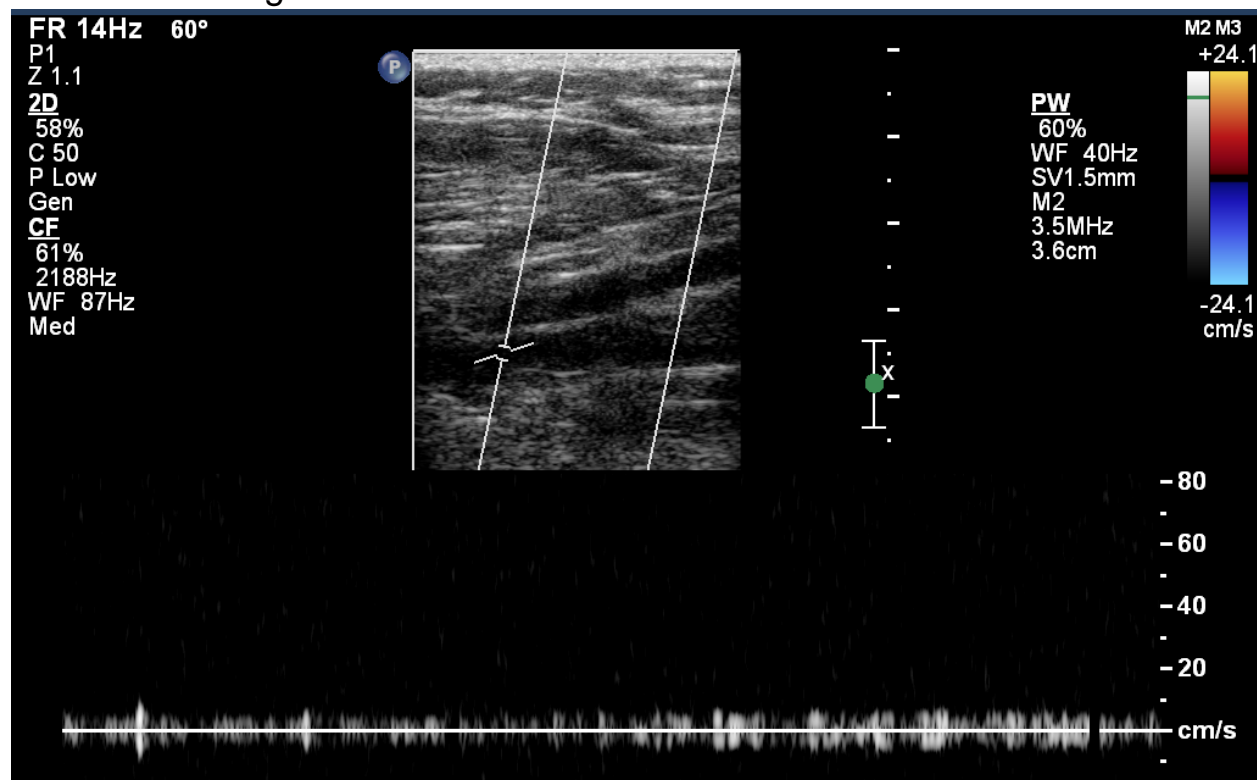
Ralph J Perrico III MD

E-signed 2016-06-01 04:10AM EDT

rjp@neomed.edu



Ultrasound Image 1730



Assessment for ultrasound image coded 1730

OCCLUSION, Pulsatile arterial flow is absent.

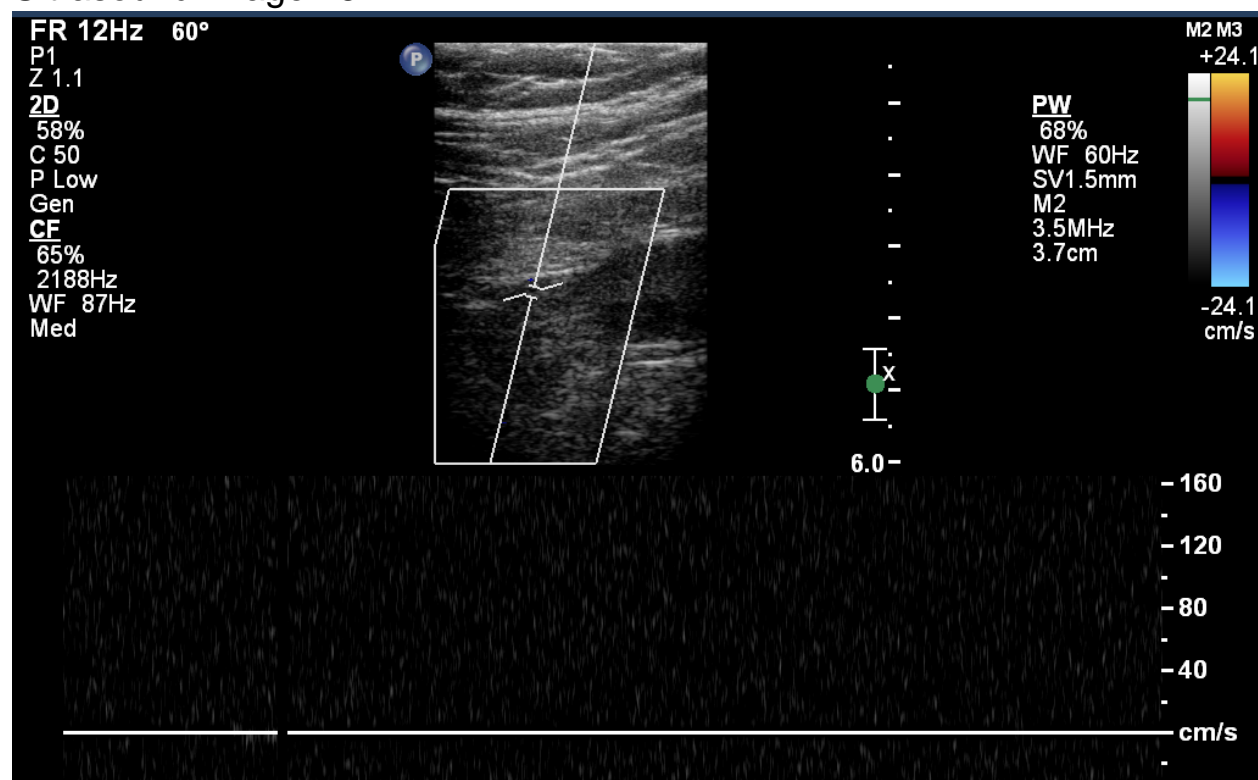
Ralph J Perrico III MD

E-signed 2016-06-01 04:10AM EDT

rjp@neomed.edu



Ultrasound Image 1824



Assessment for ultrasound image coded 1824

OCCLUSION, Pulsatile arterial flow is absent.

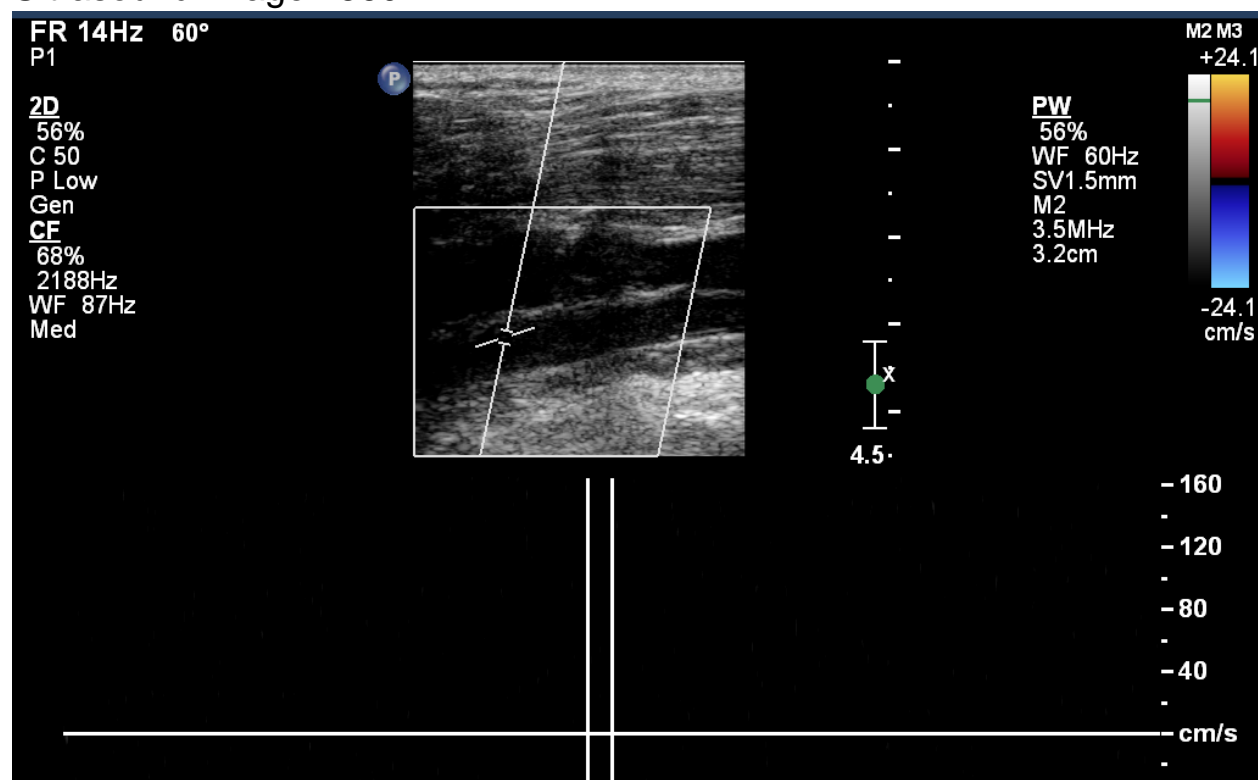
Ralph J Perrico III MD

E-signed 2016-06-01 04:10AM EDT

rjp@neomed.edu



Ultrasound Image 1860



Assessment for ultrasound image coded 1860

OCCLUSION, Pulsatile arterial flow is absent.

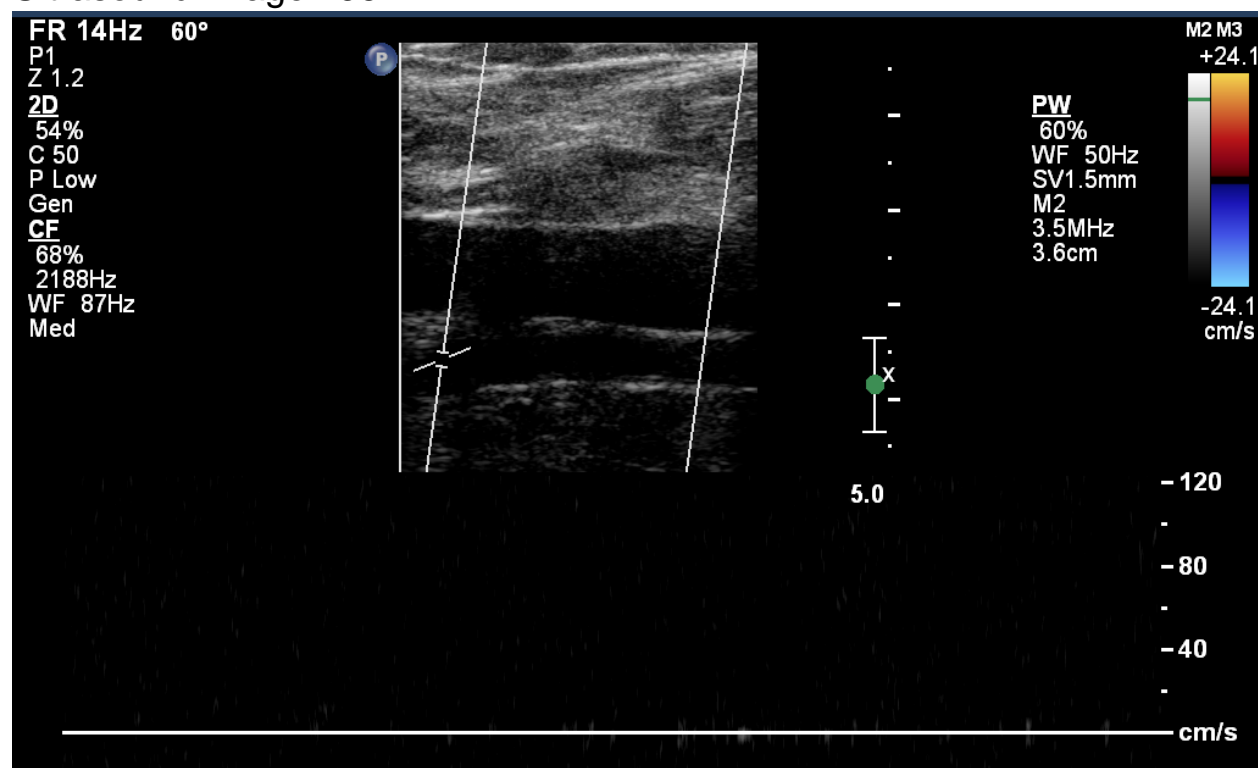
Ralph J Perrico III MD

E-signed 2016-06-01 04:10AM EDT

rjp@neomed.edu



Ultrasound Image 2532



Assessment for ultrasound image coded 2532

OCCLUSION, Pulsatile arterial flow is absent.

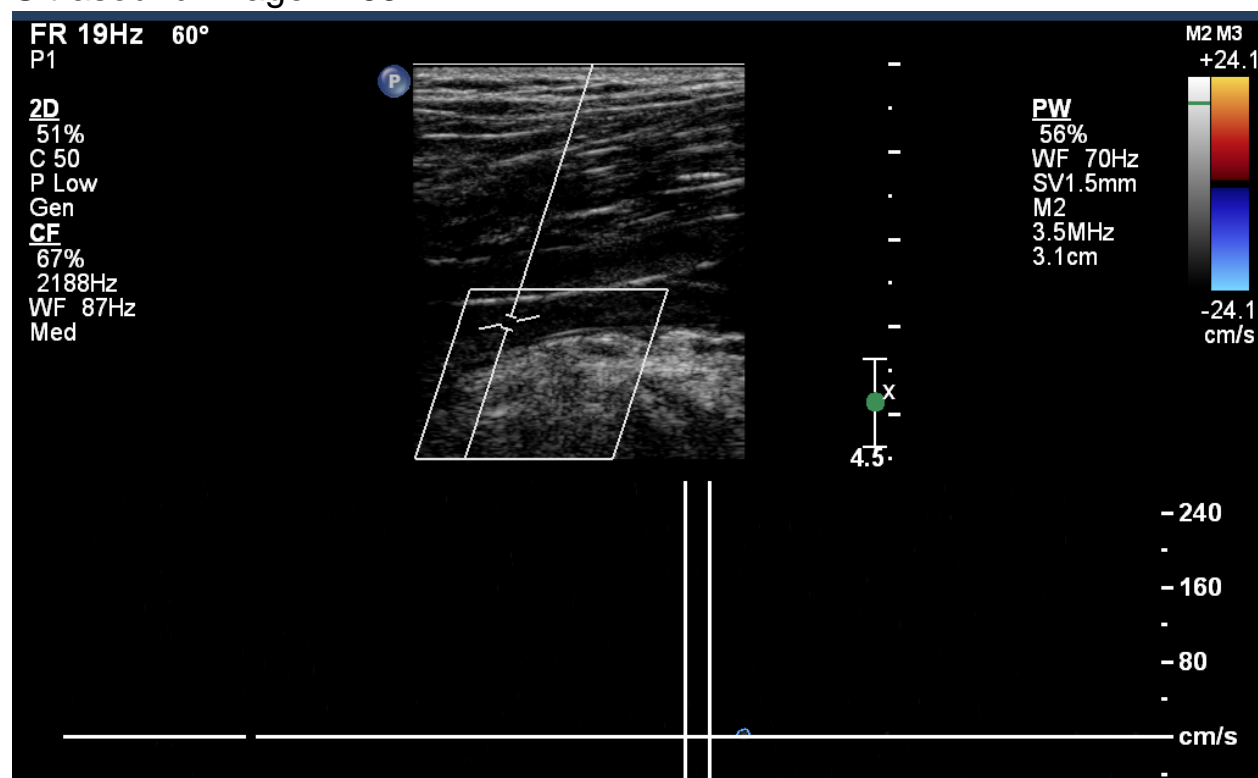
Ralph J Perrico III MD

E-signed 2016-06-01 04:10AM EDT

rjp@neomed.edu



Ultrasound Image 2765



Assessment for ultrasound image coded 2765

OCCLUSION, Pulsatile arterial flow is absent.

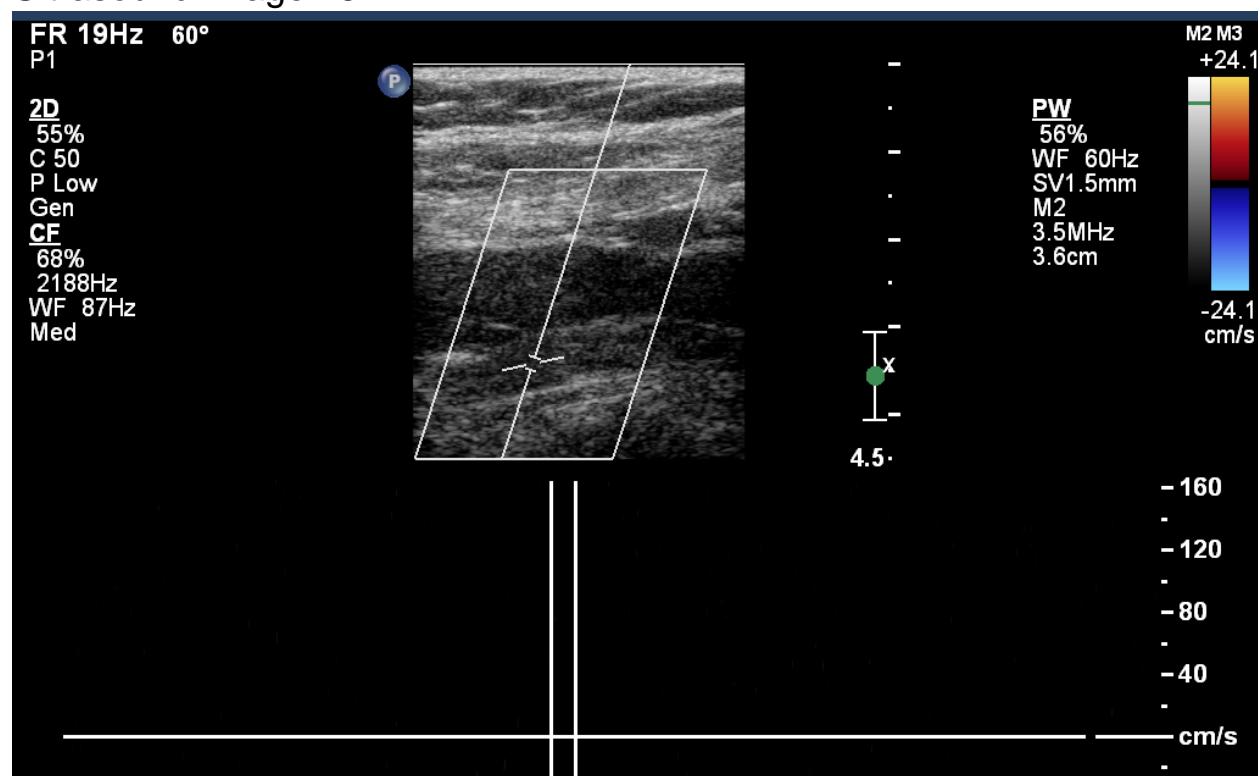
Ralph J Perrico III MD

E-signed 2016-06-01 04:10AM EDT

rjp@neomed.edu



Ultrasound Image 2874



Assessment for ultrasound image coded 2874

OCCLUSION, Pulsatile arterial flow is absent.

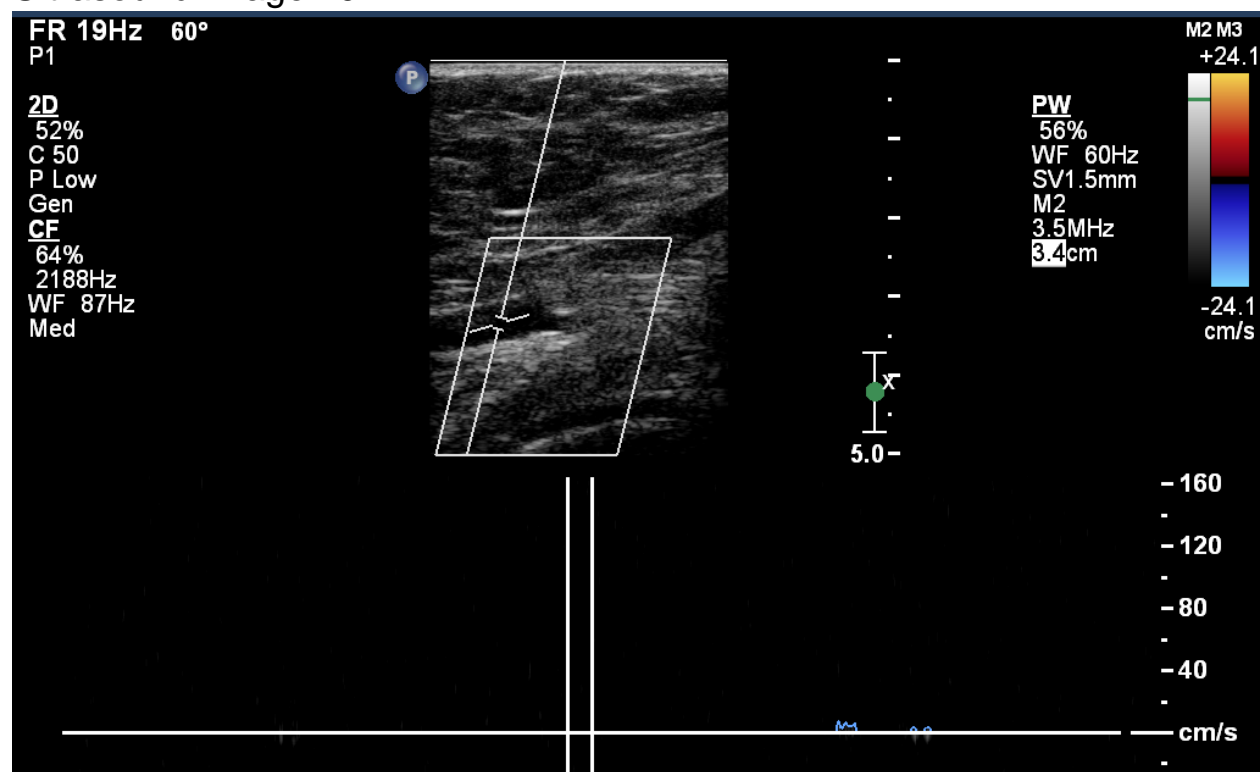
Ralph J Perrico III MD

E-signed 2016-06-01 04:10AM EDT

rjp@neomed.edu



Ultrasound Image 2922



Assessment for ultrasound image coded 2922

OCCLUSION, Pulsatile arterial flow is absent.

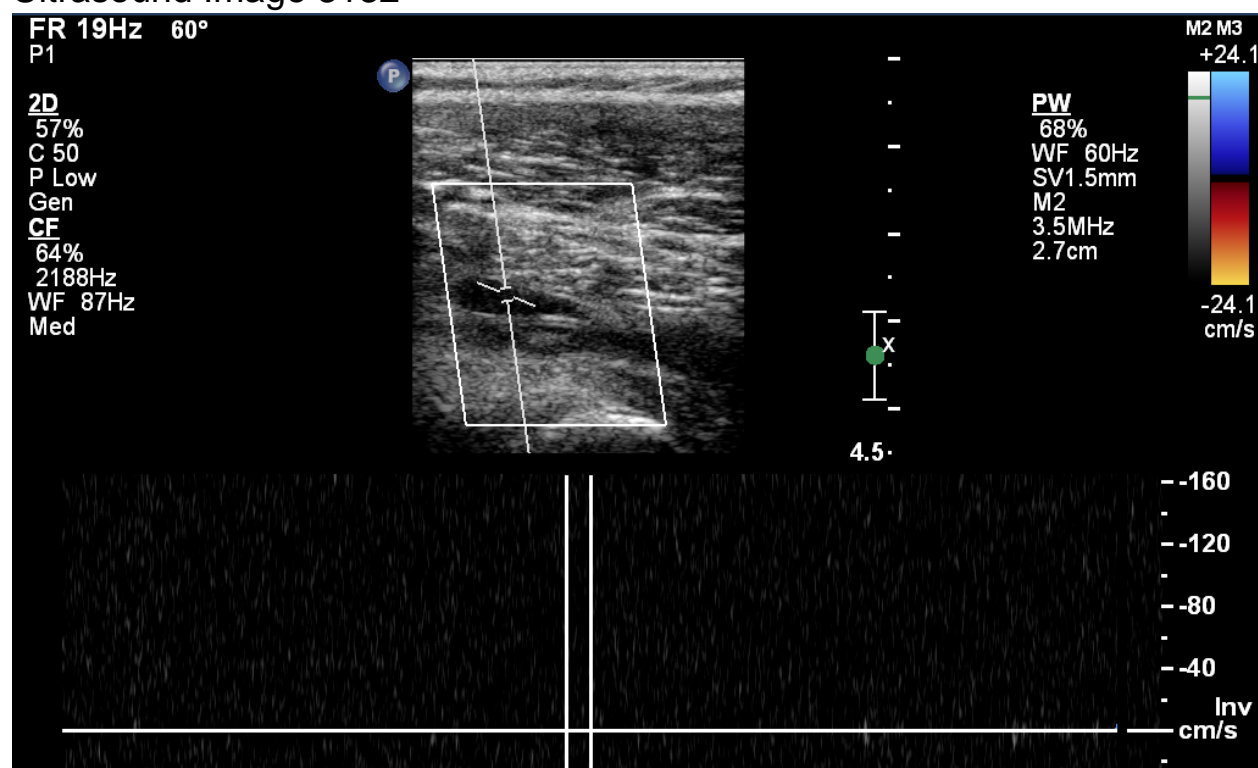
Ralph J Perrico III MD

E-signed 2016-06-01 04:10AM EDT

rjp@neomed.edu



Ultrasound Image 3132



Assessment for ultrasound image coded 3132

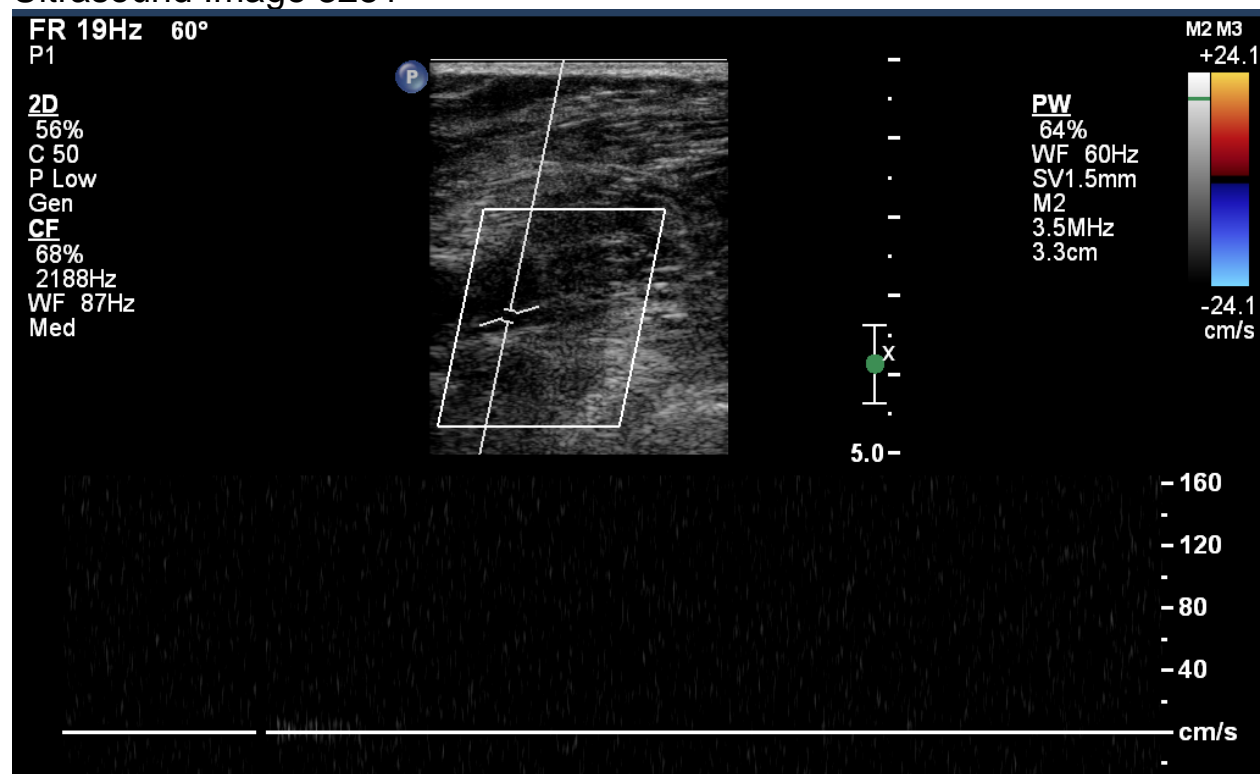
OCCLUSION, Pulsatile arterial flow is absent.

Ralph J Perrico III MD

E-signed 2016-06-01 04:10AM EDT
rjp@neomed.edu

xli

Ultrasound Image 3251



Assessment for ultrasound image coded 3251

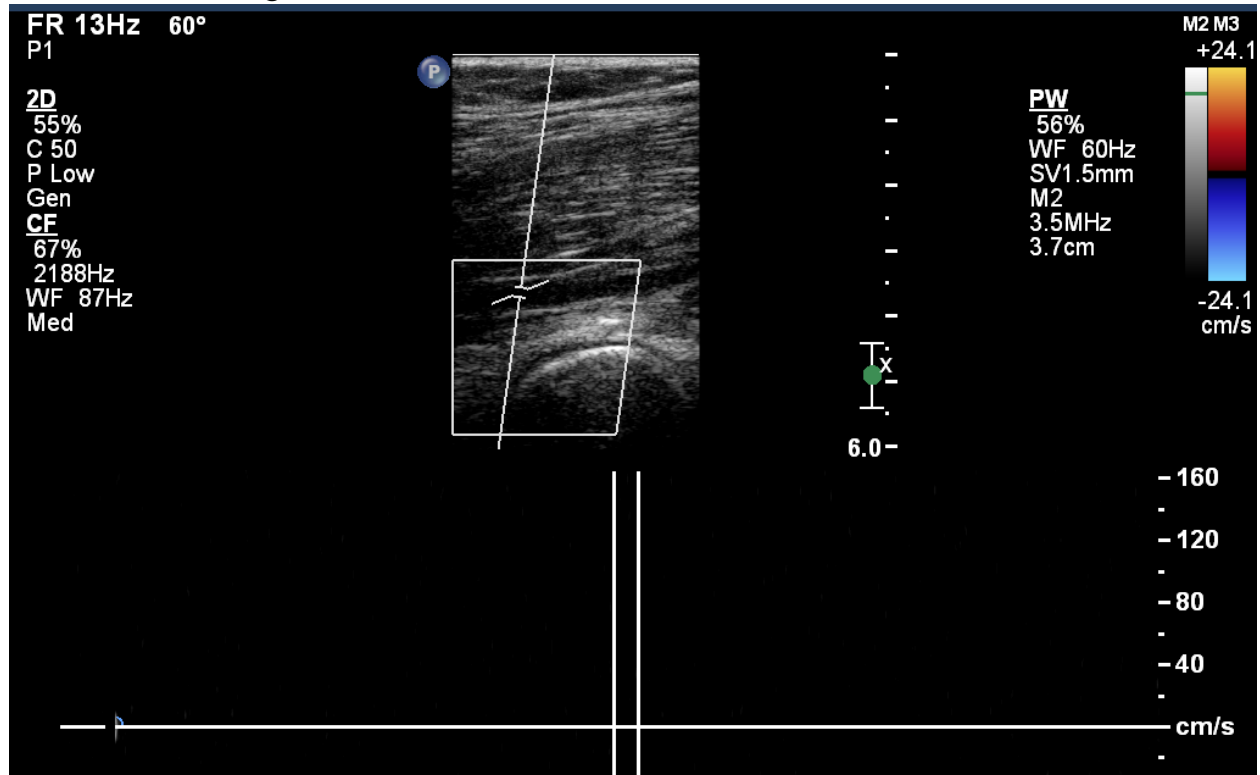
OCCLUSION, Pulsatile arterial flow is absent.

Ralph J Perrico III MD

E-signed 2016-06-01 04:10AM EDT
rjp@neomed.edu



Ultrasound Image 3258



Assessment for ultrasound image coded 3258

OCCLUSION, Pulsatile arterial flow is absent.

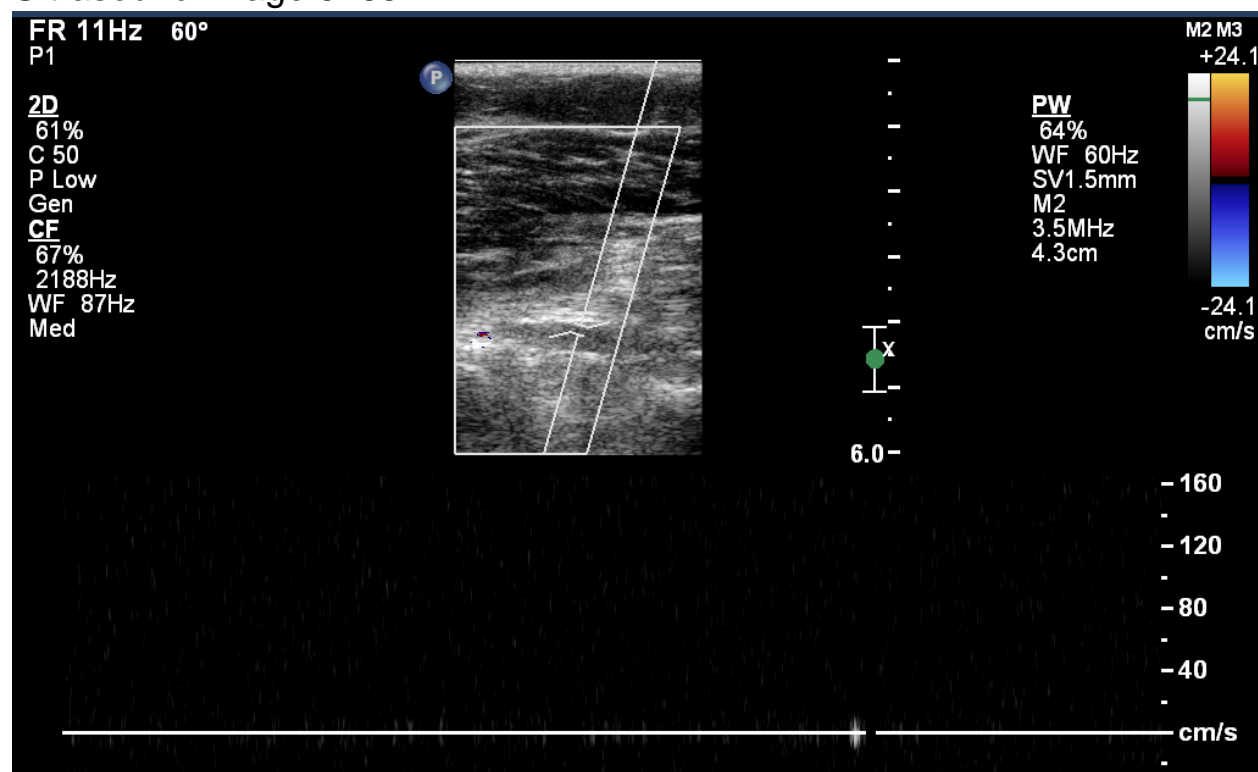
Ralph J Perrico III MD

E-signed 2016-06-01 04:10AM EDT

rjp@neomed.edu



Ultrasound Image 3265



Assessment for ultrasound image coded 3265

OCCLUSION, Pulsatile arterial flow is absent.

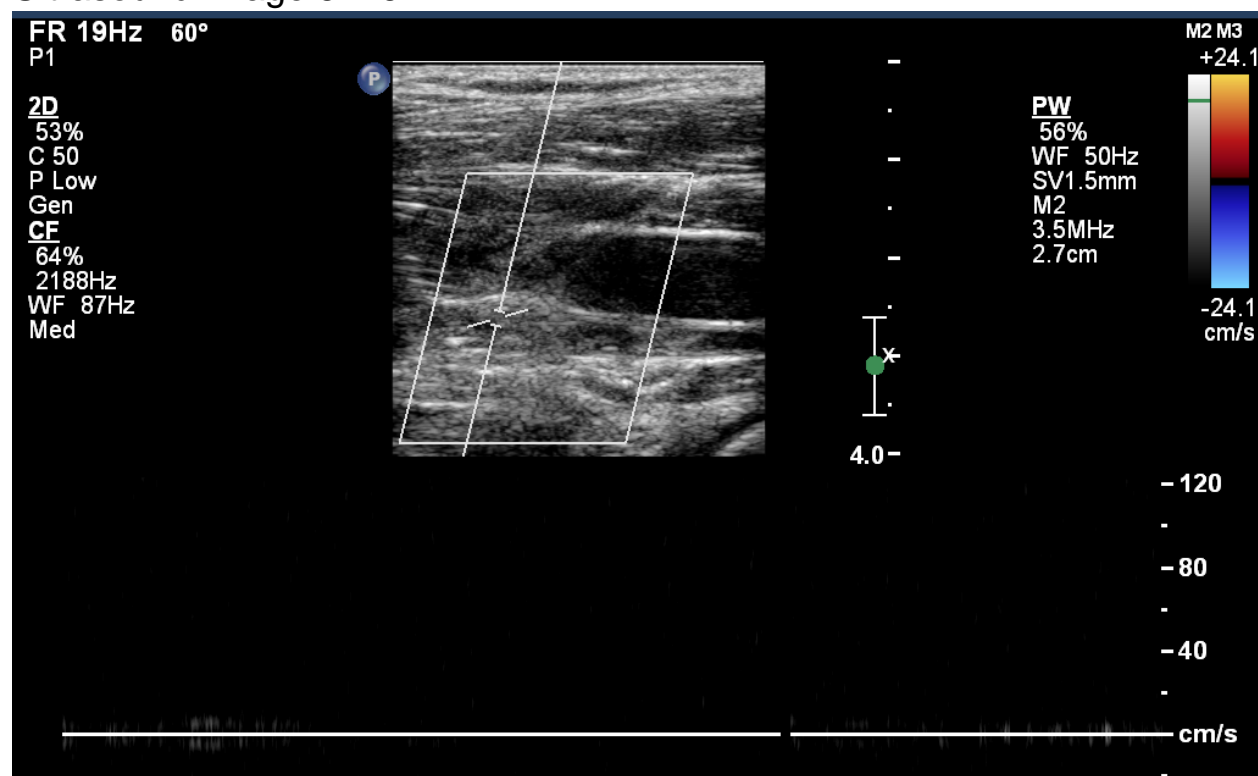
Ralph J Perrico III MD

E-signed 2016-06-01 04:10AM EDT

rjp@neomed.edu



Ultrasound Image 3276



Assessment for ultrasound image coded 3276

OCCLUSION, Pulsatile arterial flow is absent.

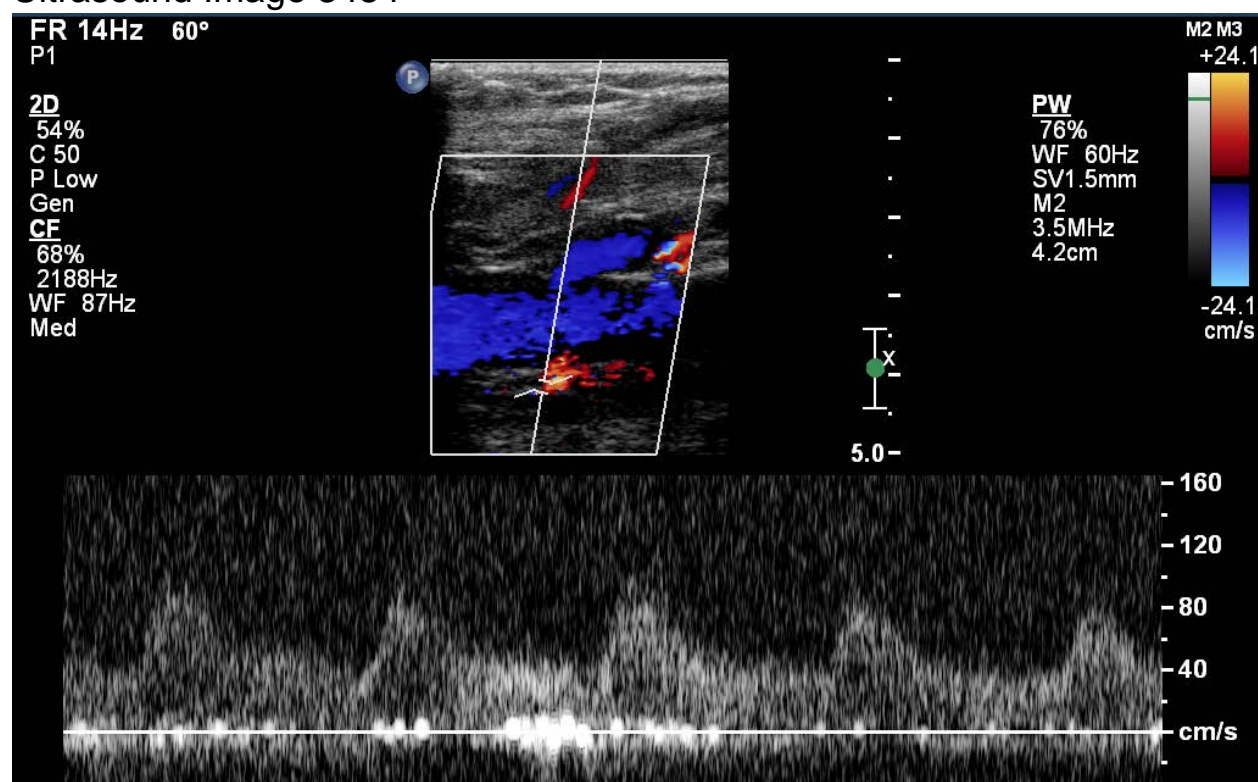
Ralph J Perrico III MD

E-signed 2016-06-01 04:10AM EDT

rjp@neomed.edu



Ultrasound Image 3434



Assessment for ultrasound image coded 3434

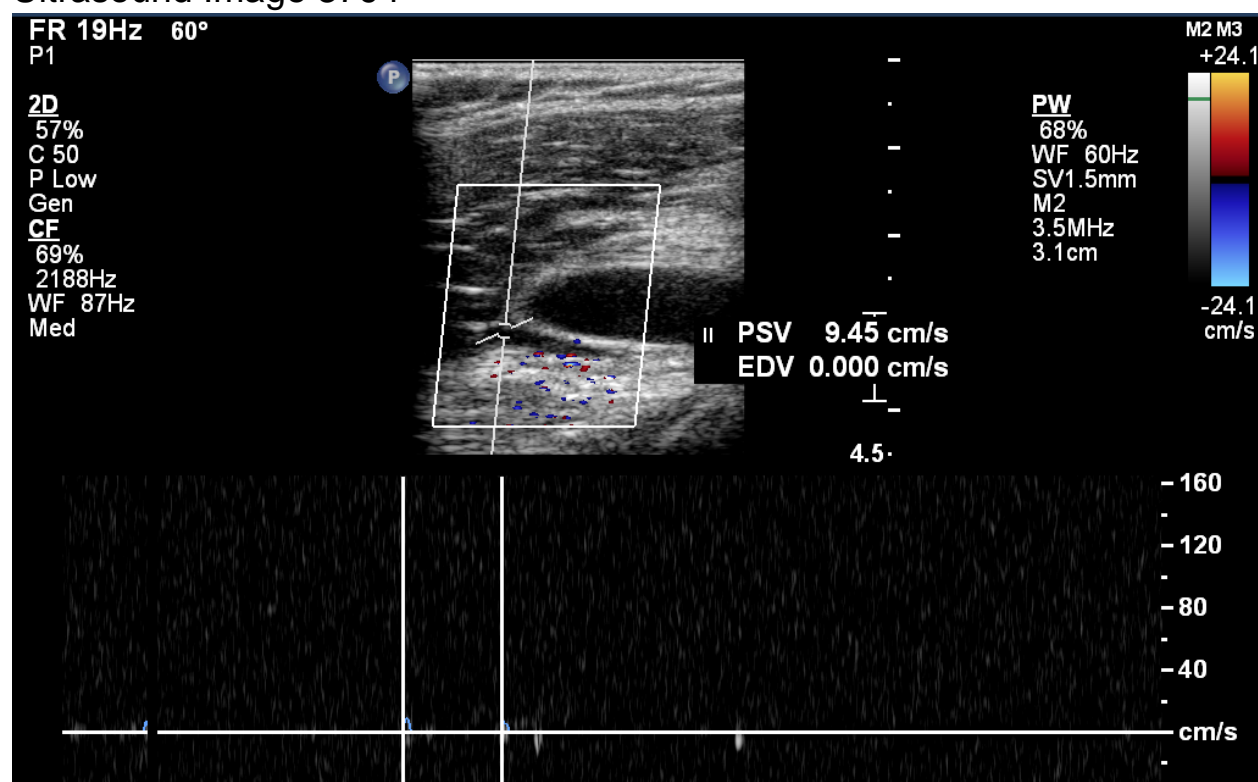
FLOW, Pulsatile arterial flow is present.

Ralph J Perrico III MD

E-signed 2016-06-01 04:10AM EDT
rjp@neomed.edu



Ultrasound Image 3794



Assessment for ultrasound image coded 3794

OCCLUSION, Pulsatile arterial flow is absent.

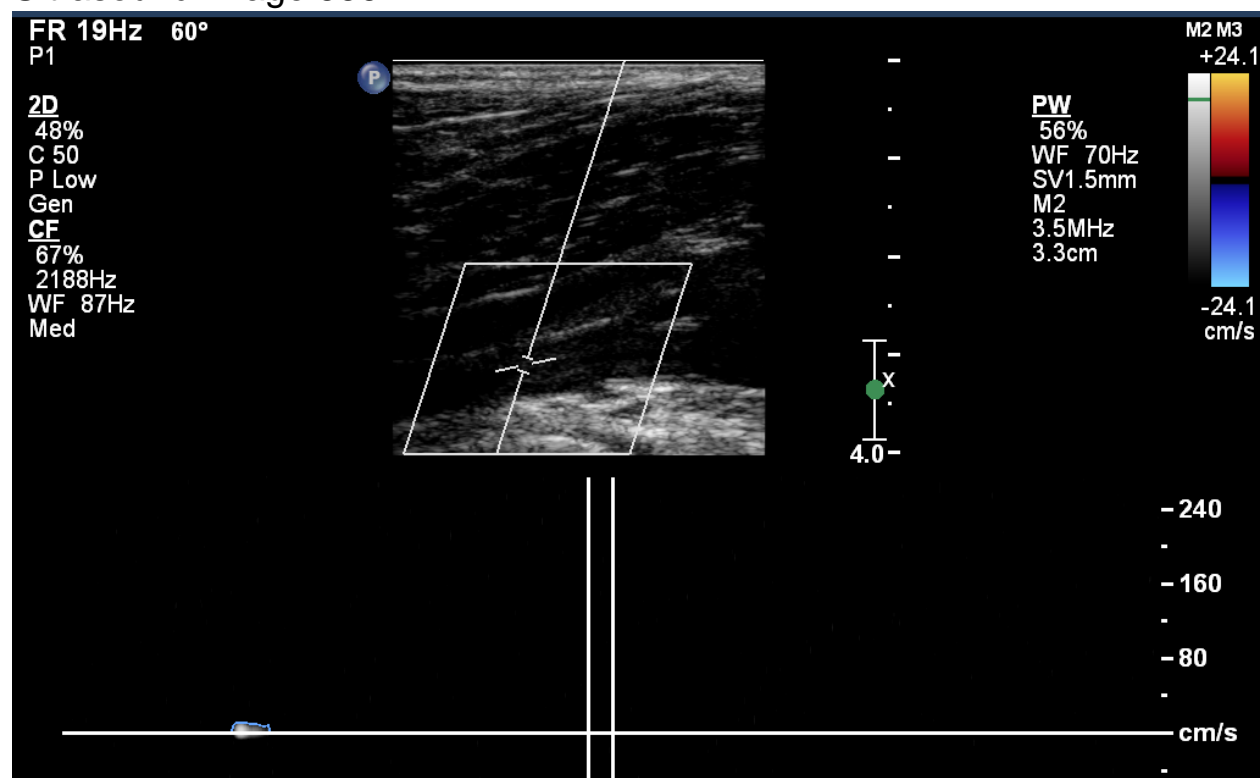
Ralph J Perrico III MD

E-signed 2016-06-01 04:10AM EDT

rjp@neomed.edu



Ultrasound Image 3862



Assessment for ultrasound image coded 3862

OCCLUSION, Pulsatile arterial flow is absent.

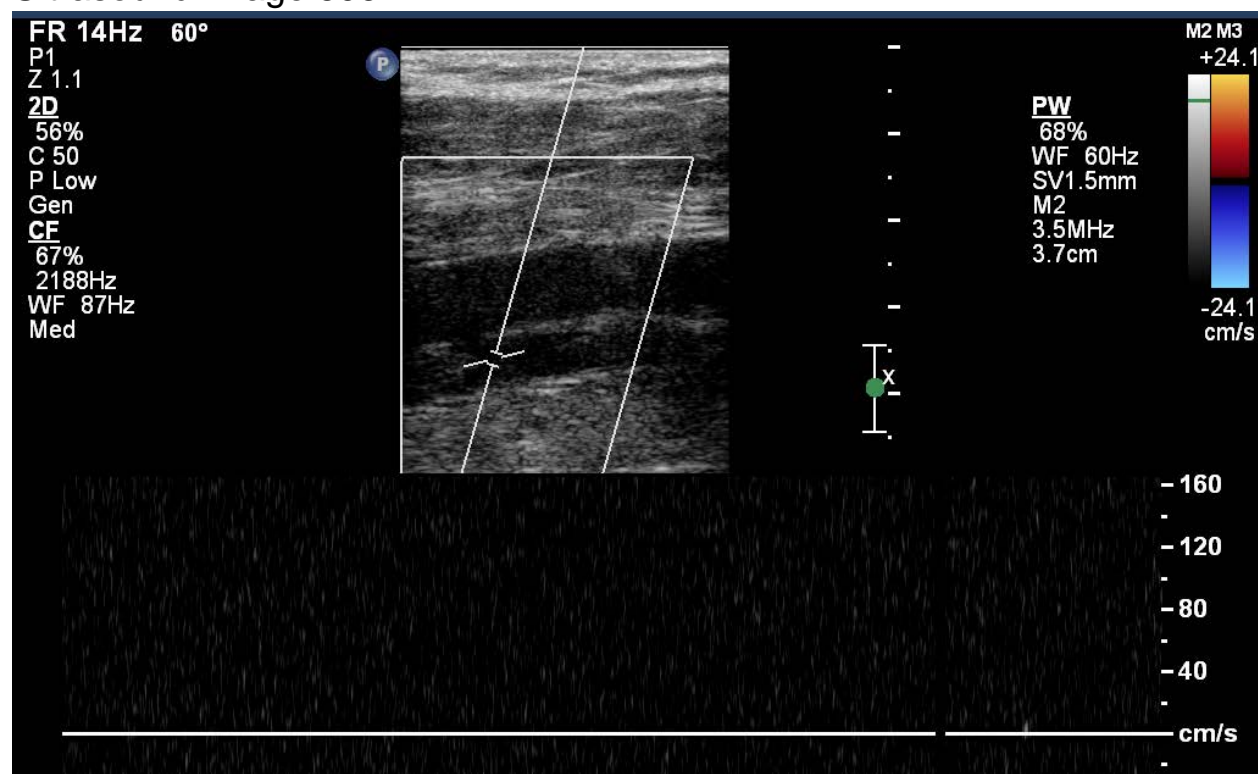
Ralph J Perrico III MD

E-signed 2016-06-01 04:10AM EDT

rjp@neomed.edu



Ultrasound Image 3954



Assessment for ultrasound image coded 3954

OCCLUSION, Pulsatile arterial flow is absent.

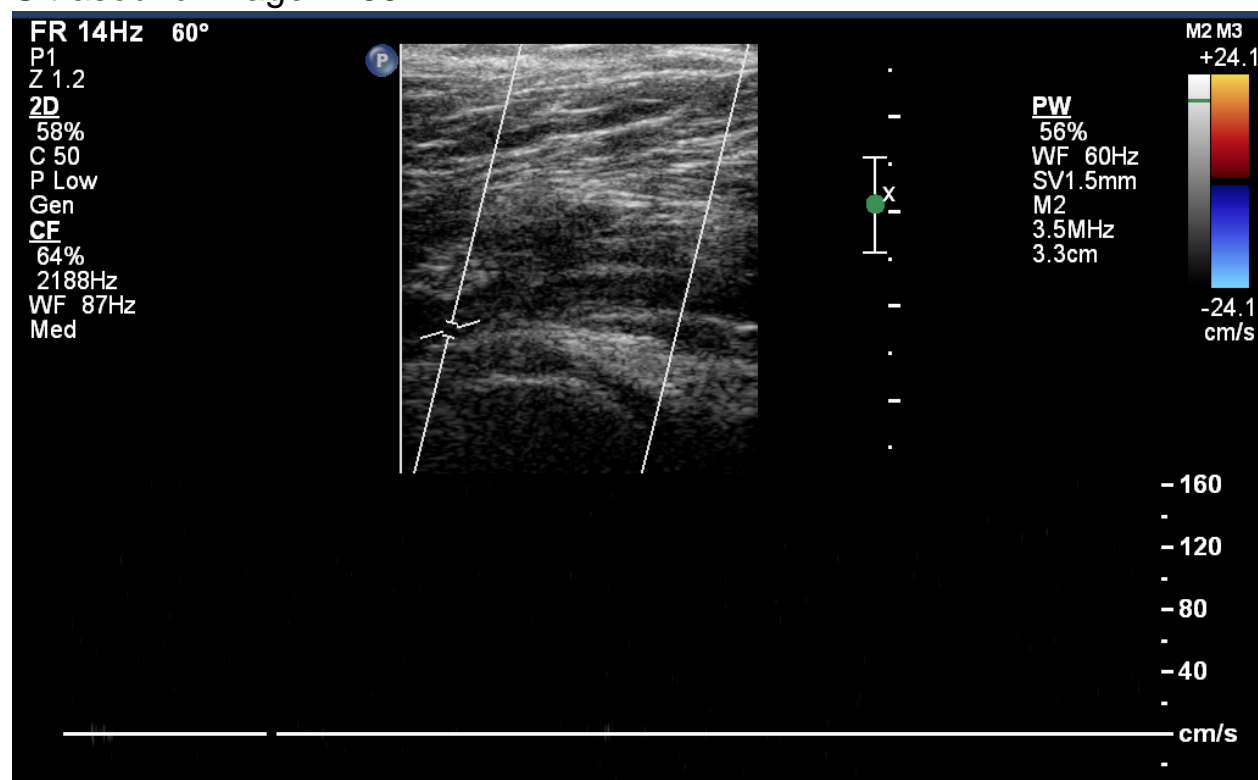
Ralph J Perrico III MD

E-signed 2016-06-01 04:10AM EDT

rjp@neomed.edu



Ultrasound Image 4466



Assessment for ultrasound image coded 4466

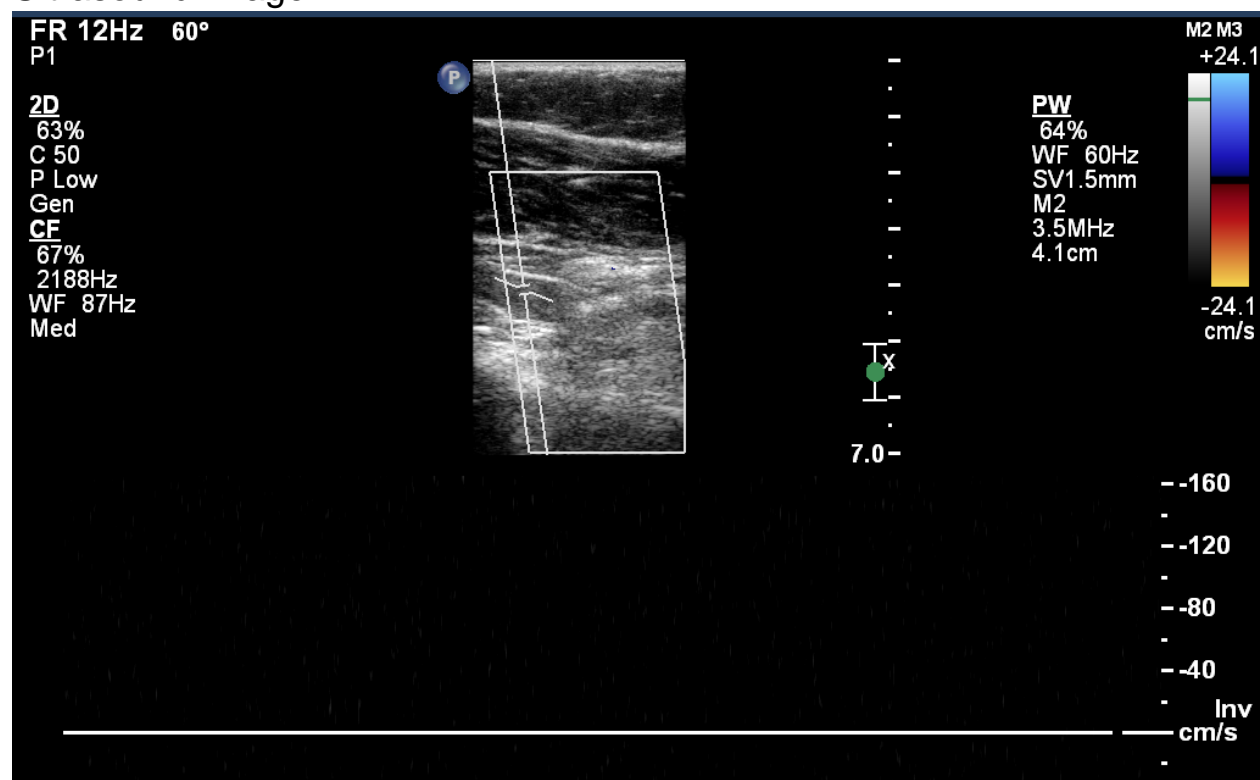
OCCLUSION, Pulsatile arterial flow is absent.

Ralph J Perrico III MD

E-signed 2016-06-01 04:10AM EDT
rjp@neomed.edu



Ultrasound Image 4472



Assessment for ultrasound image coded 4472

OCCLUSION, Pulsatile arterial flow is absent.

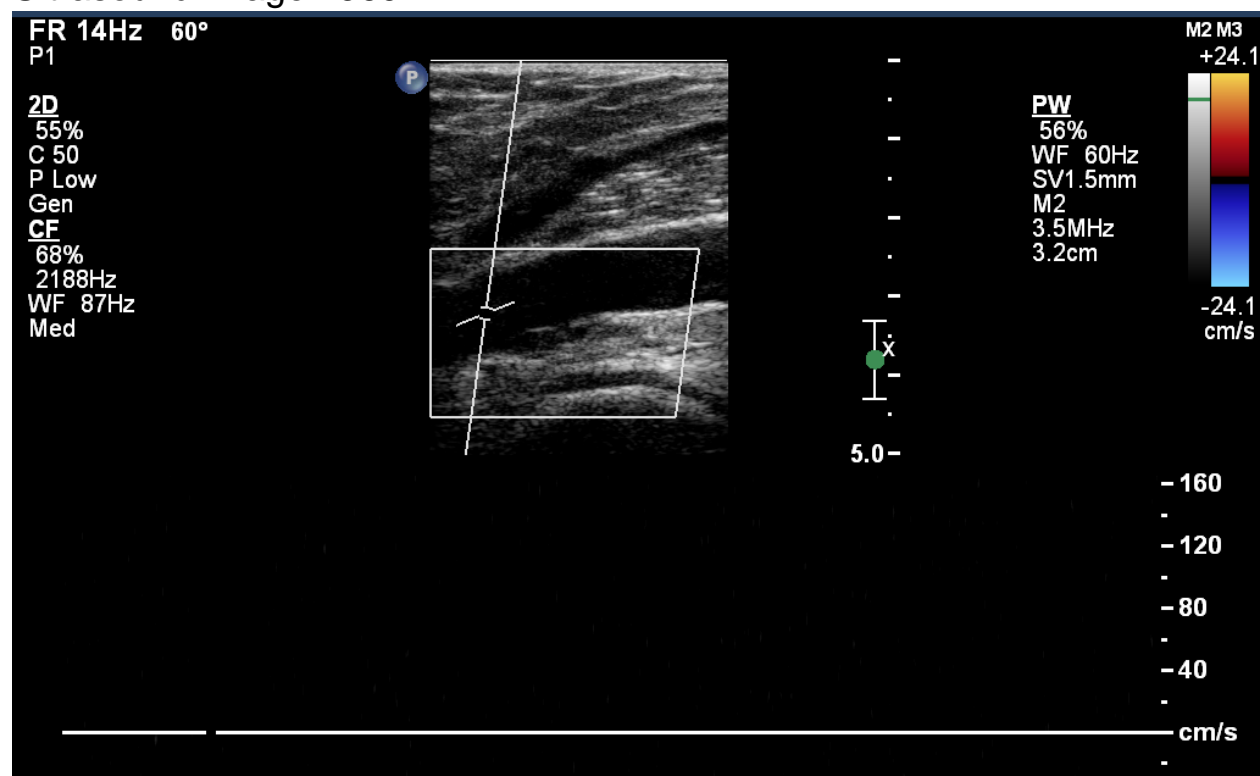
Ralph J Perrico III MD

E-signed 2016-06-01 04:10AM EDT

rjp@neomed.edu



Ultrasound Image 4569



Assessment for ultrasound image coded 4569

OCCLUSION, Pulsatile arterial flow is absent.

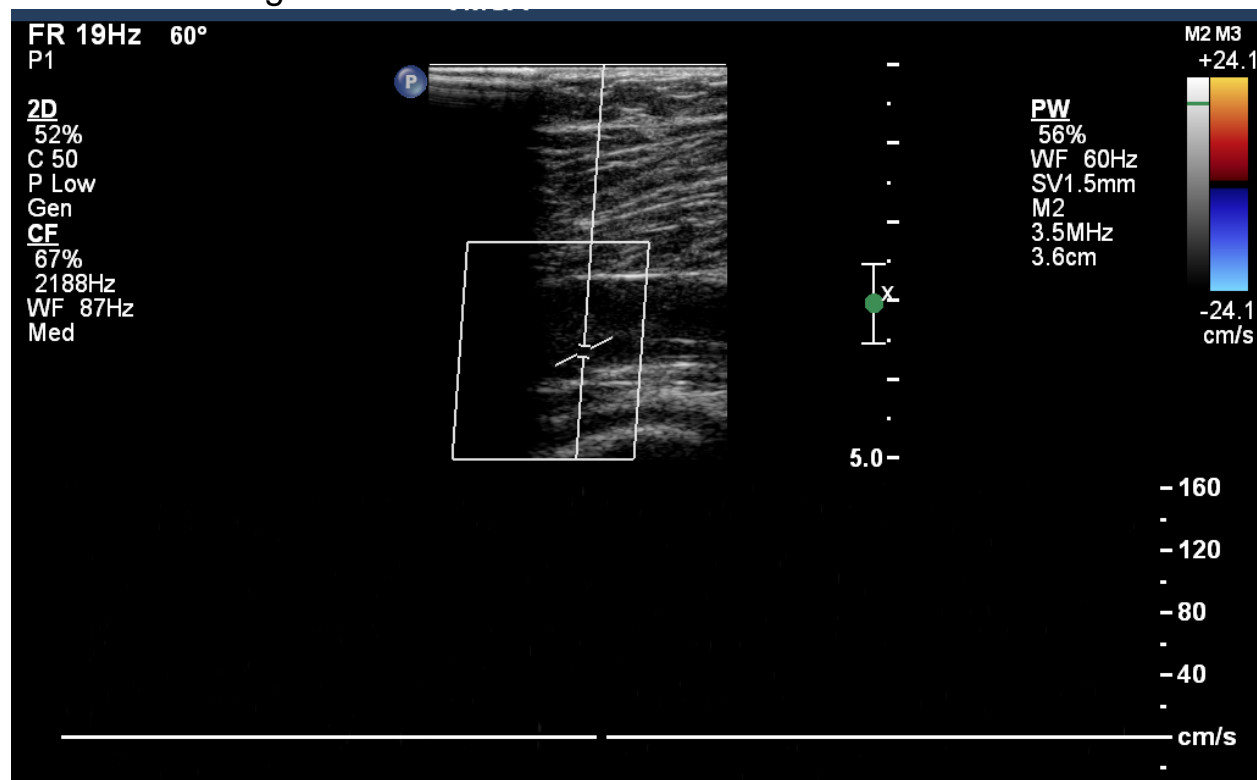
Ralph J Perrico III MD

E-signed 2016-06-01 04:10AM EDT

rjp@neomed.edu

xli

Ultrasound Image 5061



Assessment for ultrasound image coded 5061

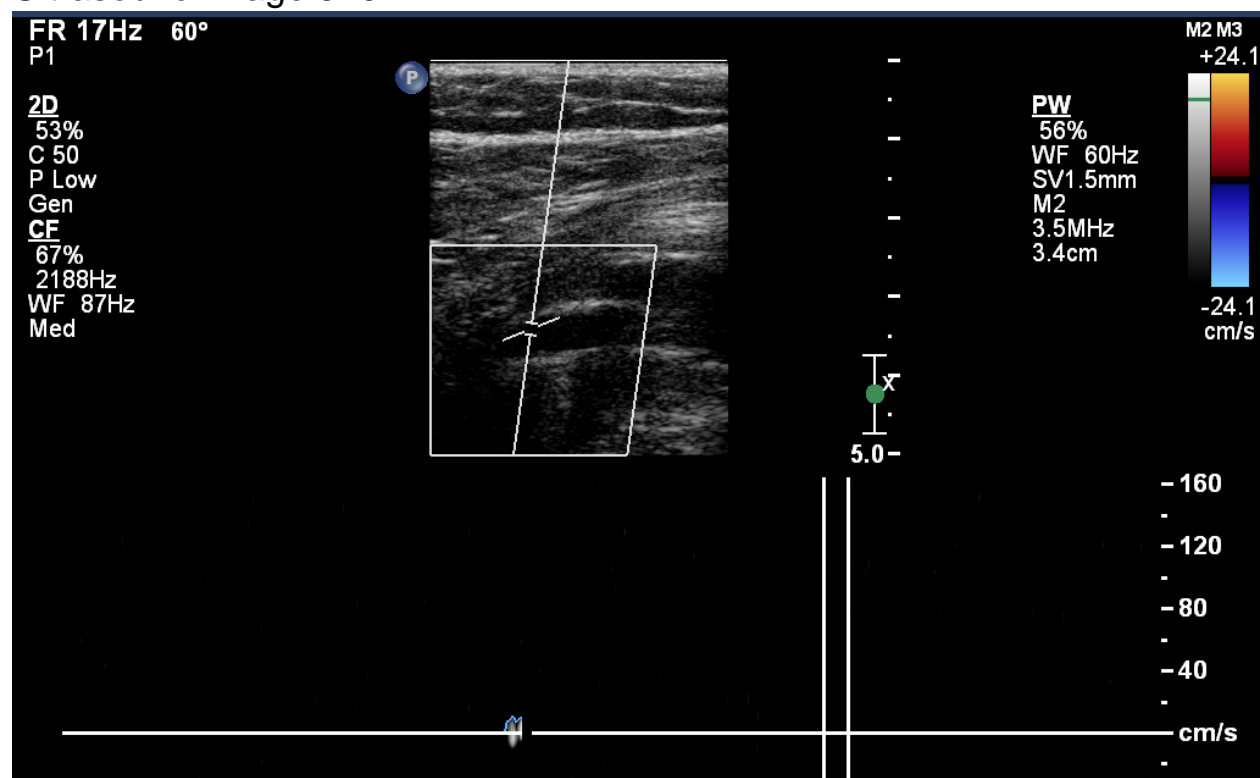
OCCLUSION, Pulsatile arterial flow is absent.

Ralph J Perrico III MD

E-signed 2016-06-01 04:10AM EDT
rjp@neomed.edu



Ultrasound Image 5401



Assessment for ultrasound image coded 5401

OCCLUSION, Pulsatile arterial flow is absent.

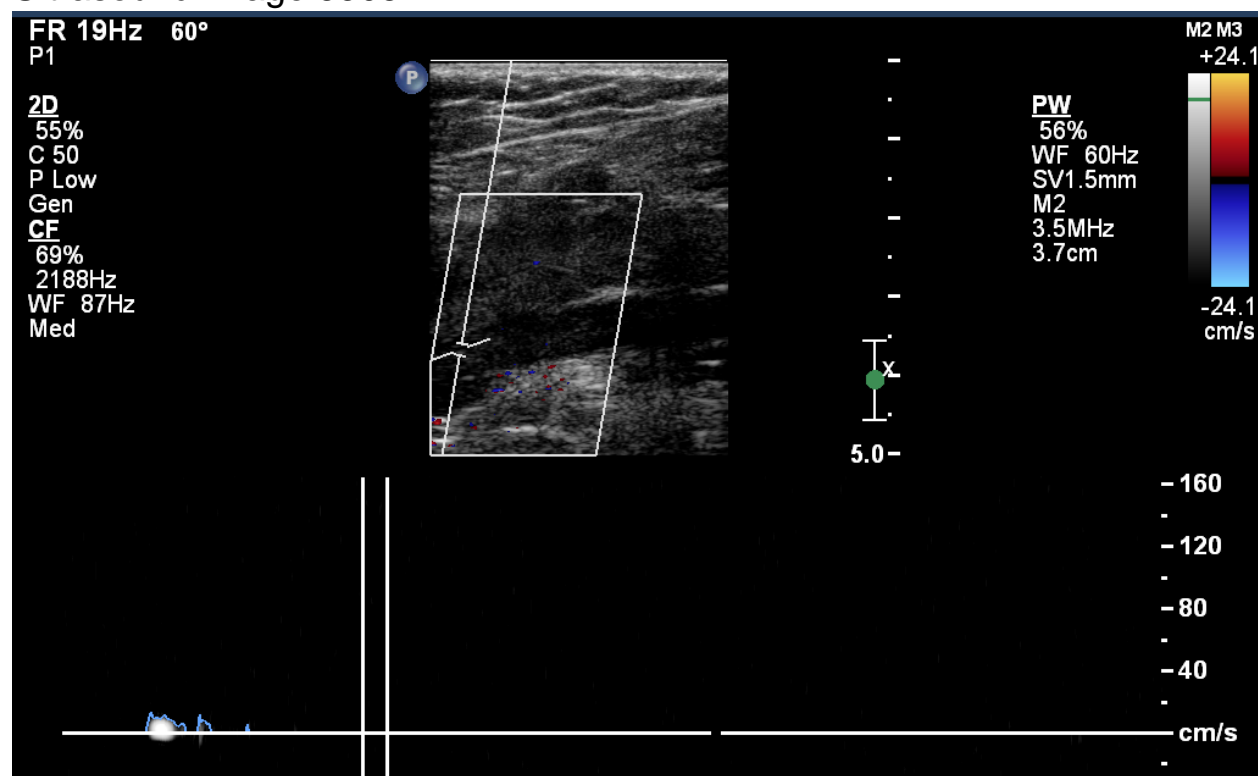
Ralph J Perrico III MD

E-signed 2016-06-01 04:10AM EDT

rjp@neomed.edu



Ultrasound Image 5503



Assessment for ultrasound image coded 5503

OCCLUSION, Pulsatile arterial flow is absent.

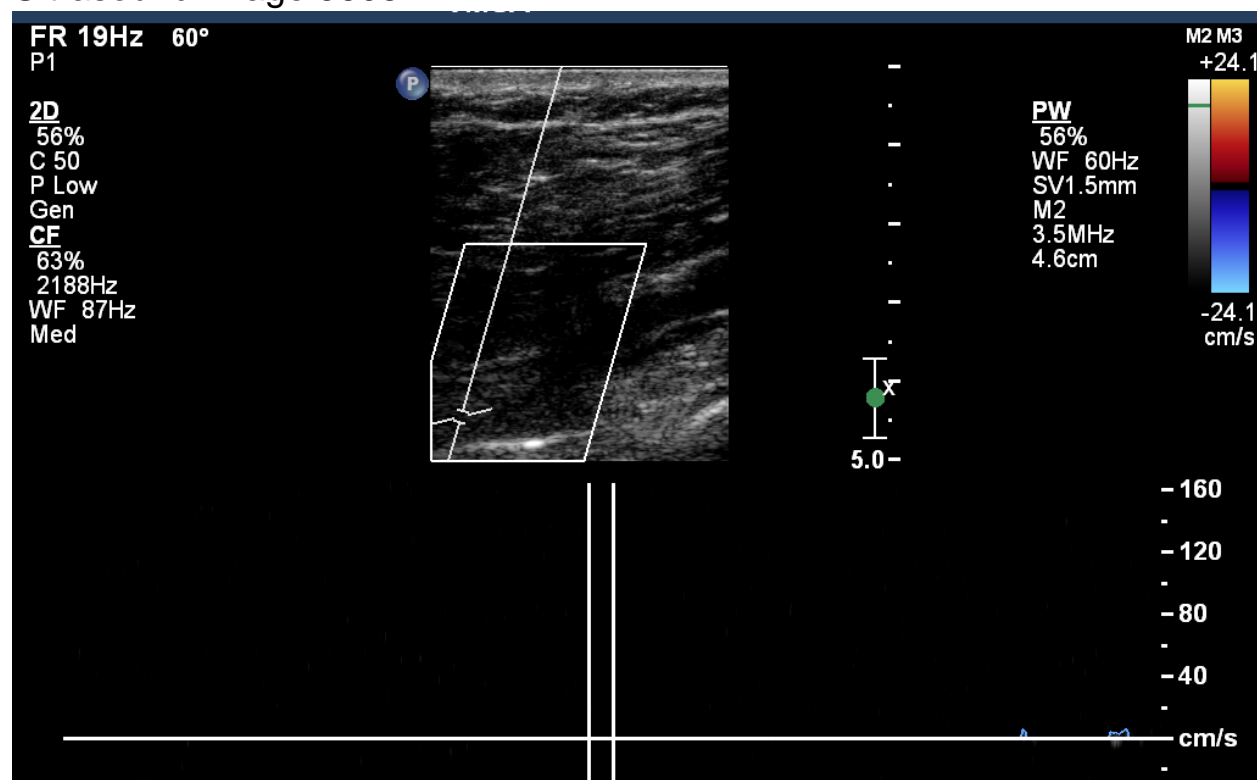
Ralph J Perrico III MD

E-signed 2016-06-01 04:10AM EDT

rjp@neomed.edu



Ultrasound Image 5608



Assessment for ultrasound image coded 5608

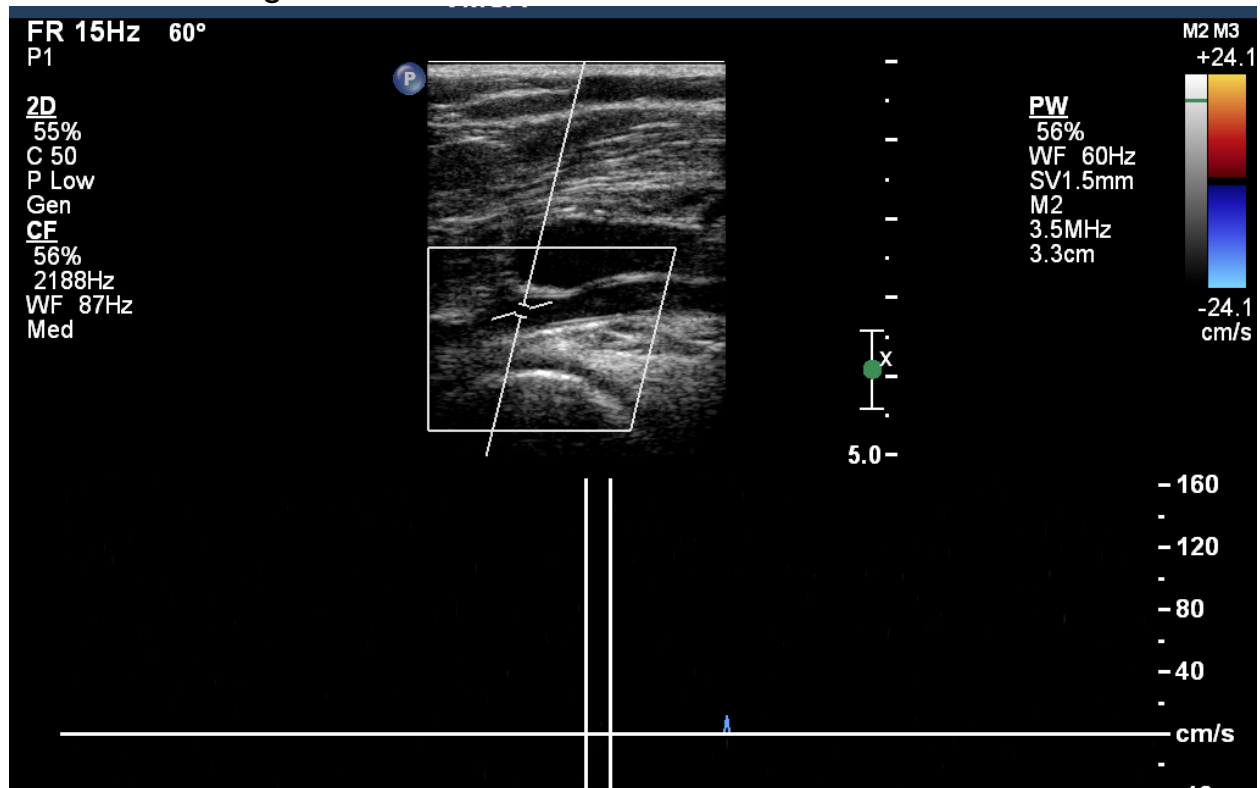
OCCLUSION, Pulsatile arterial flow is absent.

Ralph J Perrico III MD

E-signed 2016-06-01 04:10AM EDT
rjp@neomed.edu



Ultrasound Image 5624



Assessment for ultrasound image coded 5624

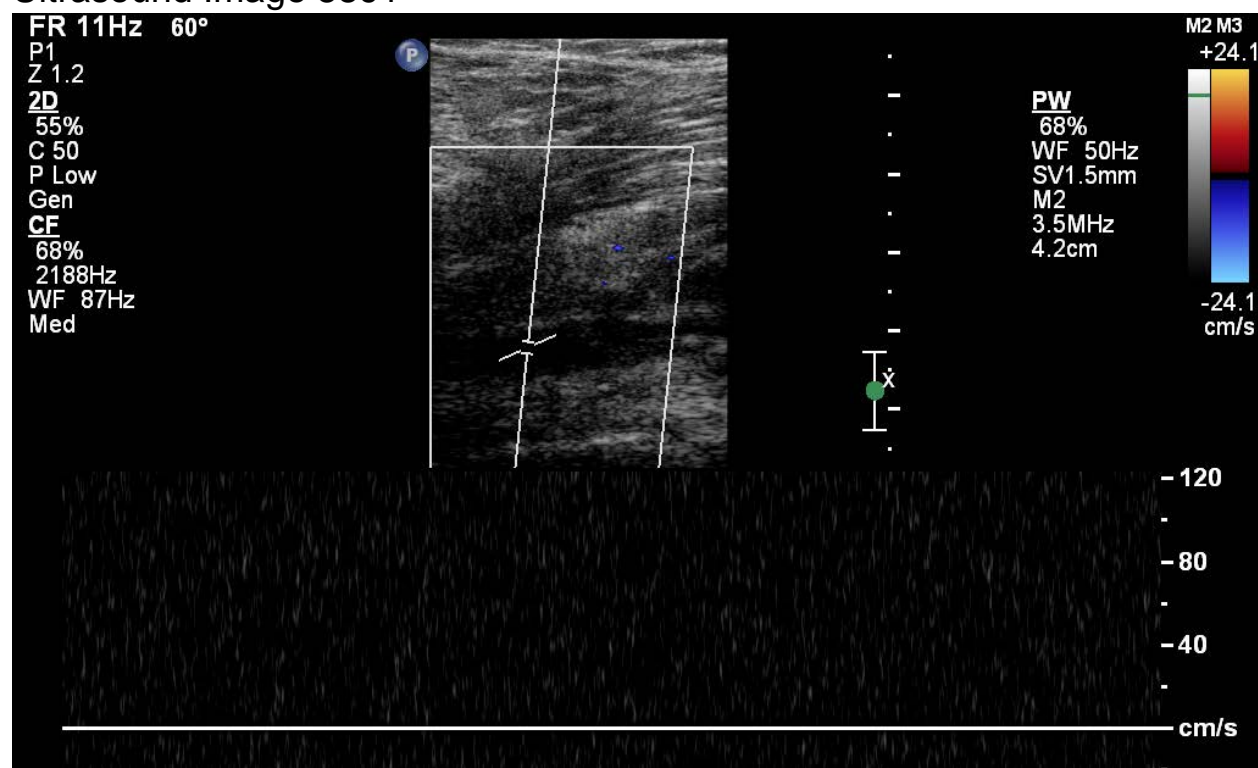
OCCLUSION, Pulsatile arterial flow is absent.

Ralph J Perrico III MD

E-signed 2016-06-01 04:10AM EDT
rjp@neomed.edu



Ultrasound Image 5891



Assessment for ultrasound image coded 5891

OCCLUSION, Pulsatile arterial flow is absent.

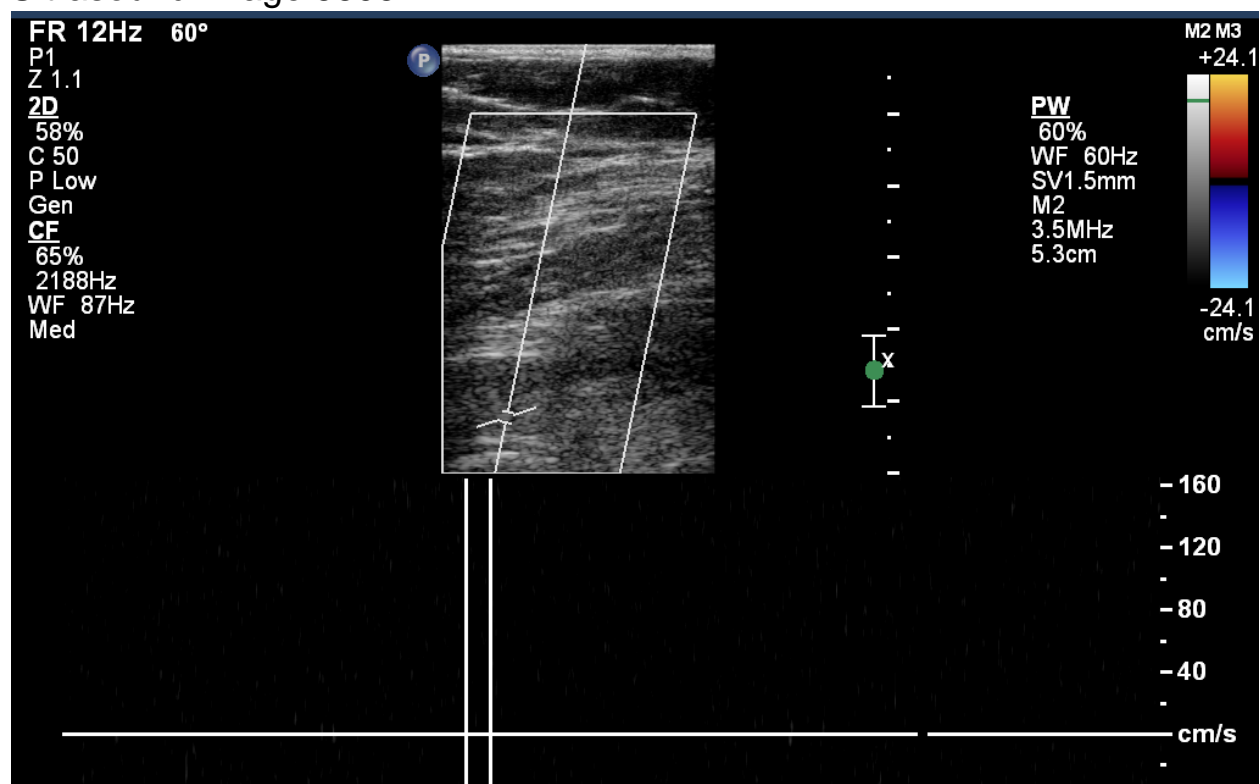
Ralph J Perrico III MD

E-signed 2016-06-01 04:10AM EDT

rjp@neomed.edu



Ultrasound Image 5893



Assessment for ultrasound image coded 5893

OCCLUSION, Pulsatile arterial flow is absent.

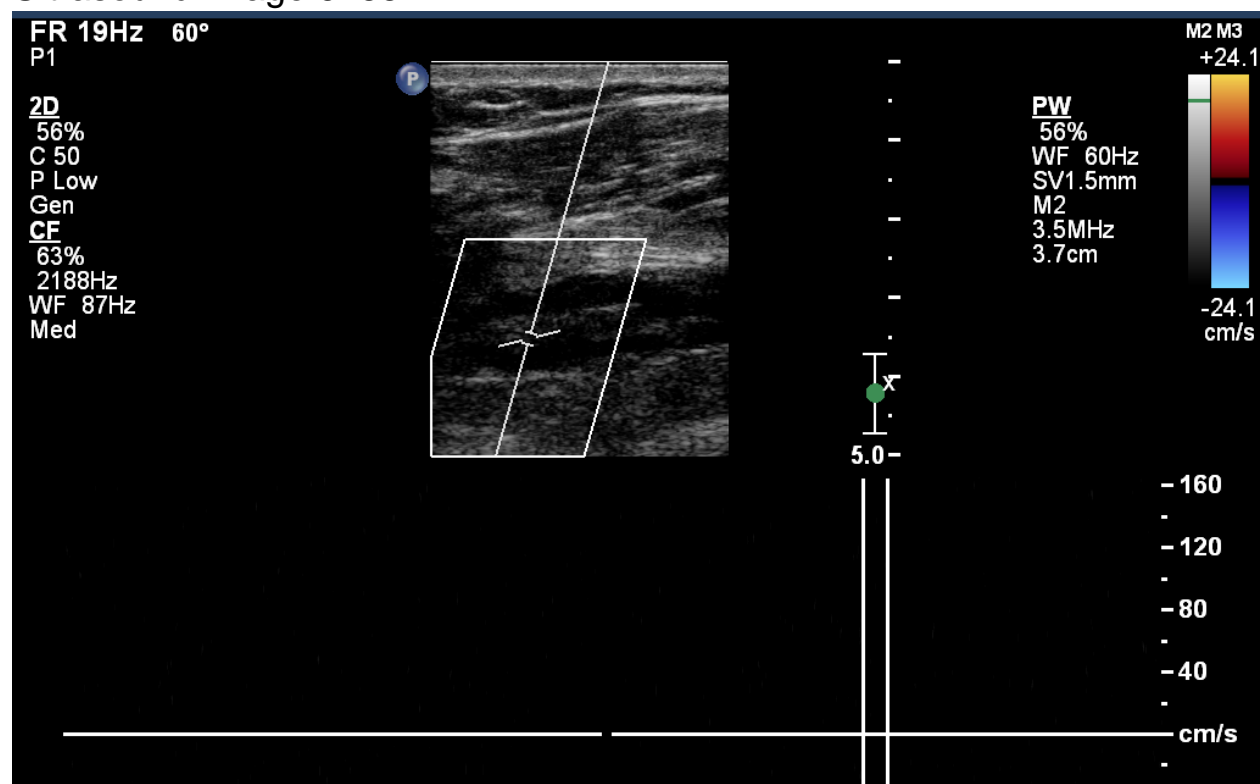
Ralph J Perrico III MD

E-signed 2016-06-01 04:10AM EDT

rjp@neomed.edu



Ultrasound Image 6188



Assessment for ultrasound image coded 6188

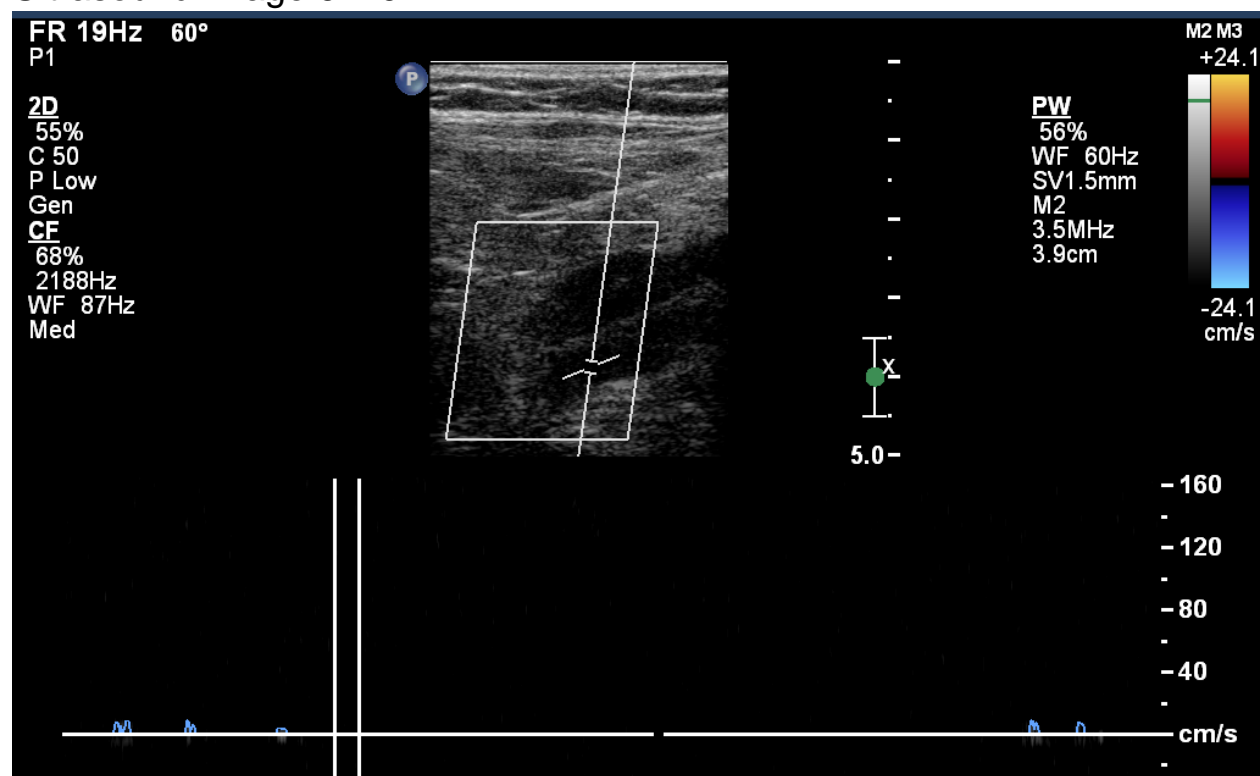
OCCLUSION, Pulsatile arterial flow is absent.

Ralph J Perrico III MD

E-signed 2016-06-01 04:10AM EDT
rjp@neomed.edu



Ultrasound Image 6279



Assessment for ultrasound image coded 6279

OCCLUSION, Pulsatile arterial flow is absent.

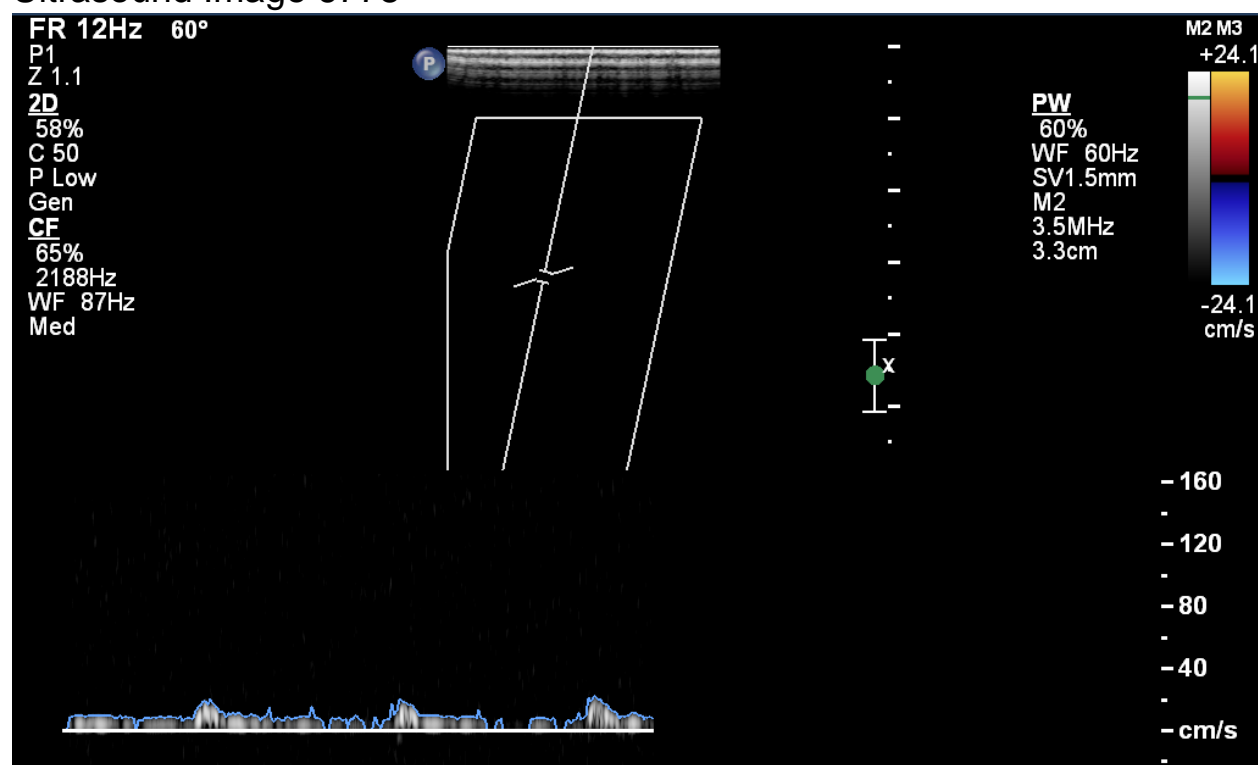
Ralph J Perrico III MD

E-signed 2016-06-01 04:10AM EDT

rjp@neomed.edu



Ultrasound Image 6778



Assessment for ultrasound image coded 6778

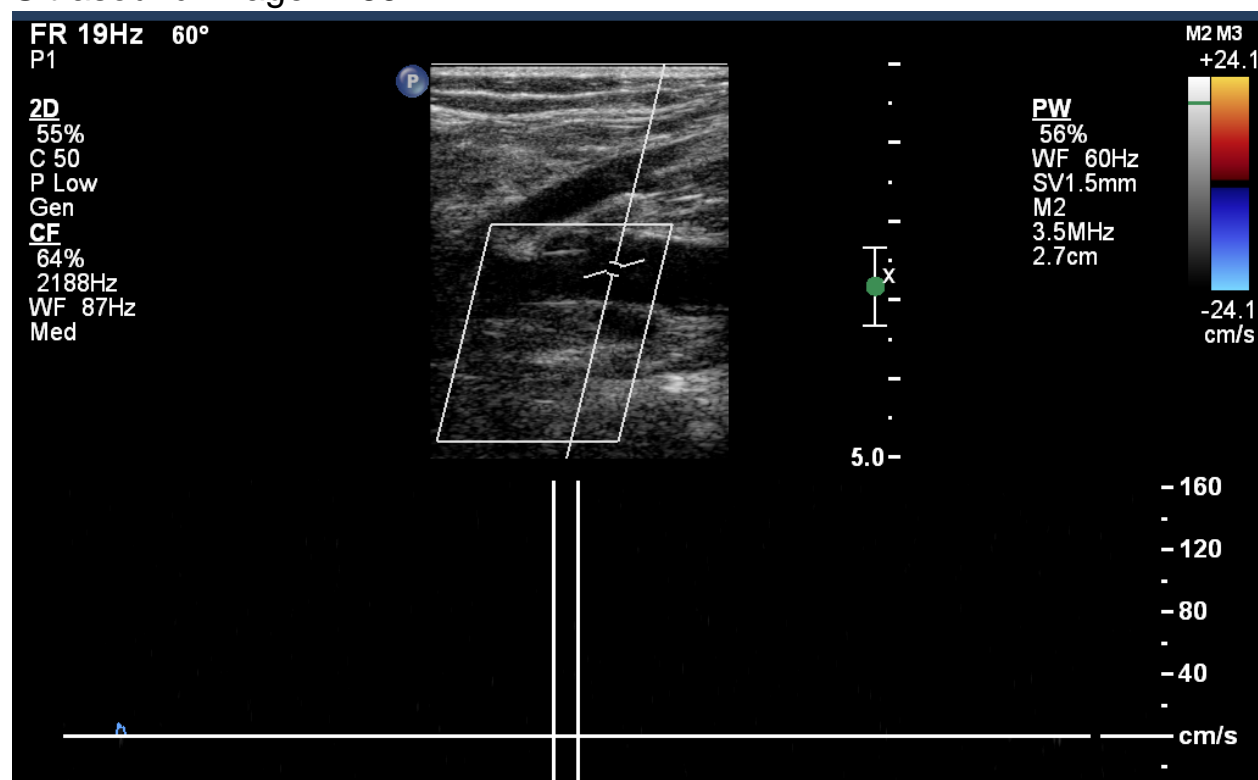
OCCLUSION, Pulsatile arterial flow is absent.

Ralph J Perrico III MD

E-signed 2016-06-01 04:10AM EDT
 rjp@neomed.edu



Ultrasound Image 7185



Assessment for ultrasound image coded 7185

OCCLUSION, Pulsatile arterial flow is absent.

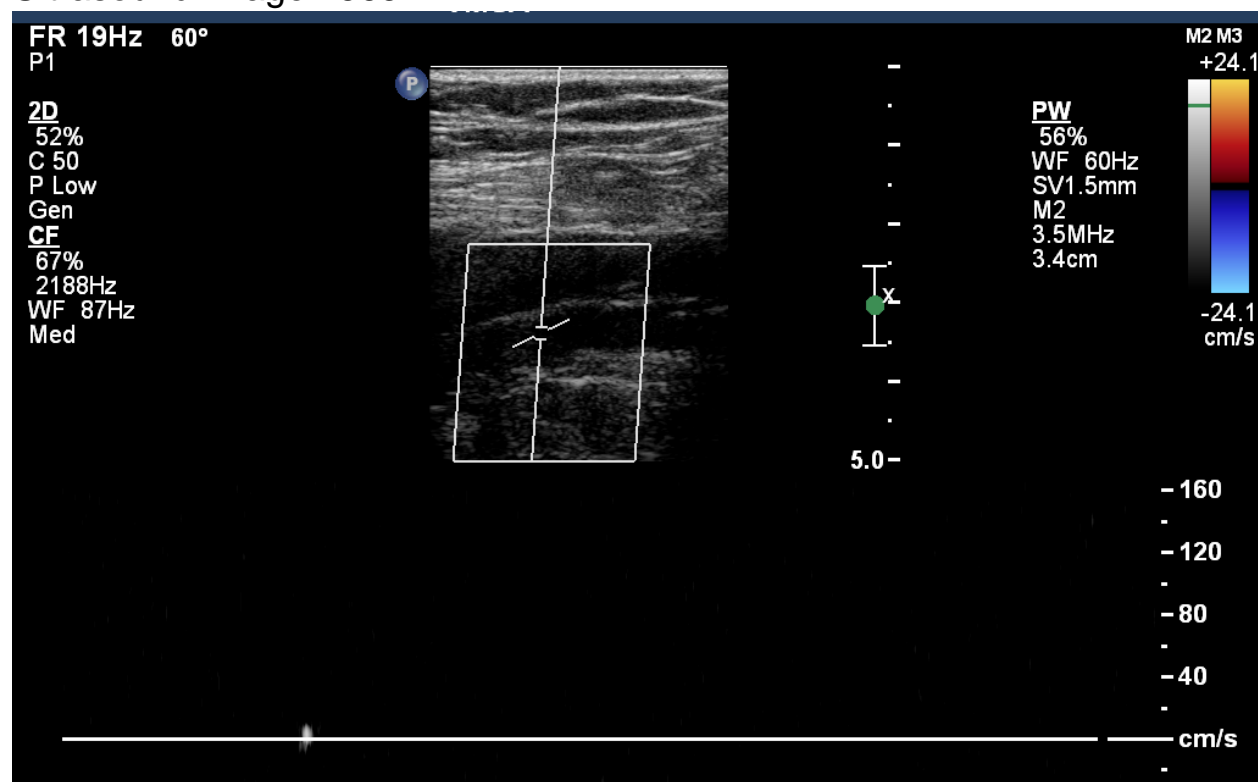
Ralph J Perrico III MD

E-signed 2016-06-01 04:10AM EDT

rjp@neomed.edu



Ultrasound Image 7365



Assessment for ultrasound image coded 7365

OCCLUSION, Pulsatile arterial flow is absent.

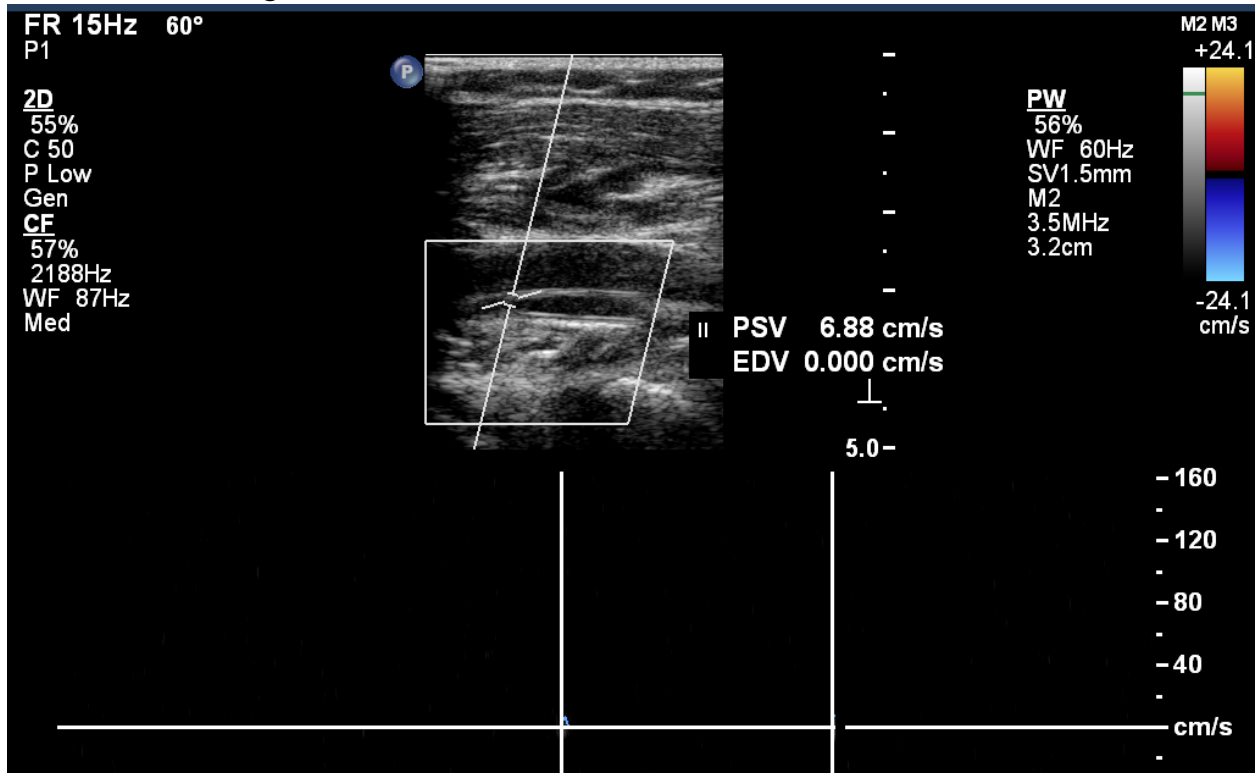
Ralph J Perrico III MD

E-signed 2016-06-01 04:10AM EDT

rjp@neomed.edu



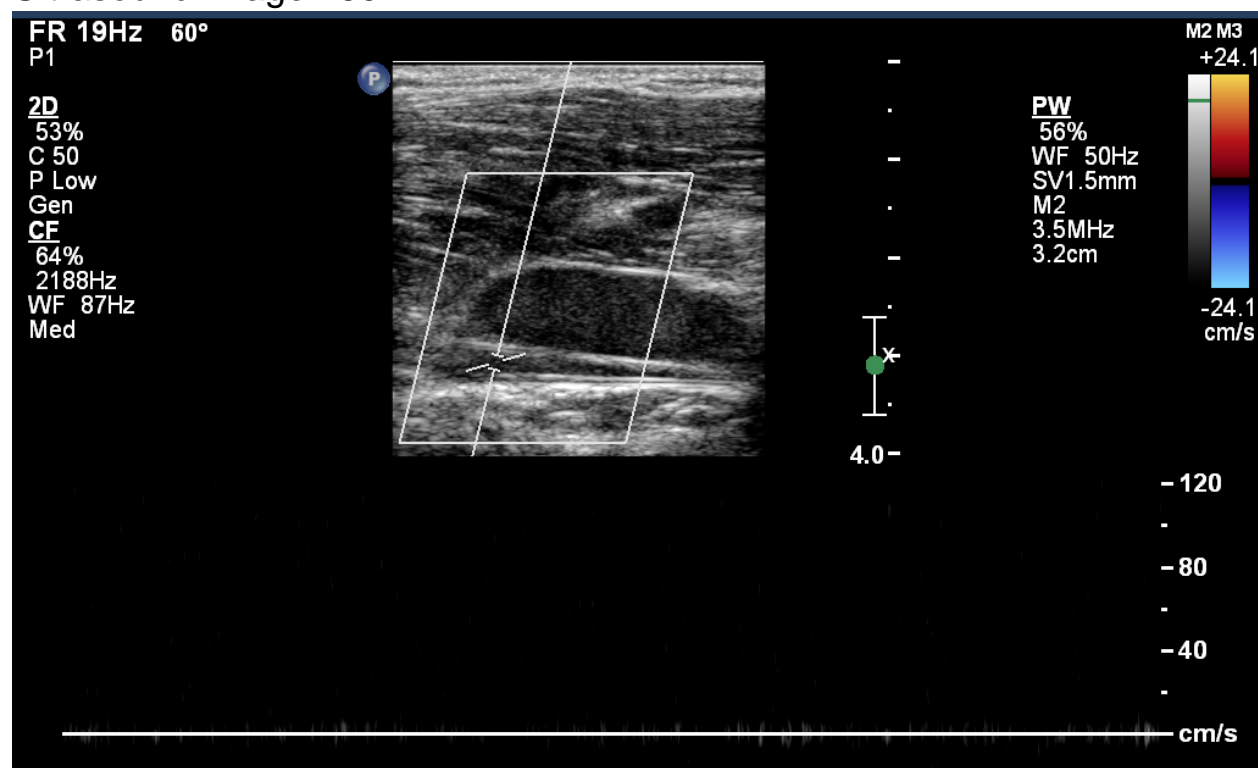
Ultrasound Image 7560



Assessment for ultrasound image coded 7560

OCCLUSION, Pulsatile arterial flow is absent.

Ultrasound Image 7601



Assessment for ultrasound image coded 7601

OCCLUSION, Pulsatile arterial flow is absent.

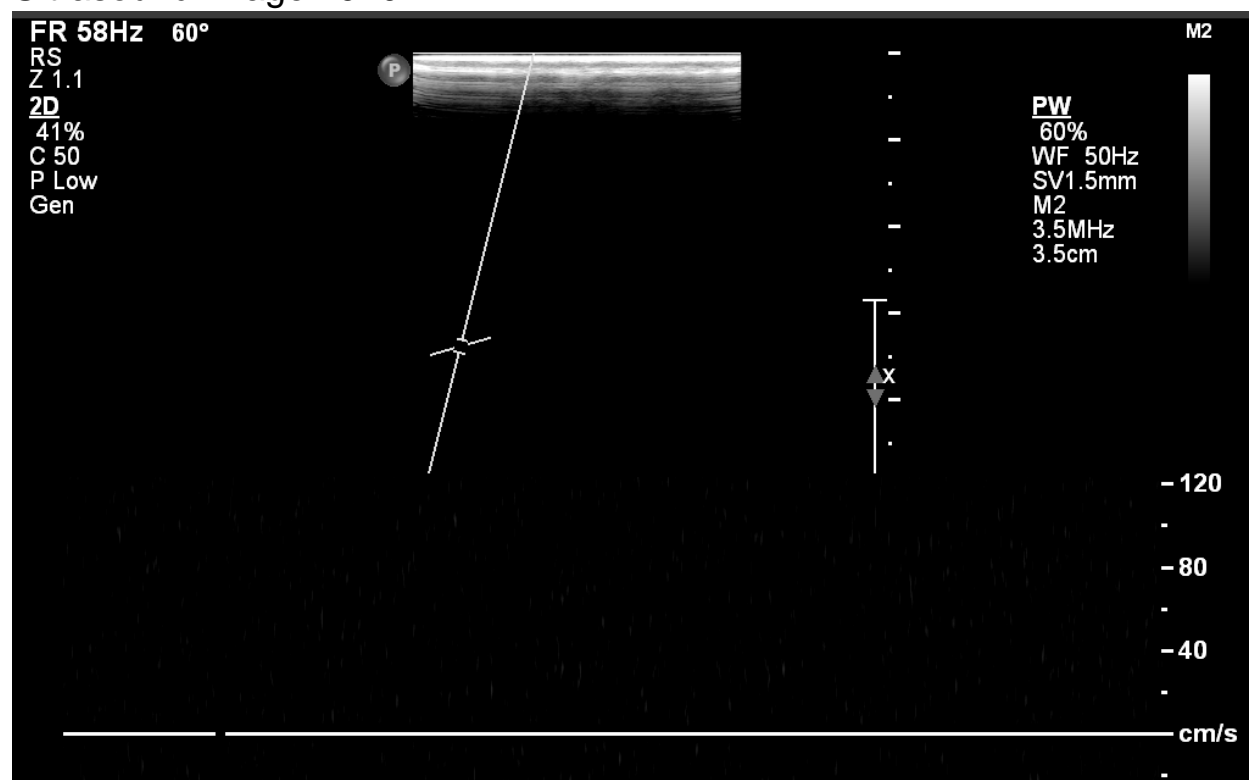
Ralph J Perrico III MD

E-signed 2016-06-01 04:10AM EDT

rjp@neomed.edu



Ultrasound Image 7910



Assessment for ultrasound image coded 7910

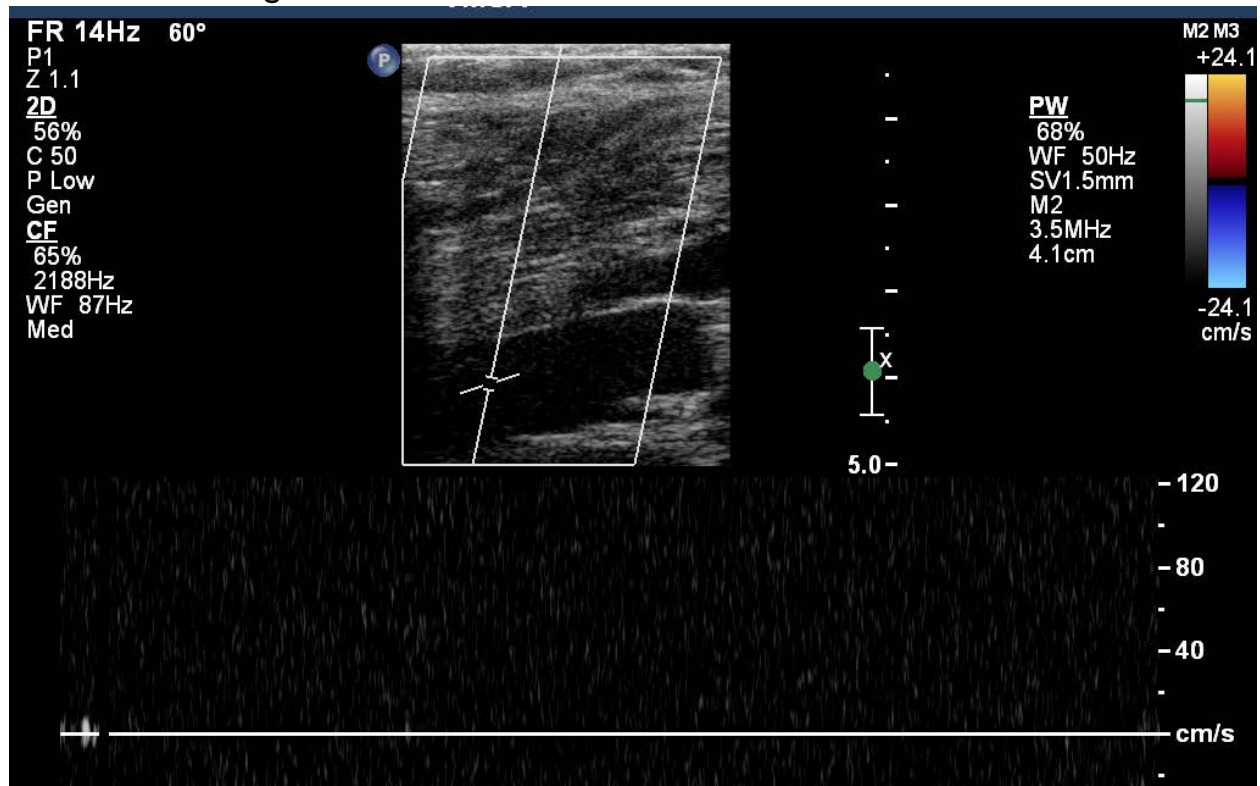OCCLUSION, Pulsatile arterial flow is absent.

Ralph J Perrico III MD

E-signed 2016-06-01 04:10AM EDT
 rjp@neomed.edu

xli

Ultrasound Image 8013



Assessment for ultrasound image coded 8013

OCCLUSION, Pulsatile arterial flow is absent.

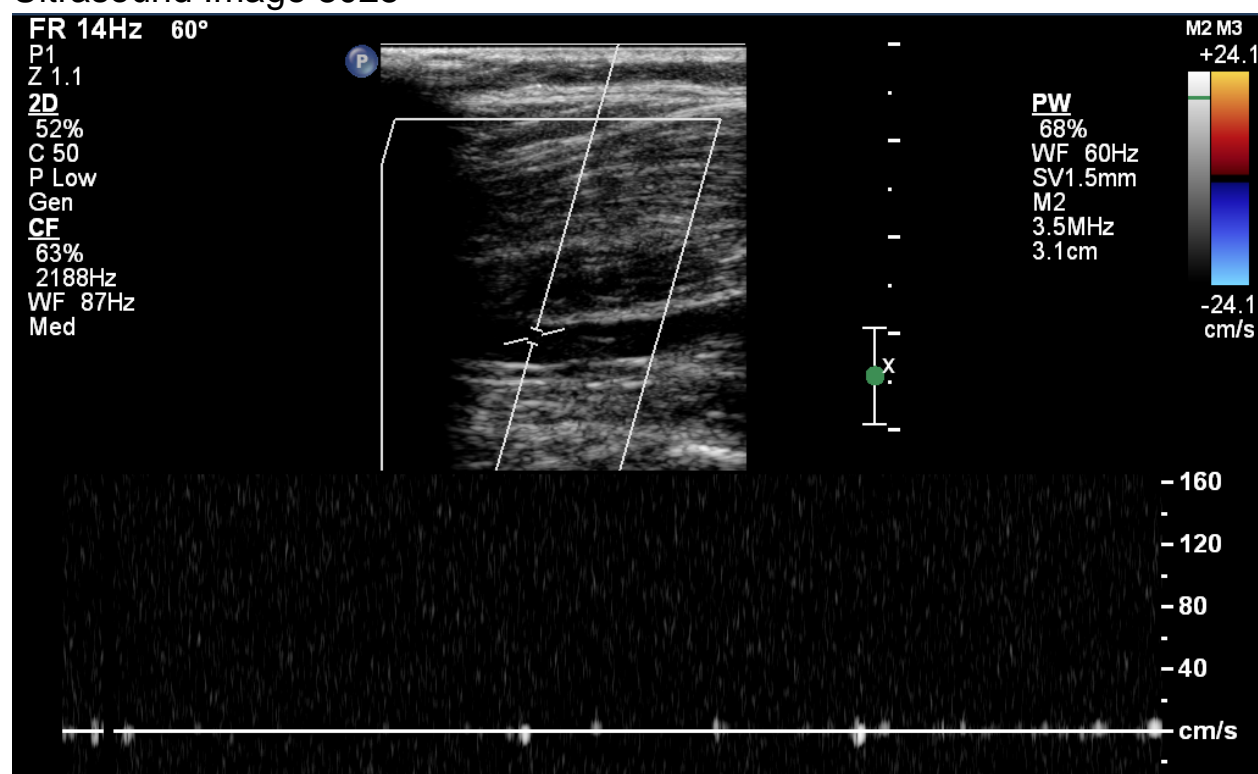
Ralph J Perrico III MD

E-signed 2016-06-01 04:10AM EDT

rjp@neomed.edu



Ultrasound Image 8025



Assessment for ultrasound image coded 8025

OCCLUSION, Pulsatile arterial flow is absent.

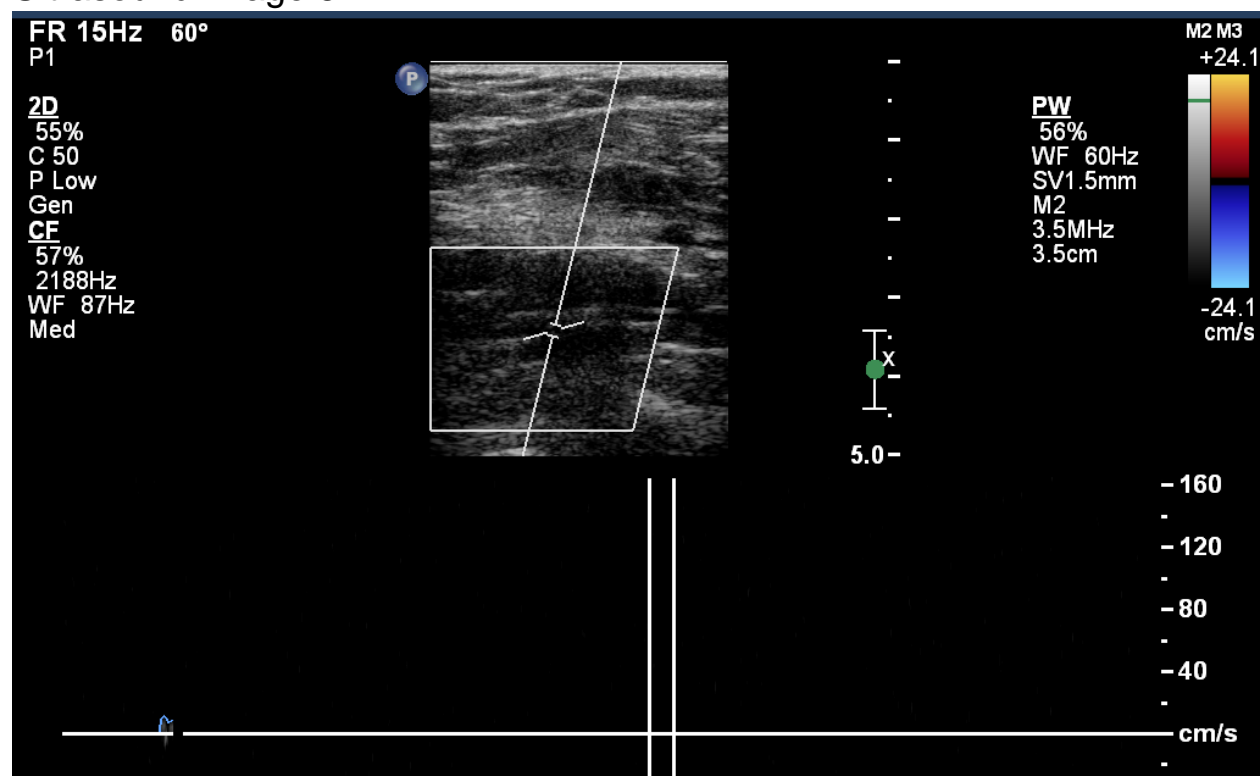
Ralph J Perrico III MD

E-signed 2016-06-01 04:10AM EDT

rjp@neomed.edu



Ultrasound Image 8227



Assessment for ultrasound image coded 8227

OCCLUSION, Pulsatile arterial flow is absent.

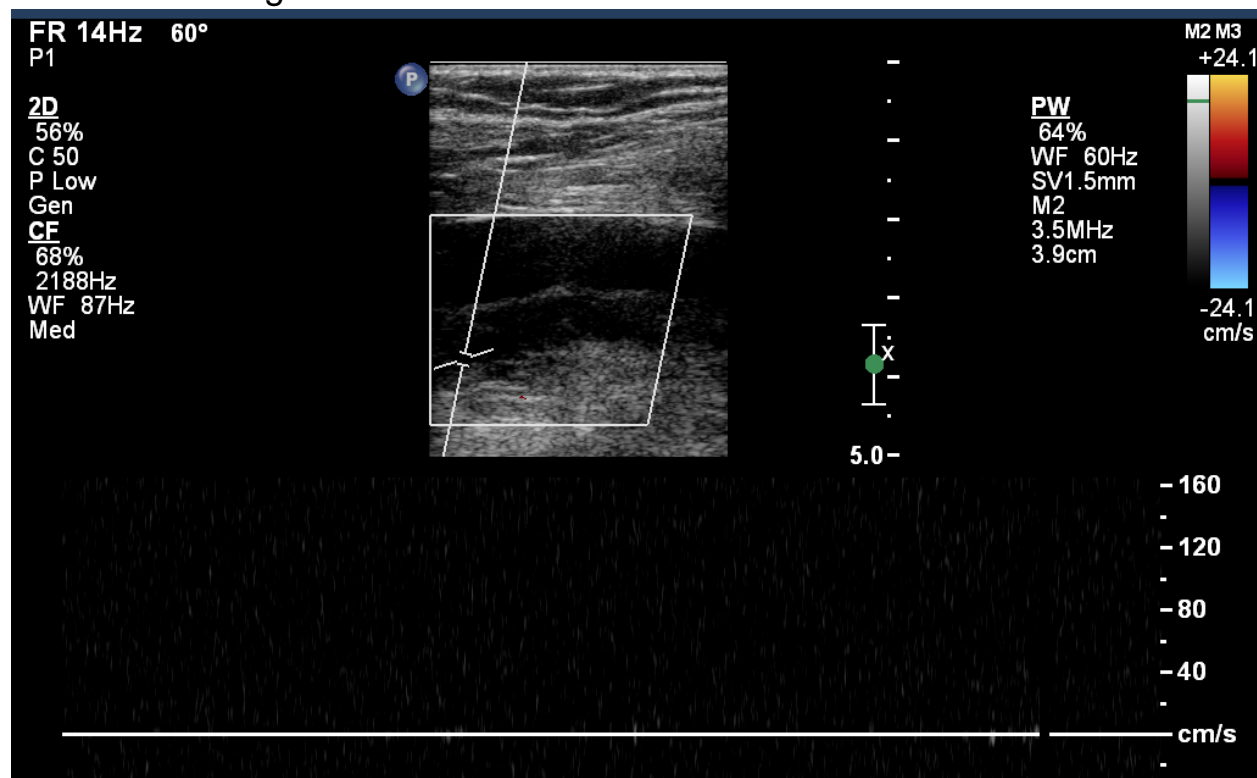
Ralph J Perrico III MD

E-signed 2016-06-01 04:10AM EDT

rjp@neomed.edu

xli

Ultrasound Image 8237



Assessment for ultrasound image coded 8237

OCCLUSION, Pulsatile arterial flow is absent.

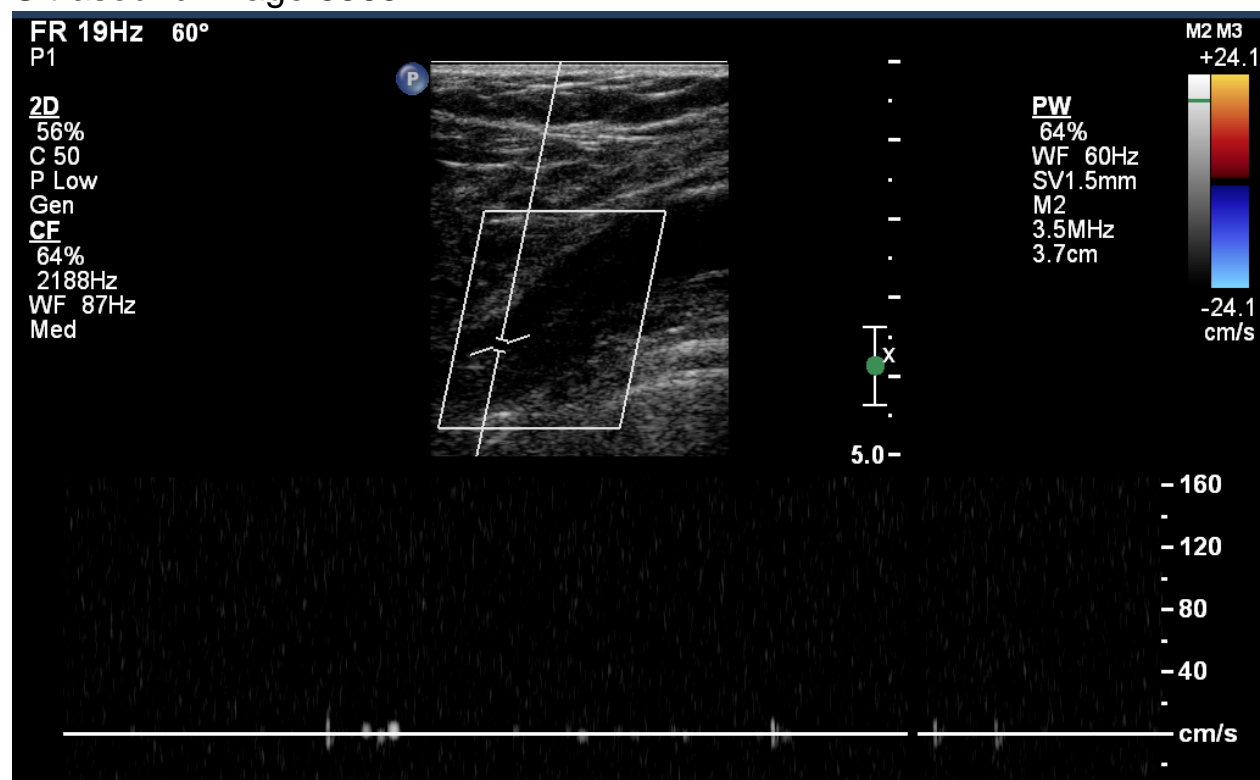
Ralph J Perrico III MD

E-signed 2016-06-01 04:10AM EDT

rjp@neomed.edu



Ultrasound Image 8365



Assessment for ultrasound image coded 8365

OCCLUSION, Pulsatile arterial flow is absent.

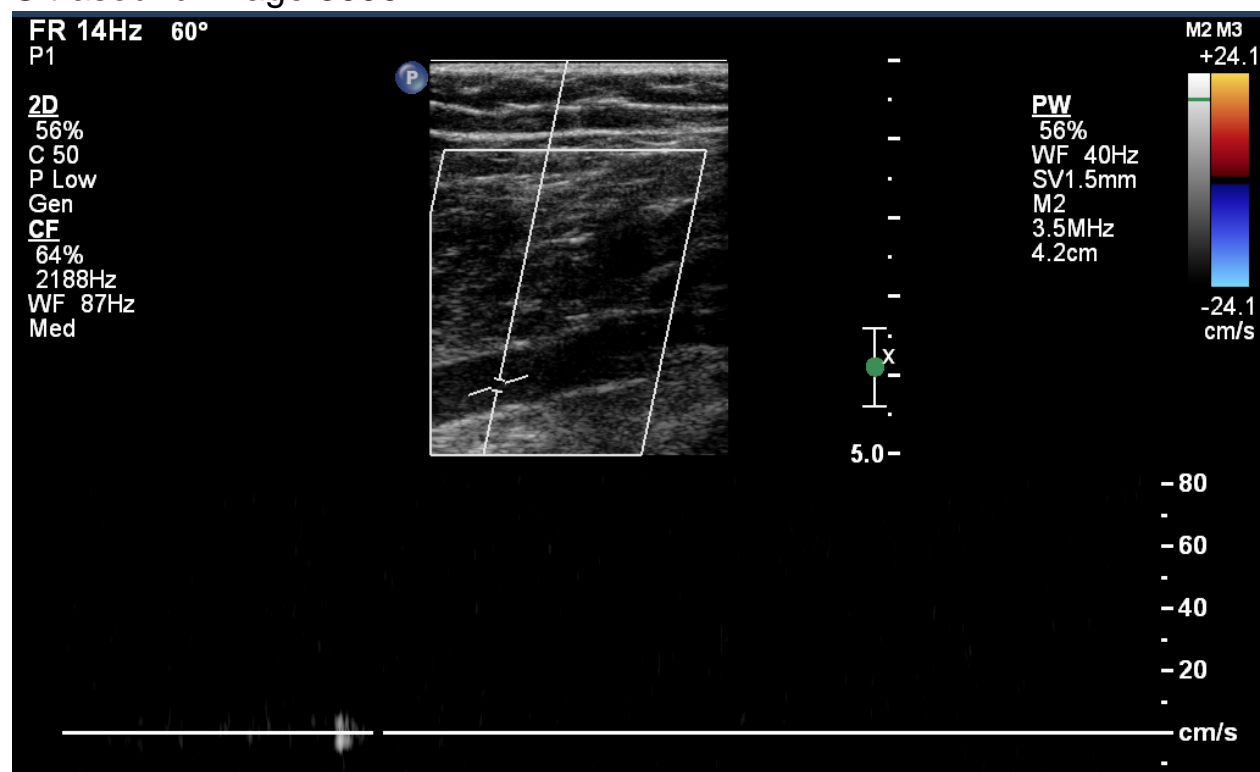
Ralph J Perrico III MD

E-signed 2016-06-01 04:10AM EDT

rjp@neomed.edu



Ultrasound Image 8656



Assessment for ultrasound image coded 8656

OCCLUSION, Pulsatile arterial flow is absent.

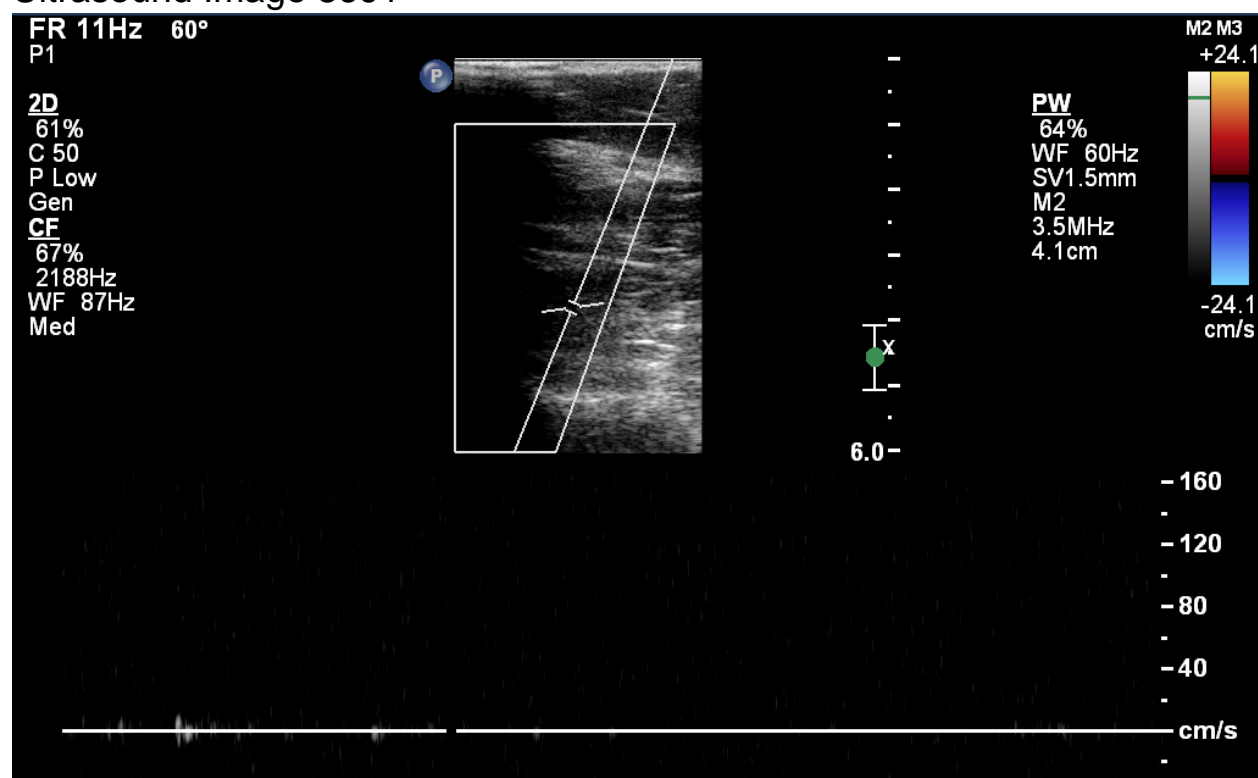
Ralph J Perrico III MD

E-signed 2016-06-01 04:10AM EDT

rjp@neomed.edu



Ultrasound Image 8691



Assessment for ultrasound image coded 8691

OCCLUSION, Pulsatile arterial flow is absent.

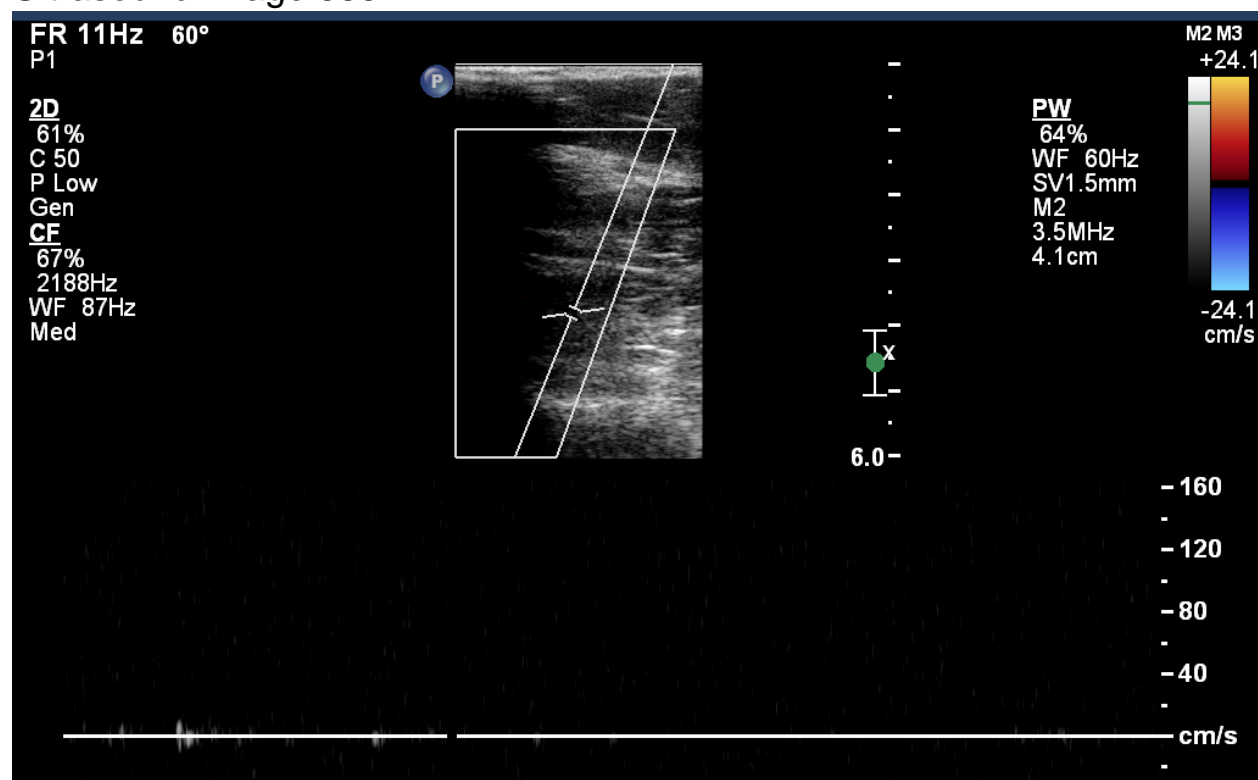
Ralph J Perrico III MD

E-signed 2016-06-01 04:10AM EDT

rjp@neomed.edu



Ultrasound Image 8857



Assessment for ultrasound image coded 8857

OCCLUSION, Pulsatile arterial flow is absent.

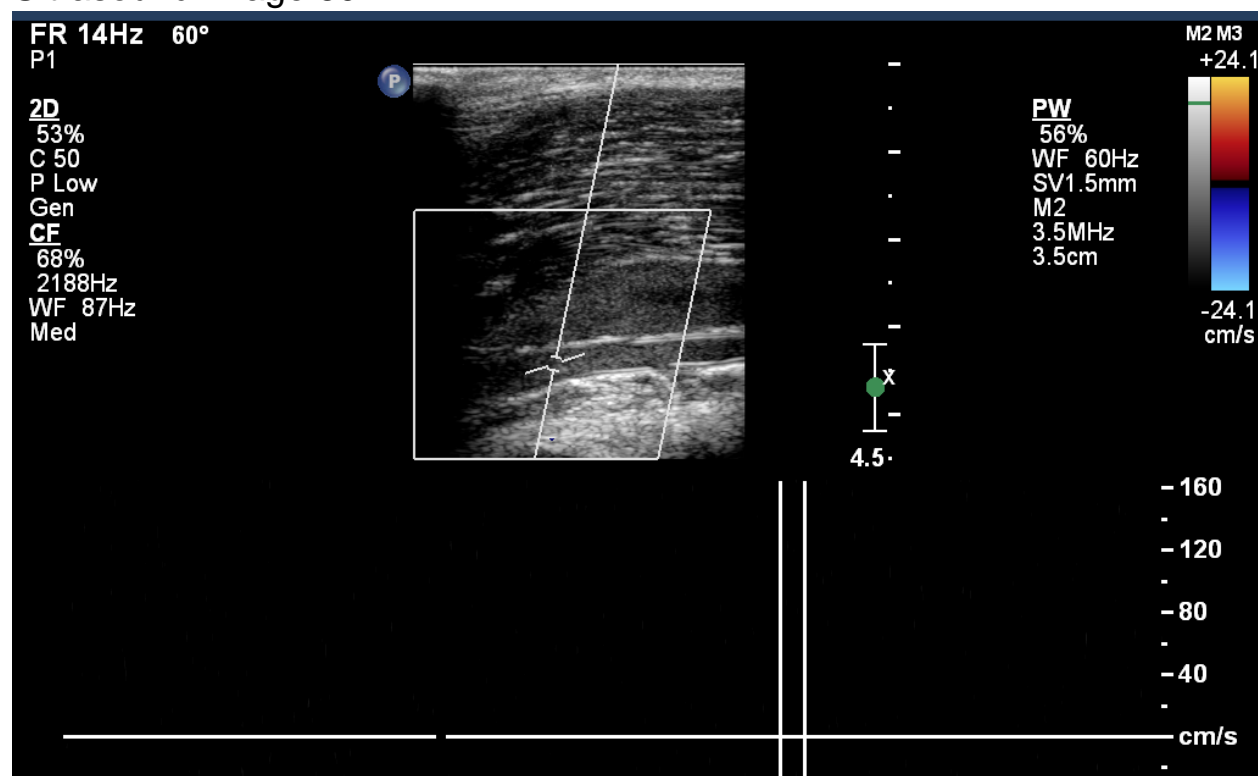
Ralph J Perrico III MD

E-signed 2016-06-01 04:10AM EDT

rjp@neomed.edu



Ultrasound Image 8947



Assessment for ultrasound image coded 8947

OCCLUSION, Pulsatile arterial flow is absent.

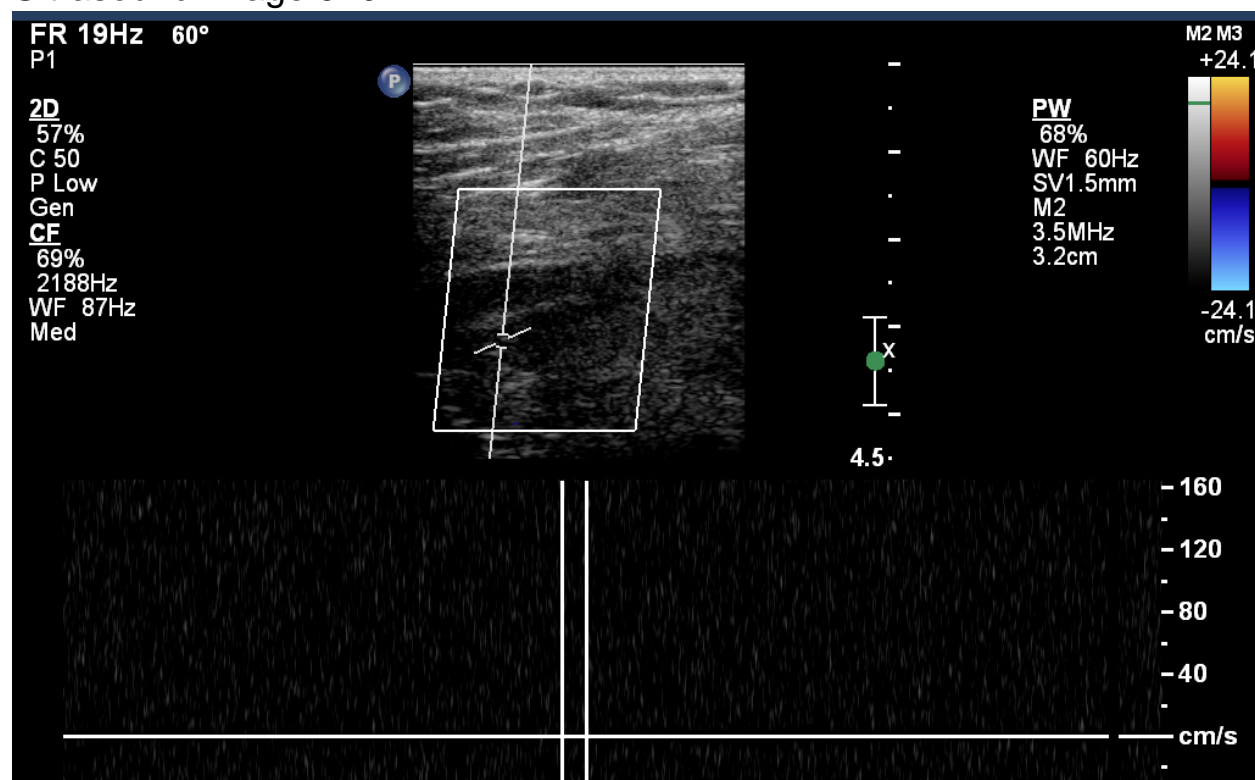
Ralph J Perrico III MD

E-signed 2016-06-01 04:10AM EDT

rjp@neomed.edu



Ultrasound Image 9207



Assessment for ultrasound image coded 9207

OCCLUSION, Pulsatile arterial flow is absent.

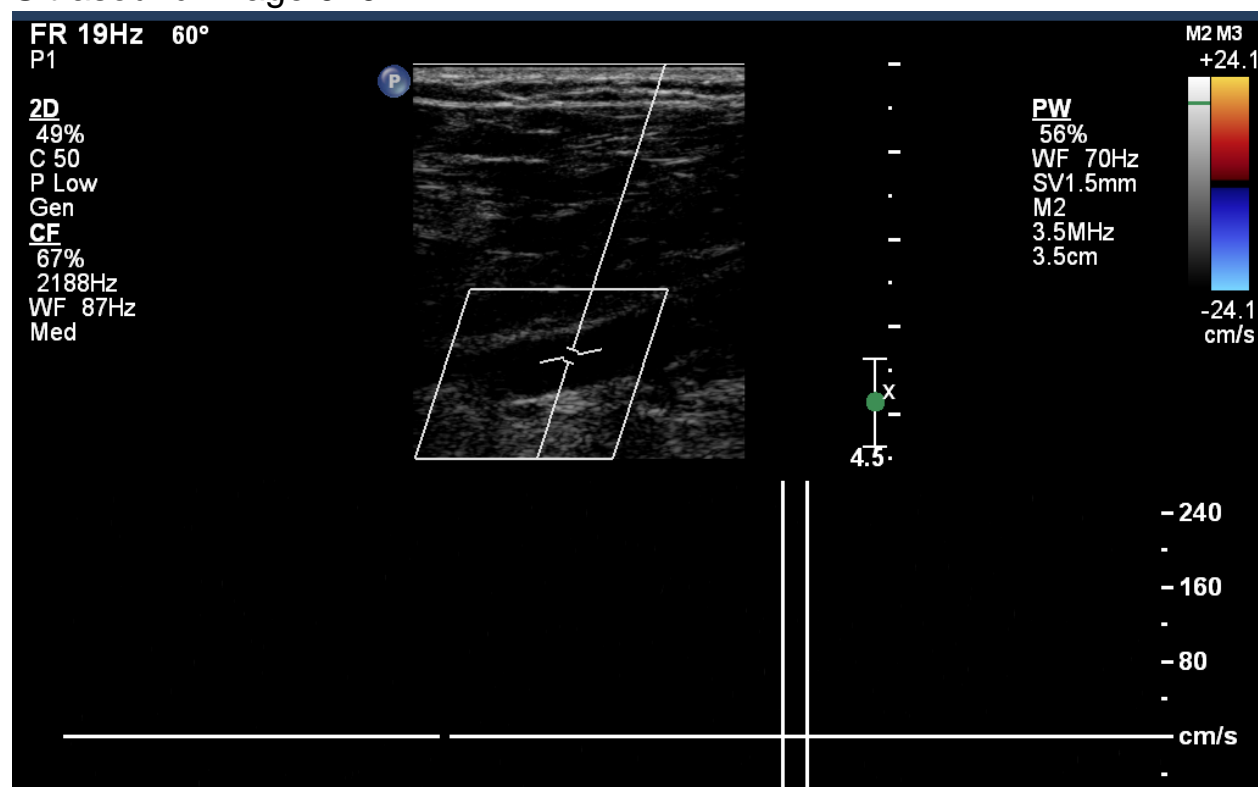
Ralph J Perrico III MD

E-signed 2016-06-01 04:10AM EDT

rjp@neomed.edu



Ultrasound Image 9292



Assessment for ultrasound image coded 9292

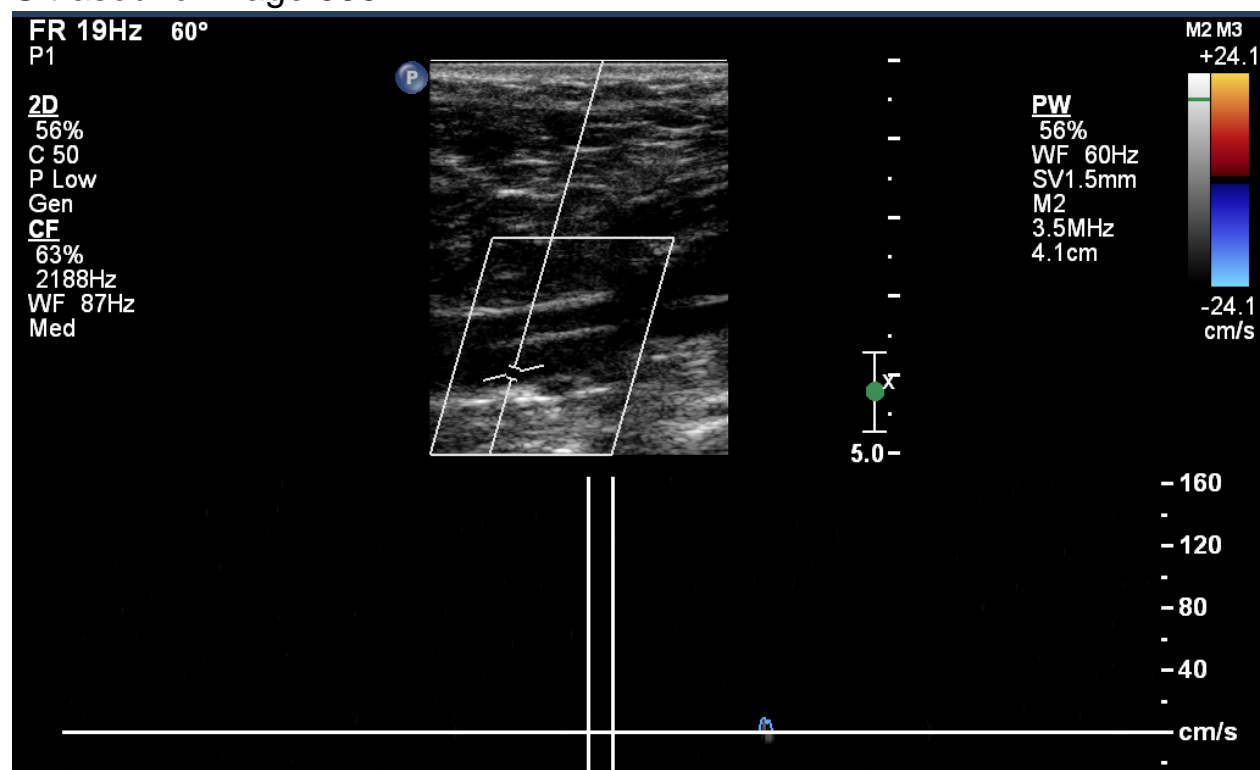
OCCLUSION, Pulsatile arterial flow is absent.

Ralph J Perrico III MD

E-signed 2016-06-01 04:10AM EDT
rjp@neomed.edu

xli

Ultrasound Image 9331



Assessment for ultrasound image coded 9331

OCCLUSION, Pulsatile arterial flow is absent.

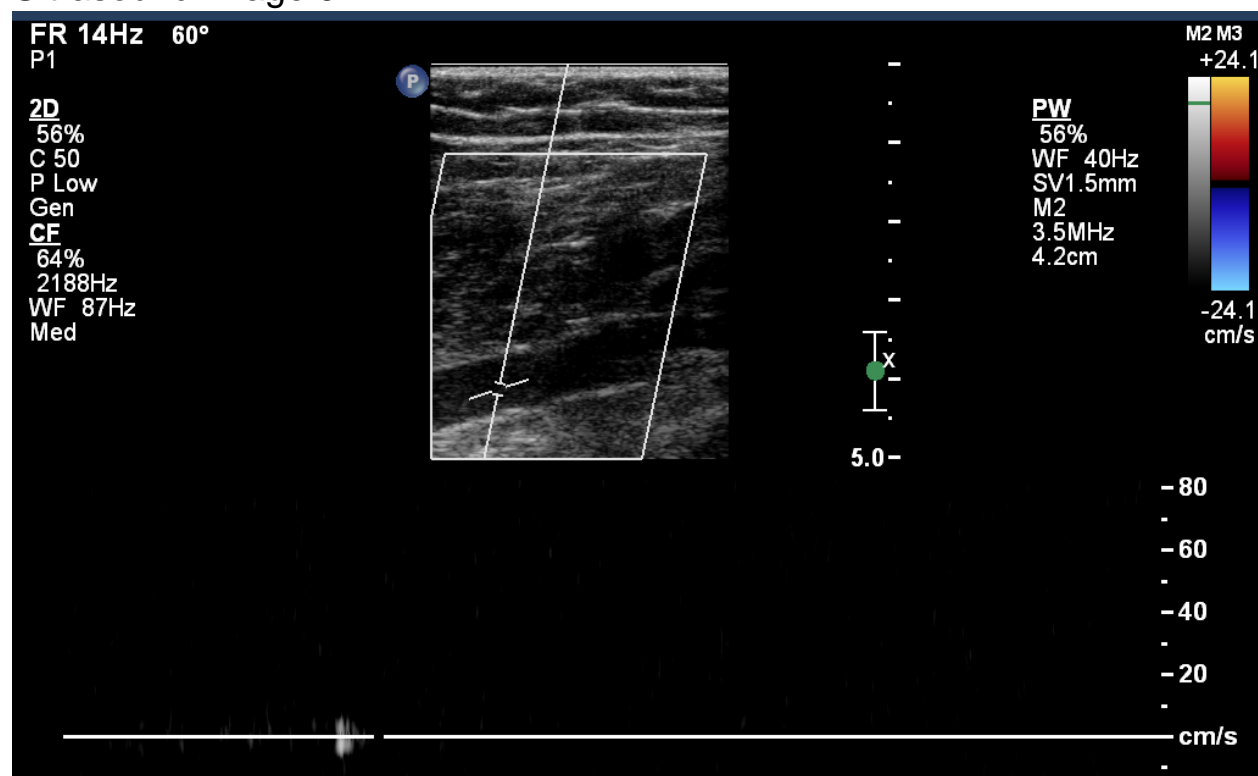
Ralph J Perrico III MD

E-signed 2016-06-01 04:10AM EDT

rjp@neomed.edu



Ultrasound Image 9427



Assessment for ultrasound image coded 9427

OCCLUSION, Pulsatile arterial flow is absent.

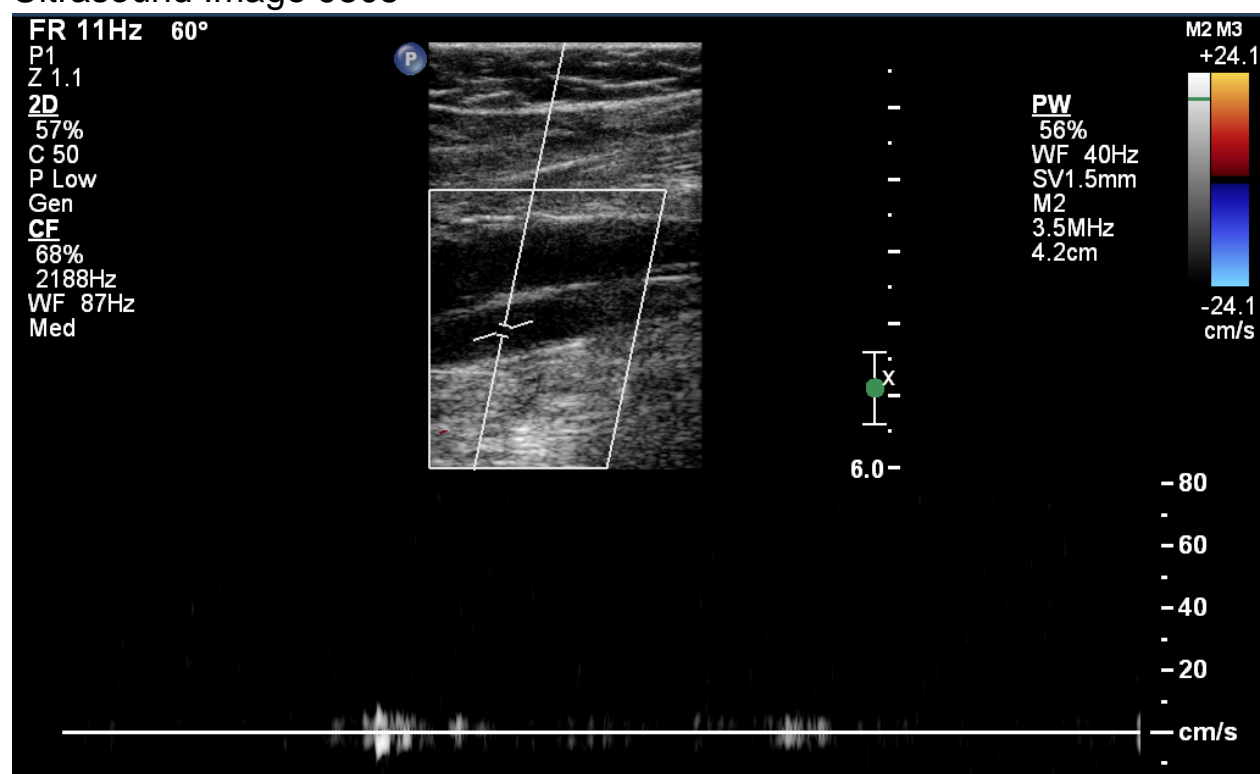
Ralph J Perrico III MD

E-signed 2016-06-01 04:10AM EDT

rjp@neomed.edu



Ultrasound Image 9805



Assessment for ultrasound image coded 9805

OCCLUSION, Pulsatile arterial flow is absent.

Ralph J Perrico III MD

E-signed 2016-06-01 04:10AM EDT
rjp@neomed.edu



PrimaryOutcome201505210910

Adobe Sign Document History

06/01/2016

NCT02592655 Primary Outcome Tourniquet Study

Instructions to the outcome assessor:

You have been blinded to this study. The identity of the subject, the identity of intervention, and the sequence of the intervention have been intentionally concealed from you. Ultrasound images have been labeled with a four-digit blinding code. As the outcome assessor, you are asked to evaluate each ultrasound image as being indicative of the presence or absence of pulsatile arterial flow.

Below each image, you are asked to select one of the following options.

- FLOW: Pulsatile arterial flow is present.
- OCCUSION: Pulsatile arterial flow is absent.

A free text box accompanies each image for optional comments.

Outcome Assessor Information and Signature

Created: 05/23/2016

By: Marcus Migura (migura@cryptoheaven.com)

Status: SIGNED

Transaction ID: CBJCHBCAABAApZA3dC2kfLt6y7HBISEbMg2FU4tWDGN

“PrimaryOutcome201505210910” History



Document created by Marcus Migura (migura@cryptoheaven.com)

05/23/2016 - 9:20:33 EDT - IP address: 50.175.241.228



Document emailed to Ralph J Perrico III MD (rjp@neomed.edu) for signature

05/23/2016 - 9:21:39 EDT



Document viewed by Ralph J Perrico III MD (rjp@neomed.edu)

06/01/2016 - 3:47:41 EDT - IP address: 66.249.85.191



Document e-signed by Ralph J Perrico III MD (rjp@neomed.edu)

Signature Date: 06/01/2016 - 4:10:53 EDT - Time Source: server - IP address: 24.144.144.54



Signed document emailed to Ralph J Perrico III MD (rjp@neomed.edu) and Marcus Migura (migura@cryptoheaven.com)

06/01/2016 - 4:10:53 EDT



Adobe Sign