

Histopathological Alterations in *Vimba* sp. Gills as Biomarkers of Freshwater Quality in the Veleka River, Bulgaria

STELA STOYANOVA¹, VESELA YANCHEVA*², ELENKA GEORGIEVA¹

¹Paisii Hilendarski University of Plovdiv, Faculty of Biology, Department of Developmental Biology, 24 Tsar Assen Str., 4000 Plovdiv, Bulgaria

²Paisii Hilendarski University of Plovdiv, Faculty of Biology, Department of Ecology and Environmental Conservation, 24 Tsar Assen Str., 4000 Plovdiv, Bulgaria, *vyancheva@uni-plovdiv.bg

Abstract. In the present research, we evaluated the alterations in the histological structure of *Vimba* sp. gills as a biomarker of freshwater quality. Fish were collected from the Veleka River. Based on the obtained results, we established the highest degree of proliferative changes. These alterations concerned mainly the covering epithelium of the secondary lamellae and proliferation of the cells in the cartilage tissue (chondrocytes). Overall, the study emphasizes the importance of biomonitoring in natural ecosystems in order to assess the health of native fish and hence the quality of surface waters.

Keywords: histopathology, fish, gills.

Introduction

Most environmental contamination of natural ecosystems is caused by human activities such as industrial emissions, mining, and agricultural practices, such as the use of different contaminants (Kumar *et al.* 2024). In this regard, the aquatic environments, as final recipients of numerous contaminants, are exposed to inorganic, organic, microbiological, and pharmaceutical contaminants. Their effect could be evaluated by analyses of different biomarkers, such as histopathological alterations in fish target organs, along with the chemical analyses of surface waters. Histopathological changes in target fish organs have a high significance in aquatic toxicology, and they could be applied in the aquatic ecosystem monitoring (Marinović *et al.* 2021). Among them, gills are particularly useful in environmental monitoring, given the fact that they have a large surface area, thin epithelium, and are in direct contact with water (Kumar *et al.* 2024). Moreover, histopathological methods could be successfully included in the aquatic ecosystem monitoring of contaminant effects, but also to assess changes in the abiotic factors, as this method provides an opportunity for the detection and quantification of lesions that occur in selected target organs of bioindicator organisms (Sihoka *et al.* 2024). The Veleka River is the largest and longest in Strandzha Nature Park in Bulgaria. Currently, there is no information concerning the histological structure of fish from the Veleka River under the influence of pollution or environmental factors.

Therefore, the main aim of this present research was to evaluate the alterations in the histological structure of *Vimba* sp. gills as a biomarker of freshwater quality. To our knowledge, no prior studies have examined this topic.

Materials and Methods

Fish were collected from the Veleka River, located in the Strandzha Mountain region of Bulgaria. We used *Vimba sp.* and proposed it as a bioindicator for water quality (Minaz *et al.*, 2023). Fish (n=10) were dissected, complying with the requirements for the humane treatment of experimental animals according to EU legislation. The histological processing was performed according to the standard procedure, and staining of Romeis (1989) and the alterations in the gills were scored according to Bernet *et al.* (1999).

Results and Discussion

The normal gill histological structure includes filaments (primary lamellae) arranged in double rows. A thick stratified epithelium covers the primary epithelium. A squamous epithelium lines the secondary lamellae. Below the epithelium, lamellar blood sinuses are located, separated by pillar cells (Laurent & Perry 1995). The obtained results showed that the circulatory disturbances were expressed mainly in a mild degree of expression (Table 1). Only vasodilatation in the filament was observed to a moderate degree (Figure 1C). Overall, the index for circulatory disturbances was calculated as 5. On the other hand, the degenerative changes (Table 1, Figure 1B) were detected in a mild degree of expression, but the index for degenerative alterations showed a score of 6. The proliferative changes, which can be considered as compensatory-adaptive mechanisms, were observed in a higher degree of expression (Table 1). We found edema, proliferation of the secondary lamellae, and proliferation of chondrocytes in a moderate degree of expression (Figure 1A, B). Fusion, with a severe degree of proliferative changes, was not observed in the fish gills. These alterations were classified as Class IV, indicating a severe degree of change in the gill structure. Based on the obtained results, we established the highest degree of lesions for the proliferative changes. These alterations concerned mainly the covering epithelium of the secondary lamellae and proliferation of the cells in the cartilage tissue (chondrocytes). We agree with the statement that the progressive changes in fish gills, such as hyperplasia and hypertrophy of epithelial cells, could be considered as a general safety mechanism against toxicants in water (Marinović *et al.* 2021). In addition, the intense proliferation could increase the distance between the external environment and the blood and also could serve as a barrier to the entrance of different toxicants. The higher degree of proliferation indicates intense compensatory-adaptive mechanisms in the fish organism, probably influenced by environmental factors. Sihoka *et al.* (2024) added that the additional protective mechanism could be the hyperplasia of mucous cells, which secrete mucus in order to establish a protective barrier over the gill epithelium. Along with proliferative changes, we also found degenerative alterations in small areas, expressed in the process of necrosis, concerning the stratified epithelium. Similarly, Carvalho *et al.* (2020) found intense necrosis in the gills' structure along with the epithelial lifting and aneurysm in the blood vessels in *Menticirrhus americanus* and *Micropogonias furnieri* collected from Paraty and Sepetiba bays in Rio de Janeiro.

The study is the first to report histological alterations in fish from the Veleka River and emphasizes the importance of biomonitoring in local natural ecosystems in order to assess both fish health and the quality of surface waters. Morphological methods can be successfully applied for diagnostic purposes in water monitoring programs.

Acknowledgements. This work was supported by the European Union-NextGenerationEU, through the National Recovery and Resilience Plan of the Republic of Bulgaria, project № BG-RRP-2.004-0001-C01.

Table 1. Histopathological alterations in *Vimba sp.* gills from the Veleka River, Bulgaria.

Reaction Pattern	Functional Unit of the Tissue	Alteration	Importance Factor (W)	Degree of the alterations - Score Value
Circulatory disturbances	<i>Primary Lamellae (filament)</i>	Vasodilation	$W_{GC1} = 1$	3
	<i>Secondary lamellae</i>	Vasodilation	$W_{GC2} = 1$	1
	<i>Filament/Secondary lamellae</i>	Aneurysms	$W_{GC3} = 2$	1
Index for circulatory disturbances				I_{GC} = 5
Degenerative alterations	<i>Epithelium of primary lamellae</i>	Necrosis	$W_{GR1} = 3$	1
	<i>Epithelium of secondary lamellae</i>	Necrosis	$W_{GR2} = 3$	1
Index for degenerative alterations				I_{GR} = 6
Proliferative alterations	<i>Epithelium of primary lamellae</i>	Edema	$W_{GP1} = 1$	3
		Proliferation of stratified epithelium	$W_{GP2} = 2$	1
		Proliferation of glandular cells	$W_{GP3} = 1$	0
		Fusion	$W_{GP4} = 3$	0
	<i>Epithelium of secondary lamellae</i>	Lamellar lifting	$W_{GP5} = 1$	2
		Proliferation	$W_{GP6} = 2$	3
	<i>Cartilage tissue</i>	Proliferation of chondrocytes	$W_{GP7} = 2$	3
Index for proliferative alterations				I_{GP} = 19
Index organ I_G				I_G = 30

(0) – no changes in the gills histological structure; (1) – very mild changes in the gills histological structure; (2) – mild degree of changes in the gills histological structure; (3) – moderate degree of changes in the gills histological structure; (4) – severe degree of changes in the gills histological structure; (5) – very severe degree of changes in the in the gills histological structure

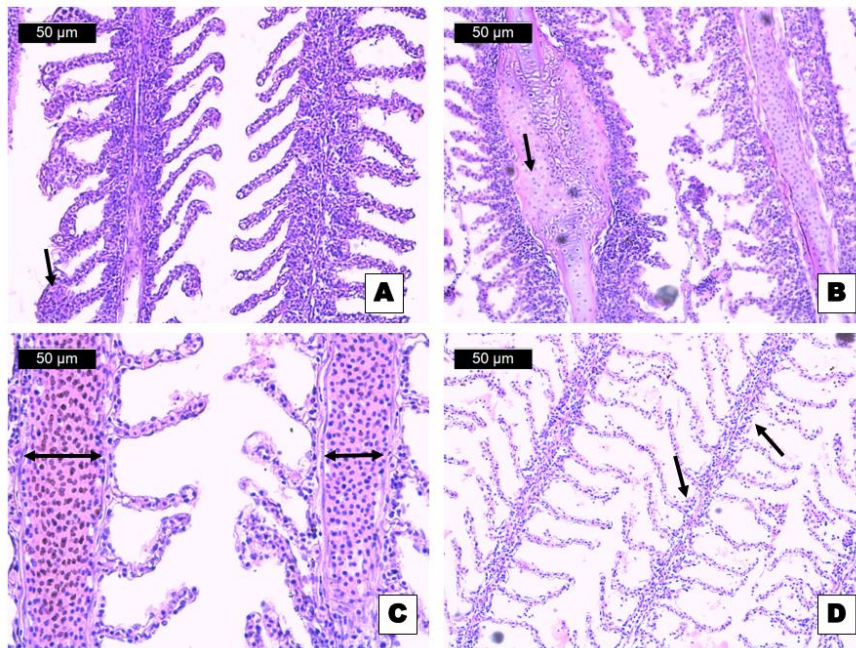


Figure 1. Histopathological alterations in *Vimba sp.* gills, H&E: A – proliferation in the secondary lamellae; B – proliferation of the cartilage tissue; C – vasodilation; D – necrosis.

References

- Bernet, D., Schmidt, H., Meier, W., Burkhardt-Holm, P. & Wahli, T. (1999) Histopathology in fish: proposal for a protocol to assess aquatic pollution. *The Journal of Fish Disease*, 22: 25-34
- Carvalho, T.L.A., Nascimento, A.A., Gonçalves, C.F.S., Santos, M.A.J. & Sales, A. (2020) Assessing the histological changes in fish gills as environmental bioindicators in Paraty and Sepetiba bays in Rio de Janeiro, Brazil. *Latin American Journal of Aquatic Research*, 48(4): 590-601.
- Kumar, M., Singh, S., Jain, A., Yadav, S., Dubey, A. & Trivedi, S.P. (2024) A review on heavy metal-induced toxicity in fishes: Bioaccumulation, antioxidant defense system, histopathological manifestations, and transcriptional profiling of genes. *Journal of Trace Elements in Medicine and Biology*, 83: 127377.
- Laurent, P. & Perry, SF. (1995) Morphological basis of acid–base and ionic regulation in fish. In: Heisler, N. (Ed), *Advances in comparative and environmental physiology. Mechanisms of systemic regulation: acid–base regulation ion transfer and metabolism*. Heidelberg: Springer, pp. 91-118.
- Marinović, Z., Miljanović, B., Urbányi, B. & Lujic, J. (2021) Gill histopathology as a biomarker for discriminating seasonal variations in water quality. *Applied Science*, 11: 9504.
- Minaz, M., Er, A., Kübra, A., Nane, İ.D., İpek, Z.Z. & Aslankoç, R. (2023) Bisphenol A used in plastic industry negatively affects wild *Vimba Bream (Vimba vimba)*. *Turkish Journal of Fisheries and Aquatic Sciences*, 23(8): TRJFAS22598.
- Romeis, B. (1989) *Mikroskopische technik*. München: Urban und Schwarzenberg, p. 697.
- Sihoka, C., Wagenaar, I., van Dyk, C. (2024) Metal bioaccumulation and histological alterations in *Oreochromis andersonii* at Itezhi-tezhi Dam downstream of a mining area in the Central Province of Zambia. *Environmental Toxicology and Pharmacology*, 107: 104394.