

MULTIPLE EXOSTOSES, INCLUDING AN EXOSTOSIS WITHIN THE SPINAL CANAL WITH SURGICAL AND NEUROLOGICAL OBSERVATIONS.

BY EDWARD H. OCHSNER, M.D.,

OF CHICAGO,

Attending Surgeon to the Augustana Hospital; Adjunct Professor of Clinical Surgery in the University of Illinois,

AND

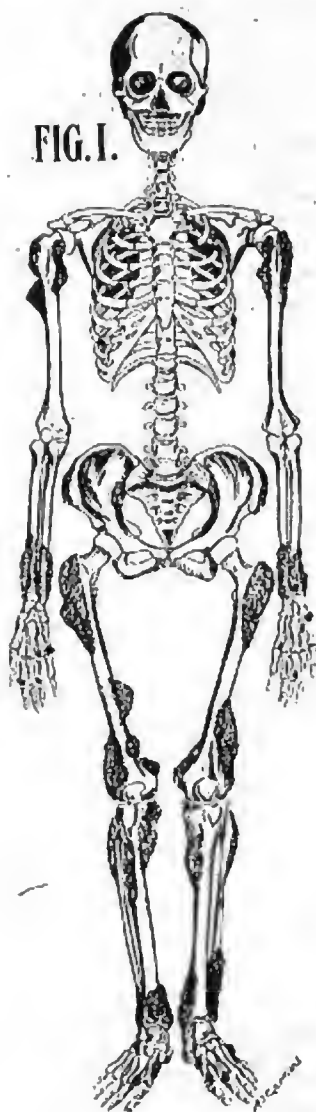
THOR. ROTHSTEIN, M.D.,

Assistant Professor of Medicine, in Rush Medical College.

EXOSTOSES of the human skeleton occur as chondroma, osteochondroma, and osteoma. They are not very common and fortunately those cases in which the exostoses cause marked disturbances are very rare. In the following case one of the exostoses caused serious trouble.

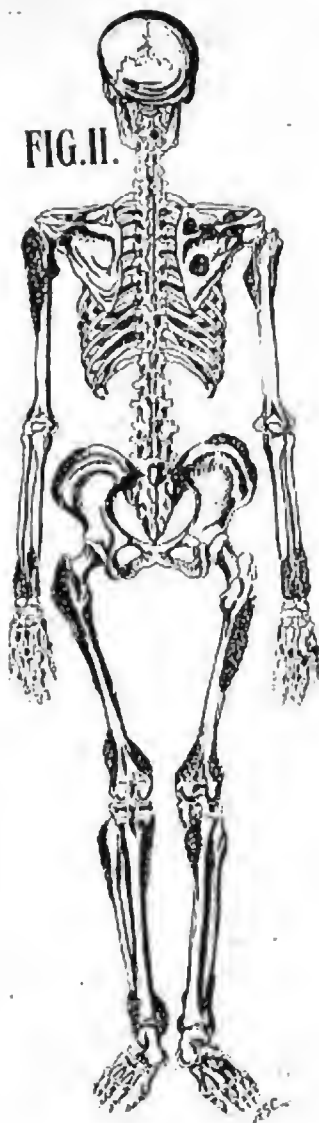
The patient, male, age twenty-three, was admitted to the Augustana Hospital October 8, 1906. No history of similar trouble among any of his relatives for several generations back. Father died at the age of forty with meningitis, probably tubercular, after an illness of several weeks. His father's left hand had been injured in a saw-mill several years before his death, causing ankylosis of all of the fingers of the left hand, the index and middle finger being held straight, the ring and little finger slightly flexed. There were also numerous bony irregularities on these fingers. During his last illness, while the mother was several months pregnant with the patient, the mother repeatedly stroked this irregular hand. Patient and patient's mother ascribe his exostoses to this prenatal influence, more especially as the patient habitually held his left hand in this same position during the first few years of his life, though the joints were never ankylosed. Except for these multiple exostoses patient has always been well.

At the age of fourteen first occasionally noticed slight incoördination of the lower extremities. When trying to move quickly and especially if tired, lower extremities would tremble



Anterior view of skeleton with multiple exostoses.

FIG. II.



Posterior view of skeleton with multiple exostoses.

and he could not place the feet exactly where he wished them to go. This became appreciably worse, especially in the right leg, and later appeared in the right arm. Since February, 1906, his right leg has dragged more than usual, his right hip seemed more stiff, and he had greater difficulty in walking. Since August, 1906, he has noticed that he has had less accurate control of his right arm and hand and that the tactile sense of his left arm and hand was somewhat impaired. From this time on the condition grew progressively worse, though there were intervals of slight remission, lasting sometimes for only a few hours at a time, so that by November 27, 1906, the patient was unable to walk at all even with crutches.

March, 1906, while pitching hay and straining considerably he had a feeling as of wrenching his neck, which caused pain on the right side of the body lasting about two hours. One month later he suddenly turned his head to the right and had a similar pain, plus a pricking sensation in the back and right side of body. After this every time he turned his head suddenly to the right this same pain would recur. Turning to the left caused no trouble. Since May, 1906, he never turned his head to the right; instead, when wishing to turn to the right, he would rotate the whole body. June, 1906, patient injured right knee, causing as he thinks a laceration of the ligaments.

On careful examination we found one-hundred-and-eight exostoses, as represented in Figs. 1 and 2. It is to be observed that there is one on the left superior curved line of the occipital bone. This is very unusual. In a rather careful study of the literature we were unable to find any reported case of an exostosis springing from the external surface of the bones of the roof of the cranium. It is supposed that the bones of the roof of the cranium are developed in membrane, hence are epiblastic in origin, while nearly all the remaining skeletal bones are developed from cartilage and are mesoblastic in origin. It has occurred to me that possibly there is this developmental reason for the fact that exostoses do not as a rule spring from the roof of the cranium, while they are found attached to practically any one of the other bones and it may be that in this case the tabular portion of the occipital bone

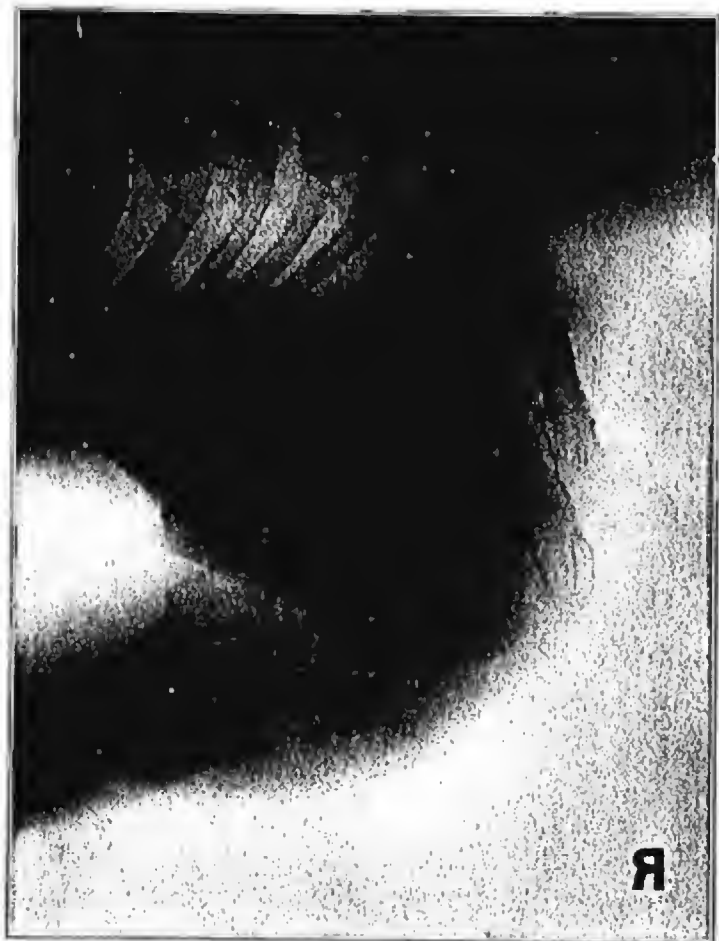developed from cartilage instead of developing in membrane and that this might account for the exostosis which we find here springing from the superior curved line of the occipital bone.

A very common location for exostoses is the ventral surface of the scapulæ, and in this case too we find a large exostosis on the ventral surface of the right scapula. The epiphyseal lines of the long bones and the insertion of tendons are also favorite seats for their development and in these two points our case conforms to the general rule. Their location and attachment to the various bones, as well as the density of the tumors is very clearly brought out by the skiagrams kindly furnished me by Dr. Reichmann, as represented by Figs. 3 & 4.

The question as to the age of development of these exostoses is still unsettled. In this patient the exostoses were first noticed at the age of two, and the patient thinks they continued to grow at about the same rate as the body and stopped growing with the body at the age of nineteen. This also is very doubtful, however, because it was not until after he was nineteen that the cord symptoms became at all pronounced, and my assistant, Dr. Abelman, who has observed this patient very carefully for the last four months is of the opinion that several of the exostoses, especially the one under the right scapula, have increased in size since the first examination. By some writers it is also claimed that these exostoses will occasionally spontaneously disappear in later life. In this case we have no evidence that any have either decreased or have disappeared.

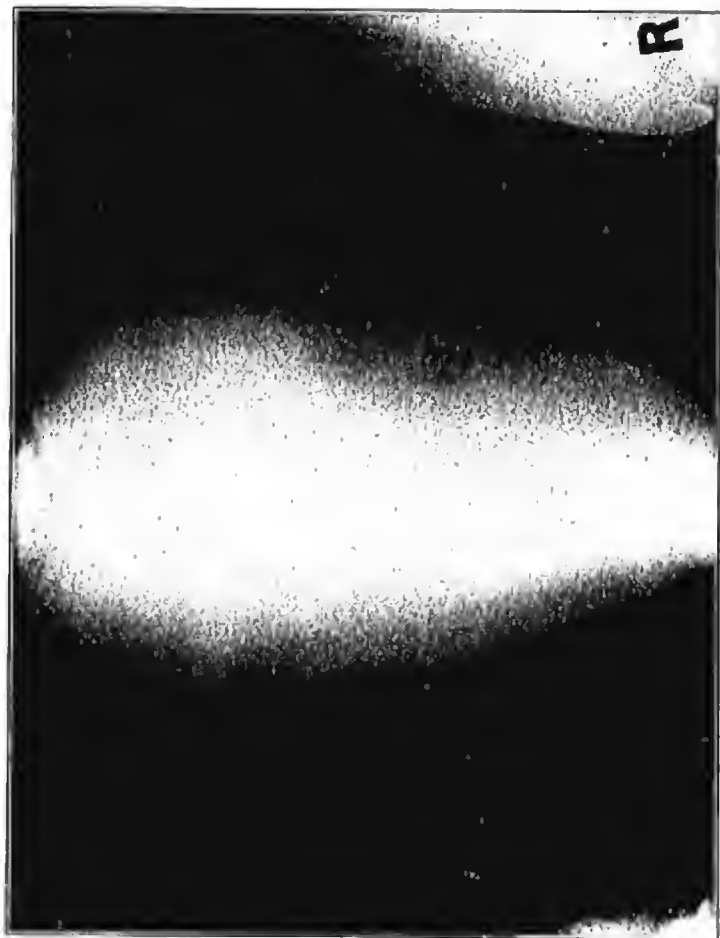
With the above history the question naturally arose as to how much of the disability was due to the rather severe injury to the right knee which the patient had sustained in June, 1906; whether or not there was some central nerve lesion, and if a central nerve lesion, was it an undiscovered exostosis making pressure upon the central nervous system, or was it a disease of the central nervous system itself. For solution of this question the patient was referred to the neurologist, Dr. Rothstein, whose findings of the nervous symptoms follow below, and who was

FIG. 3.



Skiergram of bones at shoulders affected by exostoses.

FIG. 4.



Skiagram showing femora.

able to make a rather definite diagnosis as to the location of the trouble. He referred the disturbance to the right half of the cord between the base of the skull and the upper border of the fifth cervical vertebra, probably opposite the second.

The patient was consequently anesthetized and the incision made in the median line extending from the external occipital protuberance to the sixth cervical vertebra, muscles and fascia separated from the vertebra, spinous processes and laminae of the second and third cervical vertebrae removed with bone forceps and attached by a small pedicle to the anterior surface of the right half of the second cervical vertebra. The tumor, represented by Fig. 5, was found within the dura pressing upon the cord and flattening it out considerably. The tumor proper was attached by the small pedicle to the lamina of the vertebra, the pedicle passing through a small hole of the dura, the tumor itself lying within the dura directly on the cord. When the tumor had been removed the cord appeared normal and bulged out. Fig. 5 represents the condition found as accurately as could be determined. The left lamina seemed to be more vertical than normal and shorter, while the right was longer than normal; the spinous process was consequently deflected a little to the left of the median line. Fig. 6 shows an average second cervical vertebra of normal size, while Fig. 5 represents a drawing based upon the normal in size, but modified in shape according to the conditions observed with the tumor drawn in its actual size.

It seems almost incredible that the cord could have sustained so much pressure for so long a time and not have suffered more. The dura had to be incised in order to get the tumor out, and no attempt was made to suture it. A small gutta percha drain was introduced down to the cord, the wound closed, and a large antiseptic dressing applied.

All of the operating on the vertebrae was done with the greatest care, and the tumor removed as gently as possible, and yet, on regaining consciousness, the patient complained of numbness of the whole body and was unable to move any of his extremities, anal sphincters were completely relaxed, the bladder was paralyzed. Five hours after leaving operating table slight motion in left arm and leg, but none in right; sphincters still relaxed, bladder still paralyzed. Eighteen hours after leaving operating table complete loss of sensation of left upper extremity,

impairment of sensation in remaining extremities, motion of left arm and leg fair, except that left arm was ataxic, muscle sense being completely lost, right arm and leg, right half of diaphragm and right intercostal muscles completely paralyzed. About two weeks after operation, motion began to return on the right half of the body, and since this time sensation and motion have slowly but gradually improved, and now three months after the operation he is greatly improved. He is now able to move his neck in every direction without the slightest pain and he is able to walk very comfortably with crutches, though he still suffers considerably from ataxia. His exact status is also given below by Dr. Rothstein.

It is only occasionally that operative intervention is required in cases suffering from multiple exostoses, because fortunately these tumors are usually located where they do not cause any great harm or inconvenience. Some of the indications for operation are excessive weight of the tumors, or their location in places where they cause pressure sores, interference in the mobility of joints, pressure upon nerve trunks with their resultant neuralgias and pressure upon important organs as in the case above given in detail.

Some years ago I saw a case in which it was necessary to remove an exostosis from the upper end of the radius because it caused interference with the rotary motion of the forearm. Recently I have had to remove a multiple exostosis of the lower end of the radius for the same reason. These three cases are the only cases of exostosis that I have ever seen where operative interference seemed indicated.

NEUROLOGICAL OBSERVATIONS.

When I first saw the patient he presented the picture of a spastic paresis, more marked on the right than on the left side. He was able to walk but little on account of the stiffness in his legs. After a few steps his legs, especially the right one, would come into a state of trembling, making it impossible for him to walk. The trembling once started would persist for some time, but would gradually subside during rest. Active movements

FIG. 5.



Exostoses springing from one of the lamina of axis and growing into the spinal canal.

FIG. 6.



Normal axis, to compare with diseased axis shown in fig. 5.

would cause trembling also in the arms, intense in the right arm, slight in the left. His right arm was contracted, being held in adduction and flexed to right angle in the elbow joint, and the hand was halfway closed. He was able to execute actively only very slight movements in the shoulder joint, and in the elbow joint flexion and extension of about ten degrees. The fingers could only be slightly extended and flexed, the hand being completely useless. With the right leg he could execute active movements more freely, but all the movements were weak and much limited in comparison to the normal.

Passive movements in any joint of upper or lower right extremity would meet with intense resistance. The left arm and left leg were weak, but could be freely moved actively. Passive movements would meet with some resistance.

The tendon reflexes of all four extremities were increased. Wrist and patellar clonus existing on right side, foot clonus on both sides, a strong Babinsky reflex on right and a slight but distinct Babinsky reflex on the left side.

The cutaneous reflexes were lively.

The only disturbances of the sensibility possible to demonstrate were a slight ataxia in left arm and leg and inability to recognize objects with his left hand when his eyes were closed.

His tongue was slightly asymmetrical, the left half being somewhat smaller than the right, and when the tongue was protruded it would sometimes deviate to the left.

The fundi of the eyes were normal, but a distinct nystagmus could be observed when the eyes were moved to the extreme left or right.

He had perfect control of the sphincters.

The above described symptoms might suggest the diagnosis of a disseminated sclerosis, or some other kind of sclerotic process in the central nervous system.

The patient presented, however, a symptom which directly pointed to the existence of an exostosis in the spinal canal. As Dr. Ochsner already has mentioned, the patient sometimes felt a sharp pain shooting through his whole body when he turned his head to the right. This pain occurred only when he turned his head suddenly to the extreme right. Sometimes it happened that at the same time as the pain was felt in his whole right side from the neck down to the toe, he also felt a pain shooting upward in

the back of his head on the right side. When he, immediately after such an intentionally produced pain, outlined the course of the pain in the back of the head, it was found that the pain followed the course of *nervus occipitalis minor* on the right side. As *nervus occipitalis minor* gets its fibres from the second and third cervical root (that is, the nerves which leave the spinal canal, the one immediately above and the other immediately below the second cervical vertebra), the mentioned symptom pointed towards the second cervical vertebra as being the seat of the tumor. By examination of the shoulder muscles it was found that the *musculi rhomboidci* and *musculi levator anguli scapulæ* on the right side were much weaker than the corresponding muscles on the left side, and percussion of the *trigonum scapulæ* would cause much more lively contractions in *rhomboidci* and *levator anguli scapulæ* on the right side than on the left. As the new fibres which supply *musculi levator scapulæ* do not leave the spinal cord lower down than the fifth segments (corresponding to the level of fourth cervical vertebra), it was clear that if the spastic process was due to anosteomia this must sit on the fourth cervical vertebra or higher up.

On account of the mentioned pain along the *nervus occipitalis minor* it was, however, considered that the supposed tumor most likely would be found on the second cervical vertebra. The motor symptoms being so much more pronounced on the right side, it was necessary to assume that the tumor pressed upon the right side of the cord, but there one would expect some of the symptoms usually present in a half-sided lesion of the cord. A slight suggestion of such a lesion gave the ataxia of the left extremities and the sensory disturbances of the left hand. The nystagmus and asymmetry of the tongue might be explained either as congenital or as symptoms of intrinsic affection of central nervous system.

A week after the operation the patient presented a typical picture of half-sided lesion of the cord, with loss of all the different qualities of sensation, including muscle-sense, on the left side, with hyperæsthesia and flaccid motor paralysis on the right side. He gradually improved, and three months after the operation his condition was the following: Active motility of left upper and lower extremity normal; no stiffness on passive movements. Right arm can be adducted from the body and lifted up to 135°.

and rotation is nearly normal. Full flexion and extension are possible in the elbow joint, but by extreme extension motion becomes a little slow.

Pronation and supination are of less than normal degree. Flexion and extension of right wrist joint 40° . The thumb can only be slightly extended and flexed. The right index finger can be fully extended and flexed, but the other three fingers cannot be extended fully, especially not the little finger. He can spread and adduct the fingers to some degree. The grip of the right hand is weak, but has increased considerably in strength. By passive movements some resistance is felt, but the stiffness is easily overcome.

The passive and active movements in the ankle and toes are nearly normal, some resistance existing in the ankle joint by passive movements. The movements of left knee and hip joint could not be examined on account of a plaster cast having been put on the leg.

The patella-reflex on left side somewhat decreased. On left side no ankle clonus is present and only a slight amount on right side. A slight Babinsky reflex can be elicited on left and also on right side.

The tendon reflexes of right arm seem about normal. The abdominal reflexes are more lively on left than on right side.

Sensation for touch-, temperature-, pain-, and muscle-sense were normal on right side. On the left side a slight stroke with cotton would not be felt over dorsal aspect of the two extreme phalanges of all the fingers, neither would it be felt over dorsal aspect of foot and toe. If the pressure of the cotton was made a little heavier, the touch would, however, be felt. The patient stated himself that although he felt the slight touches of cotton over the rest of the left side he did not feel the touch nearly as clearly on the left as on the right side.

Sensation for pain was decidedly decreased over the whole left side, with exception of the area supplied by nervous trigeminus.

All passive movements in any joint on left side he would perceive and judge nearly correctly, but by active movements a marked ataxia was apparent in the hand. An object, knife, coin, etc., put in his left hand (when his eyes were closed) would not be identified and invariably dropped.

Sensation for temperature was decidedly diminished on the left side.

The nystagmus seems to be less marked than before the operation.

The patient returned to the hospital and was examined again May 30, 1907.

He is considerably improved. He is able to use his right hand to some extent, to dress himself and button his clothes, which was impossible for him in the month of March. He walks now without crutches, but his right arm is carried somewhat stiffly, usually flexed in the elbow joint. The right leg is still in a cast. The right arm can now be stretched straight upward, and can be fully extended and flexed in the elbow joint, although the last part of the extension is still a little slow.

Flexion and extension in wrist joint to 45° and 50° . Fingers can be fully extended and flexed except thumb and little finger. Grip of right hand has gained considerable in strength, but is still much weaker than grip of the left hand.

Passive movements in all joints of right extremities meet with some resistance, especially if the movements are done suddenly.

Marked Babinsky reflex. Foot and patellar clonus exist on right side.

The tendon reflexes of right arm increased.

On the left side stroking of the foot sole causes flexion of the big toe and the patellar reflex is lively. Abdominal and cremaster reflex much livelier on left than right side. Feels slight stroke of cotton over whole left side, but sensation a little uncertain over dorsal aspect of the foot and toes. Sensation for pain has improved, but needle is still felt less sharp on left than on right side. His ataxia is also considerably less than in the month of March. Objects put in his left hand are usually not recognized, but they are felt and not dropped.

The reflexes which after the operation became decreased have later gradually increased, such as the left patellar reflex, the foot clonus on the right and the tendon reflexes of the right arm. But the Babinsky reflex on left foot disappeared, and the sensibility and mobility have in the same time improved.

The nystagmus is markedly less than before the operation.