

A NEW INTESTINAL PARASITE OF MAN: PARAMOEBA HOMINIS.

BY CHARLES F. CRAIG, M.D.,

FIRST LIEUTENANT, ASSISTANT SURGEON, U. S. ARMY; PATHOLOGIST AND BACTERIOLOGIST
TO THE U. S. ARMY DIVISION HOSPITAL, MANILA, P. I.

SINCE the brilliant investigations of Schaudinn¹ upon the morphology and method of reproduction of the amœbæ inhabiting the intestine of man were published, in which he demonstrated the existence of at least two species, one harmless and the other pathogenic, the study of these organisms has acquired new interest and importance. In a previous contribution² I have described in detail the results of personal work upon *Entamœba coli* and *Entamœba dysenteriae* (*histolytica*), all of which were confirmatory of Schaudinn's conclusions, and have since been so fortunate, during several months' work in the Philippine Islands, as to be able to study the peculiar amœba which will be described, and which, not only because it is a hitherto undescribed species for man, but on account of its complicated life cycle is of the greatest interest. This parasite is of rare occurrence, as I have observed it in but six cases out of several hundred patients whose feces I have examined. I have only observed it in natives of these Islands, although I have looked very carefully for it in American soldiers and civilians, some of whom have lived for a considerable period of time in the tropics.

OCCURRENCE. This amœba was observed in the feces of six natives who were patients in the hospital at the time the examinations were made. In five of the cases the only symptoms of importance present was a diarrhœa, the stools being of watery consistence, and containing in three of the cases a small amount of blood and mucus. In none of these cases was *Entamœba dysenteriae* present. The sixth patient was suffering from a very severe attack of acute amœbic dysentery, and the new amœba was found in small numbers in conjunction with immense numbers of *Entamœba dysenteriae* (*histolytica*). In one case *Trichomonas intestinalis* was present.

MORPHOLOGY AND LIFE CYCLE. Before describing the morphology of this parasite it will be necessary to sketch briefly its life cycle, for at different periods in the latter the morphology varies very greatly. This amœba, unlike any other hitherto described as infecting man, undergoes a flagellate and an amœboid stage of development, resembling in this the water amœba first described by Schaudinn and named by him *Paramœba eilhardi*. I have been able, by making repeated examinations, to trace the life cycle of this

¹ Arbeiten aus dem Kaiserlichen Gesundheitsamte, 1903, xix. Heft 3, p. 563.

² American Medicine, May 27, June 3 and 10, 1905, vol. ix., Nos. 21, 22, and 23, pp. 854-861, 897-903, 936-942.

amœba in the intestinal contents, and while there are many points in connection with this cycle which require further study, especially as regards the intervals of time which elapse between the various stages of growth, enough has been observed to enable us definitely to place this organism in the same genus with *Paramœba eilhardi*.

LIFE CYCLE. The new amœba, as I have stated, is a flagellated organism during one stage of its growth, this stage being succeeded by a stage in which the true amœba form is observed. In both these developmental stages reproduction is probably possible, although I have observed it only in the amœboid stage; in this stage reproduction by simple division can be demonstrated (Fig. 1).

FIG. 1

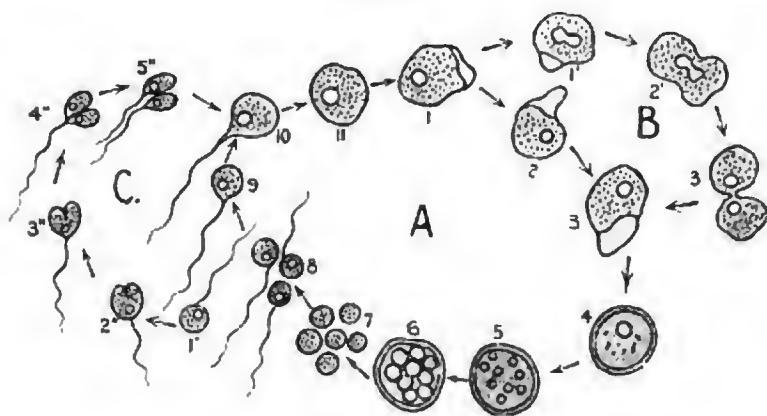


Diagram illustrating the life cycle of *Paramœba hominis*: A, 1 to 11. The entire life cycle, showing the amœba and flagellate stages, which has been observed. B, 1 to 3. Cycle of reproduction by simple division, which has been observed. C, 1 to 3. Cycle of reproduction, by longitudinal division of the flagellates, which is hypothetical.

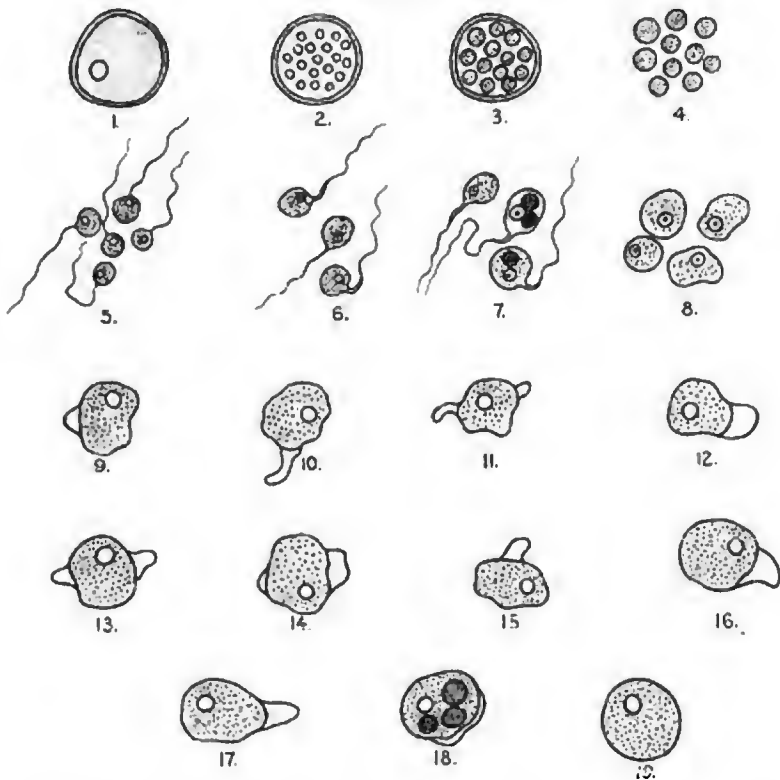
Beginning with the amœboid stage, after the organism has reproduced an unknown period of time by simple division, the amœbæ become circular in shape and there is developed a refractive, hyaline, double outlined cyst wall. Within the cyst so formed a number of small spherical bodies are produced, which are liberated by the rupture of the cyst, and which possess a long, delicate flagellum, and are actively motile. The flagellated organisms increase rapidly in size and eventually become motionless, lose their flagella, and develop into the true amœboid form, after which they undergo reproduction by simple division for a period, and then become encysted, as has been described. Whether the flagellate form reproduces as such, as does *Paramœba eilhardi*, I have not been able to determine.

MORPHOLOGY. Having thus briefly outlined the life cycle of this organism, the morphology as observed in its various stages of

development may be considered, beginning with the amoebic form at the time of encystment (Fig. 2).

Encysted Stage. At this time the parasite measures from 15 to 20 μ in diameter, and is circular in shape. It appears opaque and

FIG. 2



Various forms of the flagellate, cystic, and amoebic stages in the growth of *Paramoeba hominis*: 1, newly formed cyst, showing membrane and nucleus; 2, cyst showing absence of nucleus and a large number of small refractive dots; 3, cystic form, presenting within the cyst numerous young flagellates; 4, young parasites after liberation from the cyst and before the development of the flagellum; 5, young flagellates after the appearance of the flagellum; 6, older flagellate forms of *Paramoeba hominis*; 7, fully grown flagellate form of *Paramoeba hominis* (note the well-defined nucleus, the differentiation of the ectoplasm and endoplasm, the blunt pseudopodia, and the granular appearance); 8, flagellate forms immediately after the disappearance of the flagellum and before the appearance of amoeboid motion; 9 to 18, various forms of the amoebic stage of *Paramoeba hominis* (note the well-defined nucleus, the differentiation of the ectoplasm and endoplasm, the blunt pseudopodia, and the granular appearance); in 18 the amoeba contains three red blood corpuscles; 19, *Paramoeba hominis* at the termination of its amoebic stage, just previous to encystment.

is of a dull-gray color; no difference can be detected between the ectoplasm and endoplasm, the protoplasm appearing homogeneous; surrounding the organism is a delicate, very refractive capsule, having a double outline. In the earliest stage of encystment a nucleus,

spherical in shape and very small, is generally observed, situated a little to one side of the centre, but this nucleus entirely disappears at a later stage, being replaced by numerous brightly refractive dots which are scattered throughout the protoplasm. In some instances a smaller, oval body may be seen situated a little to one side of the nucleus; this is not so refractive. At a later stage the cyst appears to be crowded with small circular bodies which are undoubtedly the young flagellate organisms. The appearances described are those presented in fresh specimens. I have not been able as yet to stain the cystic forms successfully.

Young Flagellate Stage. While I have not been able to observe the actual rupture of the cyst wall, and the liberation of the young flagellated organisms, in all the cases observed I have found groups of such organisms, lying apparently in cellular detritus, and arranged in circular masses, corresponding in size to the original cyst, although the cyst wall had disappeared. At first these young organisms do not appear flagellated, are very small, measuring from 3μ to 5μ in diameter, are circular in shape, and have a finely granular protoplasm in which no nucleus can be demonstrated. After watching these young amoebæ for a while it will be seen that one by one they become motile, a very delicate flagellum appearing at some portion of the periphery; they disengage themselves from the material in which they seem embedded, and move forward in a rapid, jerky way, propelled by the flagellum, which thus appears to be situated posteriorly. It is impossible to stain these young forms distinctively.

Fully Grown Flagellate Stage. The young flagellate forms increase very appreciably in size, and in all the specimens which I have examined, the intermediate stages in the growth could be easily traced, but as the morphology varies but little until the flagellate form has attained its full growth, it is unnecessary to give it in detail.

When fully grown the flagellate forms measure from 10μ to 15μ in diameter and are perfectly circular in shape, save at that portion of the periphery where the flagellum is attached. The latter is three to four times as long as the diameter of the parasite, and tapers very rapidly, the outer three-fourths being so extremely slender that it requires very careful focusing to demonstrate it. At the point of attachment to the body of the parasite the flagellum is continuous with the protoplasm, and the nucleus appears to be situated, in the majority of instances, near this point. The flagellum is situated posteriorly, and the organism moves forward rapidly, propelled by the flagellum, the motion of the latter being lashing in character. The protoplasm is homogeneous in greater part, but small refractive granules are often observed, and a small spherical nucleus, having a well-marked nuclear membrane, is usually present. I have several times observed from one to two red blood corpuscles within

the flagellate form, so that it is apparent that the property of engulfing these cells is not confined to the amœboid stage. As stated I have not been able to observe reproduction in this stage. Stained preparations, even when Wright's stain is employed, are not satisfactory, the organism staining a very dark purple color throughout, and the flagellum does not take the stain.

Young Amœbic Stage. Repeated observations of these fully grown flagellate forms demonstrate that after gradually becoming less motile, progressive motion is lost, and that after lashing around with the flagellum for a while, this also becomes motionless, and disappears, being either drawn within the body of the parasite or degenerating. With the disappearance of the flagellum, amœboid motion commences, appearing at first as an undulatory motion of the border of the parasite, followed by the projection of small, rather pointed pseudopodia. At first there is no progressive motion, the pseudopodia being projected and withdrawn rapidly, but they gradually increase in size and progressive motion begins; the motion is fairly rapid for an amœba, the pseudopodia being bluntly conical in shape, and as soon as they are projected the endoplasm flows rapidly into them. There is a distinct difference in the appearance of the ectoplasm and the endoplasm, the latter being more refractive than the former and much larger in amount. When the organism is motionless the ectoplasm and the endoplasm cannot be differentiated. A nucleus is present, refractive, spherical in form, and presenting a well-defined nuclear membrane. It is always situated in the endoplasm, and changes its position with the movements of the organism. Vacuoles have not been observed. One to two red blood corpuscles are occasionally seen in these young amœbæ. The endoplasm is finely granular in structure.

Fully Grown Amœbic Stage. After becoming amœboid, the parasite increases considerably in size, measuring when fully grown from $15\ \mu$ to $25\ \mu$ in diameter; the distinction between the ectoplasm and the endoplasm is well-marked when the organism is moving, but invisible when it is motionless; the nucleus is distinct and presents a heavy nuclear membrane; no vacuoles are present, but the endoplasm contains a great deal of granular material and often from one to four red blood corpuscles. When fully grown the motility is very marked and is progressive in character.

In stained specimens no difference can be detected in the staining reactions of the ectoplasm and the endoplasm, but the nucleus stains a brilliant red with Wright's stain, and appears to be composed almost entirely of chromatin.

Precystic Stage. In the amœboid stage I have repeatedly observed reproduction by simple division, but in the same specimen of feces numerous amœboid forms will be observed which are becoming encysted, as well as those in which the process is complete. The manner in which this organism becomes encysted is very interesting.

The amœboid motion gradually ceases and suddenly the organism begins to rotate very rapidly upon its axis, this rotation sometimes lasting for an hour or more.

It is probable that it is during this process of rotation that the cyst wall is formed, for when rotation ceases it is observed that the organism is surrounded by the delicate, double-outlined membrane which has already been described. After rotation has ceased the organism appears slightly smaller than while in the amœboid stage, and the nucleus is shrunken and in some instances is not distinguishable.

CLASSIFICATION. It is evident that the parasite described passes through an amœbic and a flagellate stage of development, and for this reason it cannot be placed in the genus *Entamœba*. The organism might be regarded as a connecting link between the amœbæ proper and the flagellates, but as Schaudinn has already described a very similar organism, occurring in water, and has placed it in the genus *Paramœba*, I am of the opinion that this new amœba of man should be placed in the same genus. While I have not been able to demonstrate reproduction by longitudinal division during the flagellate stage of growth, which occurs in *Paramœba eilharði*, it is very probable that such a mode of reproduction occurs, for the other developmental stages of the new parasite are identical with those of *Paramœba eilharði*.

For these reasons I believe that this organism may be properly placed in the genus *Paramœba* described by Schaudinn, and would suggest that the name *Paramœba hominis* be given this new intestinal parasite of man.

PATHOGENICITY. As to whether *Paramœba hominis* produces any pathological condition of the intestine, or whether it is a harmless amœba, as is *Entamœba coli*, I am not prepared to say. In all the cases but one in which it was observed its presence was accompanied by the usual symptoms of a severe diarrhœa, and it was the only animal organism present which could be looked upon as being of any etiological significance. In the one case it occurred in conjunction with *Entamœba dysenteriae*, and, therefore, it is impossible to say what part *Paramœba hominis* played in the infection.

DIFFERENTIAL DIAGNOSIS. There is but one intestinal parasite which might be mistaken for *Paramœba hominis*, because of certain peculiarities in its development. I refer to *Trichomonas intestinalis*. The latter organism is often observed in the resting stage, when it is circular in form, and appears to possess very limited amœboid motility. It is much smaller than *Paramœba hominis* at the beginning of the amœboid stage, and it does not possess active progressive amœboid motion, as does the latter. In the flagellate stage *Paramœba hominis* is distinguished from the trichomonads by the absence of the undulating membrane and the presence of one flagellum, as well as by its circular shape. It is impossible to confuse it with

the cercomonads, as it does not resemble these organisms in the least. It would be somewhat difficult for one who has not traced the development of *Paramoeba hominis* to distinguish its amoebic stage from that of *Entamoeba coli*, but the presence in the same specimen of cystic forms, rotating forms, and various stages of the flagellate form makes the diagnosis of *Paramoeba hominis* easy. In conclusion, I would call attention to the fact that this parasite has been found only in natives of the Philippine Islands, but that in all probability further research will show that it is much more frequently present than appears to be the case at present.

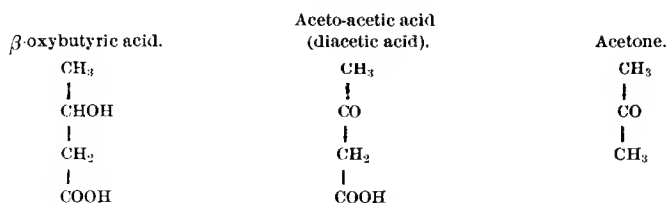
THE ACETONE BODIES: THEIR OCCURRENCE AND SIGNIFICANCE IN DIABETES AND OTHER CONDITIONS.

By T. STUART HART, A.M., M.D.,

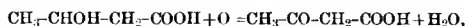
INSTRUCTOR IN PHYSICAL DIAGNOSIS, COLUMBIA UNIVERSITY; VISITING PHYSICIAN TO THE
SETON HOSPITAL, NEW YORK.

As our knowledge of the so-called acetone bodies, that is, acetone, diacetic acid, and β -oxybutyric acid, increases they assume a growing importance and interest in their connection with many pathological conditions. As symptoms of disordered metabolism they are of significant value. Their presence in diabetes and febrile conditions has been recognized for a considerable time. Their more recent discovery in operative procedures, pregnancy, digestive disturbances, nervous disorders, malignant disease, and various forms of poisoning has made them of interest to an ever-increasing number of the medical profession.

The graphic formulae of the acetone bodies at once indicates to us their close relationship.



By oxidizing β -oxybutyric acid we obtain diacetic acid:



and when diacetic acid is heated to 100° C. it is easily decomposed into acetone and carbonic acid:

