

RESULTS OF MAMMOGRAPHIC SCREENING FOR INTRADUCTAL BREAST FORMATIONS

F.M. Djalolova

Department of Oncology, Andijan State Medical Institute

<https://doi.org/10.5281/zenodo.17674596>

Abstract. *Intraductal carcinoma, or ductal carcinoma in situ (DCIS), is the preinvasive form of breast carcinoma. In most instances, it is clinically inapparent and is discovered incidentally during histologic examination of breast tissue identified as abnormal by mammography.*

Keywords: *ductal carcinoma in situ (DCIS), breast carcinoma, clinic and screening mammographic studie, calcifications.*

Introduction

Currently, one of the most pressing problems not only in oncology but also in healthcare in general is the prevention of breast cancer (BC), which is due to the rapid, steady and widespread growth in the incidence of this form of cancer, which has taken first place in the structure of morbidity in women with malignant neoplasms (Bluekens AM et al 2012). This is due to the leading position of this tumor in women, outpacing other malignant neoplasms in frequency of occurrence (Bray F et al 2018). Despite a large number of studies devoted to improving the methods of diagnosis and treatment of BC, the results are far from always satisfactory.

Mammographic screening has reduced breast cancer-related mortality by 30% (Tagliafico AS et al, 2016). However, the sensitivity of mammography is about 70%, especially in women with dense breast tissue (Pisano ED et al, 2005). Current recommendations of the Society of Breast Imaging, the American College of Radiology, and the National Comprehensive Cancer Network require annual mammographic screening, starting at age 40 and older in cases of average oncological risk. For women with a high risk of breast cancer (more than 20% during life), MRI is recommended in addition to mammography (Riedl CC et al, 2015).

For women with a BRCA1/2 gene mutation, with TP53 Li Fraumeni syndrome, or who received radiation therapy to the chest area before age 30, annual mammography and, possibly, MRI are recommended from the moment of identification. In the USA, women with dense breast tissue are warned about the advisability of additional screening (mammography + ultrasound / MRI) (Tagliafico AS et al, 2016). If calcification is detected during screening mammography, image magnification is recommended to determine the extent of the lesion. If calcification is associated with structural asymmetry of the mammary gland or the presence of a mass, additional examination using ultrasound is required to diagnose invasion.

To improve the primary screening of DCIS, it is recommended to conduct studies comparing the diagnostic efficiency of ultrasound and radiological methods of population screening. There is insufficient literature data on such a comparison today, which does not allow developing a single effective and adequate strategy for the preventive diagnosis of breast tumors.

MATERIALS AND METHODS OF RESEARCH

As women, a total of 144 patients, 77 of them had pain in the mammary glands of various ages, for the period from 2017 to 2022, were included, palpation of the mammary gland derivative,

and pathological discharge from the nipple without the presence of hyperprolactinemia. 67 women aged 40 and older, mammography revealed mammary masses, and no subjective symptoms indicative of mammary gland pathology were included. The methods of clinic and screening mammographic studies.

RESULTS

During mammographic screening in women who were subsequently diagnosed with an intraductal formation, in 120 cases out of 144, a focal shadow was found that was suspicious of the formation of breast cancer. Thus, the sensitivity of standard mammography to intraductal formation was 83.33%, which is significantly higher than the sensitivity of clinical screening ($X^2=29.72$, $p<0.001$). Moreover, the sensitivity of mammography was comparable both among the glands with a malignant neoplasm and with a benign one (80.77% and 83.90%, respectively, $\chi^2=0.15$, nd). Since the criterion for inclusion in the statistical analysis of the study was the presence of a verified intraductal formation, the specificity of the method was not evaluated. Comparison of the results of detection of intraductal neoplasms on the basis of mammography and on the basis of clinical signs revealed a significant weak relationship between these diagnostic approaches: the correlation coefficient was +0.42 for all cases ($p<0.01$), +0.39 for malignant neoplasms ($p<0.05$) and +0.42 for benign neoplasms ($p<0.01$).

Among all cases of intraductal formations diagnosed in the course of this study, only 37% of cases showed the presence of clinical symptoms of the formation and mammographic signs. In 46% of cases, screening mammography revealed the formation against the background of a "silent" clinical course, which accounted for 55.83% of all mammographically "positive" cases. In 17% of cases, patients showed clinical signs of cancer without mammographic confirmation, which accounted for 31.17% of all clinically "positive" cases (Fig.1).

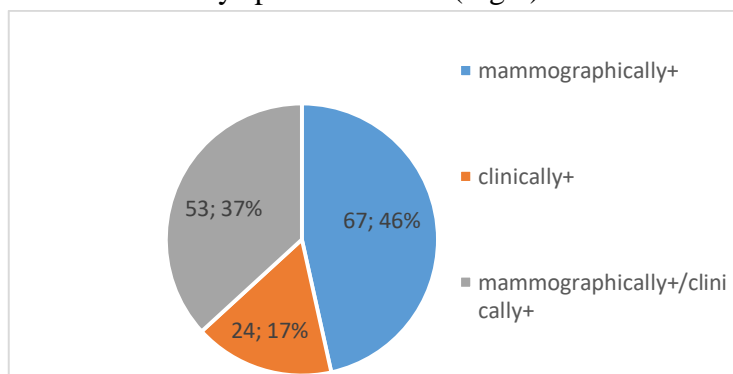


Fig-1 The frequency of occurrence of mammographically and clinically "positive" and "negative" cases of intraductal formations/

The frequency of occurrence of mammographically and clinically "positive" cases of intraductal formations in the groups with malignant and benign pathology did not differ (Table-1).

Table 1.

Criteria	Breast cancer criterion (n=26)	Benign pathology (n=118)
Mammography+ (n=67)	10 (38,46%)	57 (48,31%)
Clinic+ (n=24)	5 (19,23%)	19 (16,10%)
Mammography+ / clinic+ (n=53)	11 (42,31%)	42 (35,59%)
X2	0.83 nd	

Frequency of occurrence of mammographically and clinically "positive" intraductal breast formations, depending on the presence of malignancy (relative percentage in the group is shown in parentheses)

Calcinates are one of the important mammographic findings associated with intraductal formations. This phenomenon was found on 77 mammographic images (53.47% of all mammograms performed), while the presence of calcifications was more characteristic of malignancies (19 cases out of 26) compared to benign pathologies (58 cases out of 118): 73.08% and 49.15%, respectively ($X^2=4.90$, $p<0.05$). Differentiation of calcifications by character into linear and lumpy. Showed that linear shadows of calcifications are associated with intra-ductal breast cancer (61.54% against 26.92% of lumpy formations), while in the case of benign pathology, lumpy calcifications are more often detected (50.85% against 19.49% of linear calcifications, X^2 between breast cancer groups and benign pathology=19.18, $p<0.001$).

Thus, the analysis showed that the sensitivity of mammography in the aspect of detecting intraductal formations is 83.33%. In the aspect of differentiated detection of malignancy, informative mammographic signs turned out to be deformity of the X-ray pattern and detection of linear calcifications. The remaining mammographic characteristics did not differ in the case of malignant and benign pathology.

The sensitivity of such a mammographic sign as pattern deformity in the aspect of detecting intraductal breast cancer is 42.31% (11 out of 26), specificity is 85.59% (101 out of 118), and diagnostic value is 77.78% (112 out 144). The relative risk of detecting intraductal malignancy in patients with mammographic pattern deformity is 3.04 (absolute risk of intraductal breast cancer in patients with pattern deformity is 39.29%: 11 out of 28, in patients without pattern deformity-12.93%: 15 out of 116, $X^2=9.97$, $p<0.01$).

The sensitivity of calcification detection to the risk of ductal breast cancer is 73.08% (19 out of 26), the specificity is 50.85% (60 out of 118), and the diagnostic effectiveness is 54.86% (79 out of 144). The risk of ductal breast cancer in patients with breast calcifications diagnosed by mammography is 24.68% (19 out of 77), in the absence of calcifications-10.45% (7 out of 67, chi square=4.99, $p<0.05$), so the relative risk of breast cancer in the gland with mammographically detectable calcifications is 2.36.

Detection of linear calcifications (39 cases out of 144) is characterized by sensitivity of 61.54% (16 out of 26), specificity-80.51% (95 out of 118), diagnostic significance – 77.08% (111 out of 144). The risk of ductal breast cancer in the case of linear calcifications detected during screening mammography is 41.03% (16 out of 39), without linear calcifications-9.52% (10 out of 105, $X^2=18.51$, $p<0.001$), the relative risk of ductal breast cancer in the case of linear calcifications is 4.31. Thus, the detection of linear calcifications in the aspect of diagnosing ductal breast cancer, compared with the detection of calcifications of any form, is associated with an increase in specificity with a decrease in sensitivity.

CONCLUSION

1. The sensitivity of clinical physical screening for intraductal breast formations is 53.47%, the sensitivity of mammographic screening is 83.33%.

3. Mammographic markers of malignancy of an intraductal formations are deformation of the breast pattern (RR = 3.04, $p < 0.01$), the presence of calcifications (RR = 2.36, $p < 0.05$), in particular linear calcifications (RR = 4.31, $p < 0.001$).

REFERENCES

1. Bluekens AM, Holland R, Karssemeijer N, Broeders MJ, den Heeten GJ. Comparison of digital screening mammography and screen-film mammography in the early detection of clinically relevant cancers: a multicenter study. *Radiology*. 2012;
2. Bray F, Ferlay J and Soerjomataram I, et al. Global cancer statistics 2018;
3. Tagliafico AS, Calabrese M, Mariscotti G, Durando M, Tosto S, Monetti F, et al. Adjunct screening with tomosynthesis or ultrasound in women with mammography-negative dense breasts: interim report of a prospective comparative trial. *J Clin Oncol*. 2016;
4. Pisano ED, Gatsonis C, Hendrick E, Yaffe M, Baum JK, Acharyya S, et al. Diagnostic performance of digital versus film mammography for breast-cancer screening. *N Engl J Med*. 2005;
5. Riedl CC, Luft N, Bernhart C, Weber M, Bernathova M, Tea MK, et al. Triple-modality screening trial for familial breast cancer underlines the importance of magnetic resonance imaging and questions the role of mammography and ultrasound regardless of patient mutation status, age, and breast density. *J Clin Oncol*. 2015;
6. Tagliafico AS, Calabrese M, Mariscotti G, Durando M, Tosto S, Monetti F, et al. Adjunct screening with tomosynthesis or ultrasound in women with mammography-negative dense breasts: interim report of a prospective comparative trial. *J Clin Oncol*. 2016.