

|   |  |   |
|---|--|---|
|  <p>ISSN NO. 2320-5407</p> | <p>Journal Homepage: -<a href="http://www.journalijar.com">www.journalijar.com</a></p> <p><b>INTERNATIONAL JOURNAL OF<br/>ADVANCED RESEARCH (IJAR)</b></p> <p>Article DOI:10.21474/IJAR01/21325<br/>DOI URL: <a href="http://dx.doi.org/10.21474/IJAR01/21325">http://dx.doi.org/10.21474/IJAR01/21325</a></p> |  <p>INTERNATIONAL JOURNAL OF<br/>ADVANCED RESEARCH (IJAR)<br/>ISSN 2320-5407<br/>Journal Homepage: <a href="http://www.journalijar.com">http://www.journalijar.com</a><br/>Article DOI:10.21474/IJAR01/21325</p> |
|---|--|---|

### RESEARCH ARTICLE

## GLANDULAR ODONTOGENIC CYST OF MANDIBLE: A RARE ENTITY REVEALED

Paramjit Kajla<sup>1</sup>, Rachana Galinde<sup>2</sup> and Sahil Prashar<sup>2</sup>

1. Assistant Professor, Department of Oral and Maxillofacial Surgery, Punjab Government Dental College and Hospital, Amritsar, Punjab, India.
2. Junior Resident, Department of Oral and Maxillofacial Surgery, Punjab Government Dental College and Hospital, Amritsar, Punjab, India.

### Manuscript Info

#### Manuscript History

Received: 06 May 2025

Final Accepted: 09 June 2025

Published: July 2025

#### Key words:-

Glandular Odontogenic Cyst, Jaw  
Cyst, Enucleation, Odontogenic Cyst,  
Cytokeratin 19

### Abstract

Glandular odontogenic cysts (GOCs) are rare odontogenic, solitary or multiloculated intrabony cysts. The importance of GOCs lies in the fact that they exhibit a tendency for recurrence similar to keratocystic odontogenic tumors and that they may be confused microscopically with central mucoepidermoid carcinoma.

**Case Report:** A 71-year-old male patient complained of swelling in his anterior region of lower jaw since 6 months causing expansion of lower labial cortex. This cystic lesion was managed by Enucleation and curettage technique.

**Conclusion:** A thorough clinical and radiological evaluation along with a meticulous and precise histopathological examination is important to prevent the recurrence of this aggressive cystic lesion.

"© 2025 by the Author(s). Published by IJAR under CC BY 4.0. Unrestricted use allowed with credit to the author."

### Introduction:-

Glandular odontogenic cyst (GOC) is an intrabony, developmental cyst of the jaw which is a clinically rare and histopathologically unusual cyst with unpredictable and potentially aggressive behavior. [1] Several case reports and case series have been reported over last three decades, and recent publications accounted for about 200 cases in the literature. Thus, GOCs, is a rare, but now a well-known entity comprising for about < 0.5% of all odontogenic cysts. [2] It was first discussed in 1984 at meeting of the International Association of Oral Pathologists but first documented by Padayachee and Van Wyk in 1987 by reporting two cases that shared the features of both botryoid odontogenic cysts and central mucoepidermoid tumors and suggested that the term "sialo-odontogenic cyst" be adopted for such lesions to avoid confusion and mismanagement. A year later, Gardner et al reported eight other cases and gave the name "glandular odontogenic cyst"; because to its unusual histopathological features, they regarded it as a distinct entity. In 1992, the revised edition of a World Health Organization report included this term as "developmental odontogenic epithelial cyst." It has also been termed "mucoepidermoid cyst" by Sadeghi et al. [3] The term "polymorphous odontogenic cyst" was introduced by High et al, in 1996 due to its varied histological appearances. [4]

Most commonly GOCs are reported in middle-aged adults, with highest prevalence at fifth and sixth decades of life, however, cases in paediatric patients have also been documented. [2] No gender predilection is seen. However, reports have been presented that in South African population GOCs has a higher male predominance which facilitates the

**Corresponding Author:- Rachana Galinde**

Address:- Junior Resident, Department of Oral and Maxillofacial Surgery, Punjab Government Dental College and Hospital, Amritsar, Punjab, India.

difference in gender distribution in various population groups[5]. In 73.2 to 80% of the lesions, the cyst accounts to be located in the mandible, mainly in anterior region (about 60% cases) and 20 to 26.8% in the maxilla. GOCs have shown to occur in the globulomaxillary relation when the maxilla is affected. About 75% of lesions are symptom-less and generally associated with swelling/expansion in 43.5 to 87% which is reported to be the most common presenting complaint. [2]

The microscopic features of GOC, especially the morphology of the epithelium, potentially suggest an origin from the remnants of dental lamina showing papillary projections and focal thickenings (plaques) within it along with mucous cells, interepithelial gland-like structures, and absence of inflammation in the connective tissue.[4]

Radiographic presentation is not remarkable. Radiographically, the lesion may appear as unilocular or multilocular radiolucency, usually with well-defined margins and scalloped border. Imaging analysis is quite helpful for the diagnosis of glandular odontogenic cyst, but histological analysis is essential for differentiating glandular odontogenic cyst from other odontogenic cysts and central mucoepidermoid carcinoma due to lack of peculiar difference in radiological findings among these lesions.[6] Treatment of GOC is yet controversial and varies from curettage, enucleation to en-bloc surgical resection.

The aim of this report is to present a rare case of GOC in an adult male patient in the anterior mandible region, emphasizing the clinical, radiographic, histopathological aspects along with note on its treatment.

### Case Report

A 71-year-old male reported to Department of Oral & Maxillofacial Surgery, Punjab Government Dental College & Hospital, Amritsar with the chief complaint of swelling in his anterior region of lower jaw since 6 months. On general physical examination, all the vital signs were within normal range and he denied of any drug allergy. Patient gave the history that he first noticed the slight swelling in his lower anterior region of jaw 6 months ago which gradually increased to its present size [Fig. 1]. There was no symptom of pain or any sensory changes.

Intraoral examination revealed mild swelling w.r.t to anterior region of mandible extending from 44 tooth to 33 tooth region. Bony expansion of lower labial cortex was quite obvious. Mobility was present w.r.t 42, 43. The lesion showed no signs of inflammation. On palpation, it was nontender, non-compressible and hard in consistency. There was no lymphadenopathy. The results of patient's routine blood investigations were within normal range. Patient was advised an OPG for radiographic evaluation which revealed a corticated, unilocular radiolucency extending from tooth 44 to 33. On aspiration of cystic lesion, blood-tinged fluid was obtained [Fig. 2]. Hence, a differential diagnosis was made for Aneurysmal Bone Cyst. Patient was then suggested for a CBCT Scan.

CBCT MANDIBLE [Fig. 4] unveiled

- A well-defined unilocular osteolytic lesion seen in anterior mandible extending from 44 tooth to 33 tooth.
- Lesion showed thick sclerotic and scalloped borders, extending superiorly in between the roots of the teeth.
- Lesion was mildly expansile and completely radiolucent.
- No root resorption / root flaring seen.
- Thinning and breach in both labial and lingual cortex seen.
- Dimensions of lesion – 27.6mm x 9.8mm x 19.7mm (lxbxh)

The patient was explained about the lesion, the surgical treatment plan and informed consent was taken. Under general anesthesia, Enucleation & curettage of the cystic lesion was performed. A crevicular incision was given w.r.t lower anterior labial mucosa. A Trapezoidal flap was raised. A bony window was created over the cystic lesion on labial cortex [Fig. 5]. Enucleation & curettage of the cyst was done [Fig. 6], along with extraction of teeth 31, 32, 41, 42, 43. Sharp bony margins were rounded off using bone file and carbide bur. Primary closure was done with 3-0 vicryl. Cystic lining was sent for histopathological examination [Fig. 7]. Later patient was followed up for evaluation of healing and signs of recurrence if any. [Fig. 8]

### Discussion:-

A case of GOC which is a rare developmental cyst of the jaws, has been presented. It is an uncommon developmental cyst showing up with a frequency of 0.012%–1.3% of all the jaw cysts and 0.017% its prevalence rate [7]. About 200 cases have been documented in the literature, yet GOC proves to be a diagnostic challenge due to its bizarre histopathological presentation [2]. Literature demonstrated mean age for occurrence of GOC to be 5<sup>th</sup>- 6<sup>th</sup> decade. In

our case it was reported during early 70s. The site of lesion was the most common site of occurrence for GOCs i.e anterior mandible.

GOCs display nonspecific and no pathognomonic radiographical presentation. It may present as a multilocular or unilocular radiolucency with well-defined borders. This makes its recognition practically impossible only on the basis of clinical and radiographic findings. Histopathological examination alone allows for certain diagnosis of the cyst. Clinical and radiographic examination can misguide the diagnosis towards the dentigerous cyst, odontogenic keratocyst, radicular cyst, ameloblastoma, central giant cell lesion, fibrous dysplasia, and central mucoepidermoid carcinoma (MEC). [4]

Whereas the microscopic features of the GOC hold its resemblance with the lateral periodontal cyst (LPC), botryoid odontogenic cyst (BOC), and the central MEC. Many authors assumed that the GOC could be the clinical microscopic variant of LPC due to the plaque-like epithelial thickening in LPC [8]. But the low aggressive nature, limited growth potential and low recurrence nature of LPC has annulled GOC. The multilocularity, multicystic and GOC was assumed to be the variant of BOC. This was nullified by some authors because of the mucous and ciliated epithelial cells and mucous pooled cystic spaces in GOC and not in BOC, thus differentiating both the entities [9].

Kaplan et al. [10] firstly reported the number of microscopic features that are requisite for GOC to be diagnosed. Based on their analysis, it was proposed that the presence of each of the major criteria is obligatory for diagnosis and the presence of minor criteria supports the diagnosis but are not obligatory. [Table- 1]

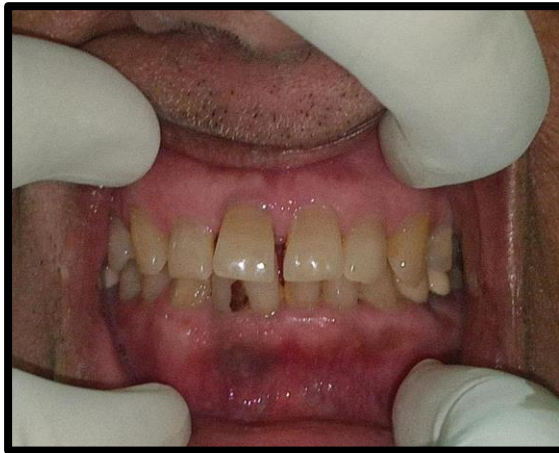The authors later drew the inference that not all of Kaplan et al. major criteria are necessary for diagnosis, but more presumably a combination of specific microscopic features. Therefore, diagnosis is not necessarily to be corresponding with their major and minor criteria [2]. Fowler et al. [11] enlisted ten histologic parameters to distinguish GOCs from other lesions with a similar histopathological appearance (GOC mimickers). It was suggested, following statistical analysis that a reliable diagnosis of GOC can be only made if at least 7 of 10 criteria are fulfilled. Fowler et al. concluded that eosinophilic cuboidal cells (hobnail cells) are important for diagnosis but are not gold standard for GOC when no other microscopic parameters are present. Moreover, the presence of intraepithelial microcysts, clear (vacuolated) cells, epithelial spheres, variable thickness, and multiple compartments are superior in distinguishing GOCs from GOC mimickers.

Pires et al. [12] researched the role of expression of cytokeratin 18 and 19 (CKs 18 and 19) in GOC and CMEC. It has been advocated that CKs 18 and 19 could turn out to be useful in differentiating between the two entities. The researchers concluded that all CMEC expressed CKs 18 whereas GOCs expressed CKs 19 consisting with previous studies. Ultimately, to achieve an accurate diagnosis, histologic features are must to be correlated with clinical and radiologic information. Coming to the management of the lesion, Enucleation, curettage and marsupialization prior to enucleation are the most common treatment for GOC but is associated with a recurrence rate of 21.6 to 50%. [2]

The case presented with management of GOC with enucleation and curettage method resulting in no recurrence on evaluation during regular follow ups.

**Table 1:- Kaplan et al [10].**

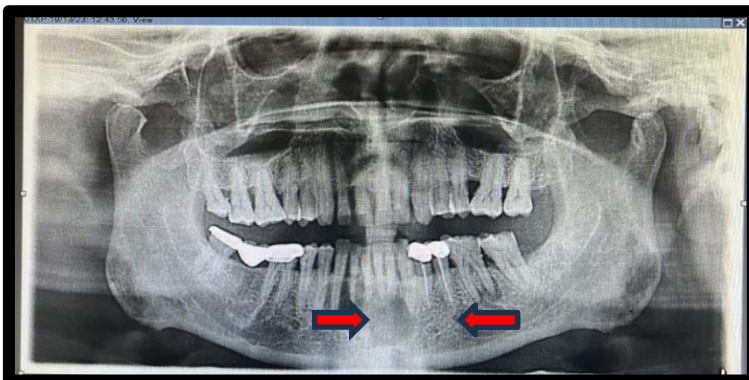
| Major criteria  | Minor criteria   |
|---|--|
| 1. Squamous epithelial lining, with a flat interface with the connective tissue wall, lacking basal palisading.   | Papillary proliferation of the lining epithelium.            |
| 2. Epithelium exhibiting variations in thickness along the cystic lining with or without epithelial “spheres” or “whorls” or focal luminal proliferation. | 2. Ciliated cells  |
| 3. Cuboidal eosinophilic cells or “hobnail” cells.  | 3. Multicystic or multiluminal architecture.                 |
| 4. Mucous (goblet) pools, with or without crypts lined by mucous-producing cells.   | 4. Clear or vacuolated cells in the basal or spinous layers. |
| 5. Intraepithelial glandular, microcystic, or duct-like structures  |  |



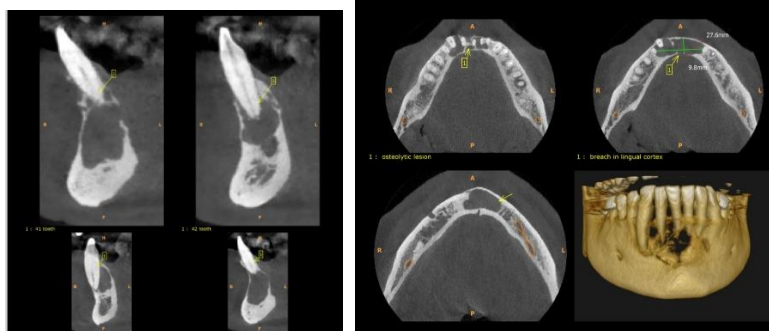
[Fig. 1]Pre-operative picture,

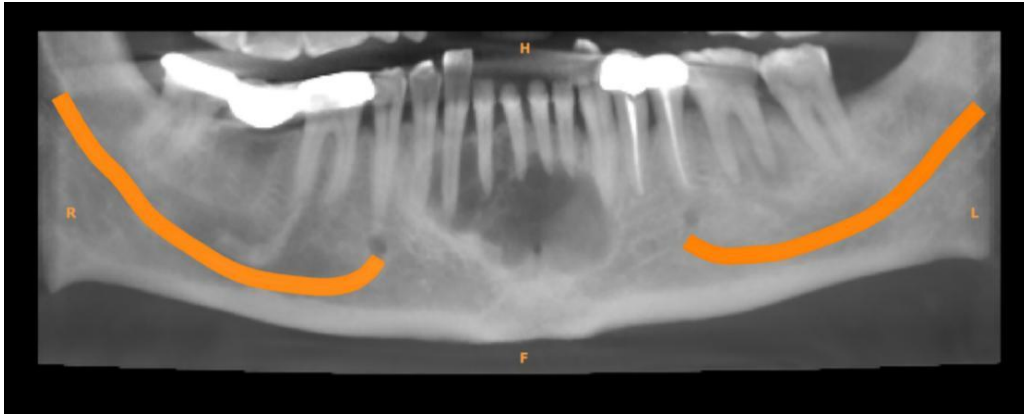


[Fig. 2]Aspirated Fluid

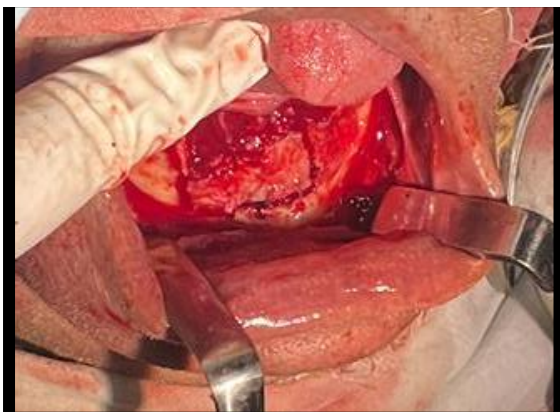

**OPG revealing  
cystic lesion**

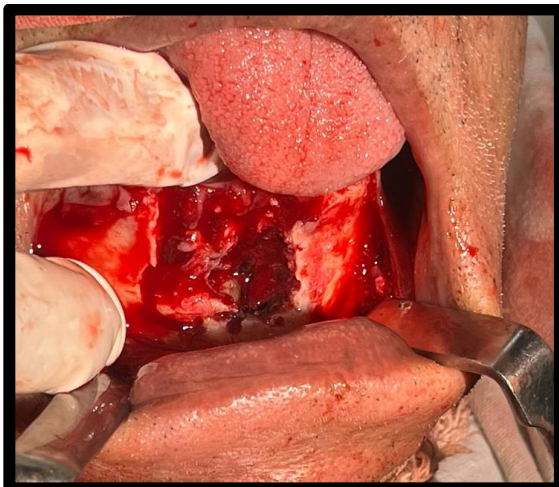




[Fig. 4]:-CBCT Scan.

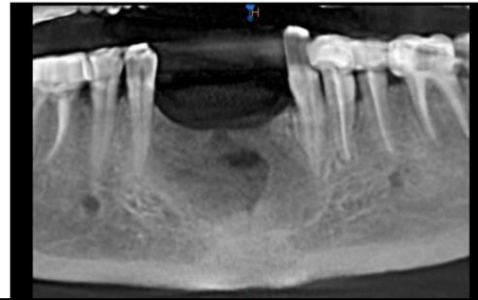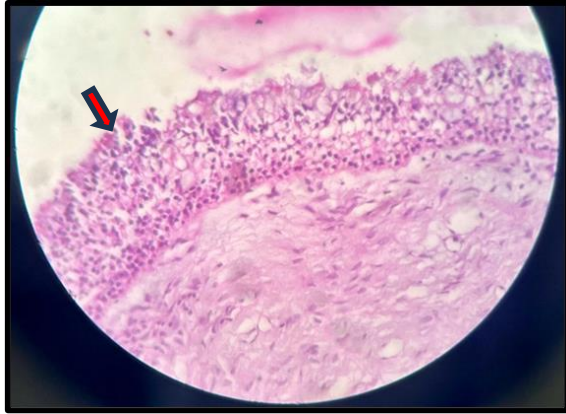


[Fig. 5] Bony window created.



[Fig. 6] Enucleation & curettage done.





**[Fig. 8] Follow-up CBCT scan**

**Fig. 7- Histopathological image showing cystic lining of pseudostratified epithelium hobnail cells (indicating with red arrow) in superficial epithelium and connective tissue wall, mucous secreting cells with intra-epithelial sperule formation and with loosely arranged collagen fibre bundles and fibroblasts.**

### Conclusion:-

GOC is a rare and aggressive lesion with a relatively high recurrence rate. Hence, a careful clinical and radiological evaluation along with a meticulous and precise histopathological examination must be carried out. CT or CBCT scans are recommended for diagnosing GOC because they provide accurate information about the lesion.

### References:-

1. Urs, A.B., Kumar, P., Augustine, J. and Malhotra, R., 2017. Glandular odontogenic cyst: Series of five cases. *Journal of Oral and Maxillofacial Pathology: JOMFP*, 21(2), p.239.
2. Gorgis, R., Krarup, S.A.C., Reibel, J. and Nørholt, S.E., 2023. Glandular Odontogenic Cyst: a Case Report and Literature Review. *Journal of Oral & Maxillofacial Research*, 14(2).
3. Tambawala, S.S., Karjodkar, F.R., Yadav, A., Sansare, K. and Sontakke, S., 2014. Glandular odontogenic cyst: A case report. *Imaging science in dentistry*, 44(1), pp.75-79.
4. Raju, S.P., Reddy, S.P. and Ananthnag, J., 2015. Glandular odontogenic cyst of the anterior mandible. *North American journal of medical sciences*, 7(2), p.65.
5. Nel, C., Robinson, L., Roza, A.L.O.C., Ker-Fox, J., Gomes, N.R., Fonseca, F.P., Santos-Silva, A.R., Románach, M.J., Vargas, P.A. and van Heerden, W.F., 2022. Clinical and radiologic spectrum of glandular odontogenic cysts: A multicenter study of 92 cases. *Oral Surgery, Oral Medicine, Oral Pathology and Oral Radiology*, 133(5), pp.593-603.
6. Ogura, I., Tsuchimochi, M., Ono, J., Kanri, Y., Okada, Y., Fujii, K., Yamaguchi, A. and Sekimoto, T., 2017. Glandular odontogenic cyst: a report of four cases. *Oral Science International*, 14(2), pp.43-49.
7. Krishnamurthy, A., Sherlin, H.J., Ramalingam, K., Natesan, A., Premkumar, P., Ramani, P. and Chandrasekar, T., 2009. Glandular odontogenic cyst: report of two cases and review of literature. *Head and neck pathology*, 3, pp.153-158.
8. Takeda, Y., 1994. Glandular odontogenic cyst mimicking a lateral periodontal cyst: a case report. *International journal of oral and maxillofacial surgery*, 23(2), pp.96-97.
9. Lin, C.C., Chen, C.H., Lai, S., Chen, Y.K., Wan, W.C., Lu, S.Y., Hong, J.M. and Lin, L.M., 2000. Glandular odontogenic cyst: A case report. *Kaohsiung Journal of Medical Sciences*, 16(1), pp.53-58.
10. Kaplan, I., Anavi, Y. and Hirshberg, A., 2008. Glandular odontogenic cyst: a challenge in diagnosis and treatment. *Oral diseases*, 14(7), pp.575-581.
11. Fowler, C.B., Brannon, R.B., Kessler, H.P., Castle, J.T. and Kahn, M.A., 2011. Glandular odontogenic cyst: analysis of 46 cases with special emphasis on microscopic criteria for diagnosis. *Head and neck pathology*, 5, pp.364-375.
12. Pires, F.R., Chen, S.Y., da Cruz Perez, D.E., De Almeida, O.P. and Kowalski, L.P., 2004. Cytokeratin expression in central mucoepidermoid carcinoma and glandular odontogenic cyst. *Oral oncology*, 40(5), pp.545-551.