

Cite this article as: Baruteau A-E, Belli E, Boudjemline Y, Laux D, Lévy M, Simonneau G *et al.* Palliative Potts shunt for the treatment of children with drug-refractory pulmonary arterial hypertension: updated data from the first 24 patients. *Eur J Cardiothorac Surg* 2015;47:e105–e110.

Palliative Potts shunt for the treatment of children with drug-refractory pulmonary arterial hypertension: updated data from the first 24 patients

Alban-Elouen Baruteau^{a,b,*}, Emre Belli^a, Younes Boudjemline^{c,d}, Daniela Laux^a, Marilyne Lévy^{c,d},
Gérald Simonneau^{b,e,f}, Adriano Carotti^g, Marc Humbert^{b,e,f} and Damien Bonnet^{c,d}

^a Marie Lannelongue Hospital, Pediatric and Congenital Cardiac Surgery, M3C, Reference Center for Complex Congenital Heart Diseases, Le Plessis Robinson, France

^b Paris Sud University, Le Kremlin Bicêtre, France

^c AP-HP, Necker Hospital for Sick Children, Pediatric Cardiology, M3C, Reference Center for Complex Congenital Heart Diseases, Paris, France

^d Université Paris Descartes, Sorbonne Paris Cité, Paris, France

^e AP-HP, Bicêtre Hospital, Pneumology, Reference Center for Severe Pulmonary Hypertension, TORINO, Le Kremlin-Bicêtre, France

^f INSERM UMR 999, LabEx-LERMIT, Marie Lannelongue Hospital, Le Plessis Robinson, France

^g Pediatric Cardiac Surgery, Bambino Gesù Children's Hospital, IRCCS, Rome, Italy

* Corresponding author. Département de Chirurgie Cardiaque Pédiatrique et Congénitale, Centre Chirurgical Marie Lannelongue, 133 avenue de la Résistance, 92350 Le Plessis-Robinson, France. Tel: +33-1-40942429; fax: +33-1-40948642; e-mail: a.baruteau@gmail.com (A.-E. Baruteau).

Received 3 July 2014; received in revised form 17 October 2014; accepted 24 October 2014

Abstract

OBJECTIVES: Palliative Potts shunt has been proposed in children with suprasystemic pulmonary arterial hypertension (PAH).

METHODS: A retrospective multicentre study was performed to assess short- and long-term outcomes after Potts shunt.

RESULTS: From 2003 to 2014, 24 children underwent a Potts shunt [19 surgical, median age: 7.7 years (1.5–17 years), median weight: 19.5 kg (10.2–47 kg) and 5 transcatheter, median age: 8.1 years (2.3–9.7 years), median weight: 22 kg (12.5–31 kg)] for drug-refractory PAH. For the first time in humans, we performed an unidirectional valved Potts anastomosis in a child with infrasystemic PAH on intravenous epoprostenol who experienced repeated central line infections. Severe postoperative complications occurred in 6 patients (25.0%, all from the surgical group) including 3 early deaths (12.5%) related to low cardiac output. After a median follow-up (FU) of 2.1 years (range, 3 months to 14.3 years, ≥ 8 years in 7 patients), World Health Organization (WHO) functional class was dramatically improved in the 21 survivors, all being in WHO-functional class 1 or 2 ($P < 0.05$); none experienced syncope during the FU; none had overt right ventricular failure; mean 6-min walk distance improved from $42.3 \pm 10.0\%$ to $81.2 \pm 9.7\%$ of adjusted values for age and sex ($P < 0.001$), BNP/NT-proBNP levels normalized in all; and weaning of intravenous epoprostenol was obtained in all patients who received triple combination as pre-Potts anastomosis therapy. Finally, all survivors caught up to normal growth curves. Arterial oxygen saturation gradient between upper and lower limbs persisted at the last FU ($94.7 \pm 3.6\%$ vs $81.6 \pm 5.1\%$, $P < 0.001$). One patient required double lung transplantation 6 years after a surgical Potts shunt.

CONCLUSIONS: Palliative Potts shunt allows prolonged survival and dramatic, long-lasting improvement in functional capacities in children with severe, drug-refractory PAH. The Potts shunt might be considered as a first surgical or interventional step in the management of children with severe, drug-refractory PAH, leaving the door open for further lung transplantation, if needed.

Keywords: Potts shunt • Paediatric • Pulmonary arterial hypertension

INTRODUCTION

Idiopathic pulmonary arterial hypertension (IPAH) can present at any age from infancy to adulthood and remains a progressive fatal disease [1]. In most children, IPAH is usually diagnosed in its later stages due to non-specific symptoms, making the prognosis poor [2–6]. Life expectancy of patients with an Eisenmenger syndrome is significantly superior to that of IPAH patients [7]. In an attempt to convert severe, drug-refractory paediatric IPAH into an Eisenmenger physiology, we have proposed to perform a Potts shunt, namely a

direct side-by-side anastomosis from the left pulmonary artery to descending aorta [8]. We then reported promising results with prolonged survival and persistent improvement in functional capacities, positioning the palliative Potts shunt as a new surgical alternative to lung or heart-lung transplantation in severely ill children with suprasystemic IPAH [9]. The promising results from this surgical technique have inspired us and others to try interventional methods in creating a connection between the left pulmonary artery and descending aorta, opening the door to new hopes and new strategies in the management of severe IPAH [10–14].

We here report the clinical outcomes of the first 24 patients who underwent either a surgical or a transcatheter Potts shunt for drug-refractory IPAH.

MATERIALS AND METHODS

A retrospective multicentre study was conducted in three tertiary centres of paediatric cardiac surgery (Marie Lannelongue Hospital, Necker Hospital and Bambino Gesù Children's Hospital). All patients <15 years old who underwent a Potts shunt for drug-refractory PAH were included in the study. The ethics committee of each institution approved this study, and all parents or legal guardians gave their informed consent to study inclusion. Between 2003 and 2014, 24 children underwent a Potts shunt (19 surgical, 5 transcatheter) for drug-refractory IPAH. Data were collected with special attention to clinical data [World Health Organization (WHO) functional class, history of syncope, overt right ventricular failure clinical signs, upper and lower limb oxygen saturations and 6-min walk distance (6MWD) when available], biological data [BNP or N-terminal pro-brain natriuretic peptide (NT-proBNP)], echocardiographic data, perioperative characteristics and outcomes at the last follow-up (FU). 6MWD values were compared with normal values adjusted for age and sex [15]. Children received supportive therapy including diuretics, oral anticoagulation and oxygen on a case-by-case basis. From 2003 to 2007, specific PAH therapies including oral endothelin receptor antagonists and phosphodiesterase type-5 inhibitors, and subcutaneous or intravenous prostanoids were used either as sequential add-on therapy or as up-front combination therapy according to clinical status at baseline and worsening events during the FU. Since 2007, a surgical Potts shunt was considered only in patients receiving a triple combination of bosentan, sildenafil and either intravenous epoprostenol or subcutaneous treprostinil, except for a 7-year-old child referred from another country where epoprostenol was not available, and who received only oral combination of bosentan and sildenafil at the time of surgery. Transcatheter Potts shunt was performed in 5 patients with suprasystemic IPAH by stenting of a restrictive or probe-patent ductus arteriosus (PDA). This procedure was applied at the time of clinical worsening in children who were only on PAH oral drug therapy. A right heart catheterization was performed in 17 patients, all of them being non-responders for acute vasoreactivity testing. The other 7 patients did not undergo right heart catheterization before the Potts shunt because of rapid clinical deterioration (WHO functional class IV), and a very unstable haemodynamic condition when the Potts shunt was planned. We have described both the surgical and transcatheter techniques that have been used in detail in previous reports [9, 10]. The follow-up including physical examination and transthoracic echocardiography was achieved every 3 months by the referring paediatric cardiologist, and at least once a year at one of the three participating tertiary institutions. Cardiac catheterization was not systematically performed after the surgical Potts shunt.

Statistical analysis

Analyses were performed using the PASW Statistics 18 software (SPSS, Inc. Chicago, IL, USA). Categorical variables were described as numbers and percentages. Continuous variables were tested

for normality with the χ^2 test, and variables with normal distribution were expressed as mean \pm standard deviation (SD), whereas those with non-normal distribution were expressed as median (min-max). *P*-values < 0.05 were considered statistically significant.

RESULTS

Preprocedural considerations

Twenty-four children (19 surgical, 5 transcatheter, male/female sex ratio = 0.5) underwent a Potts shunt for palliation of drug-refractory PAH. PAH was diagnosed at a median age of 3.8 years (4 months to 15 years). Potts shunt was performed at a median delay of 1.4 years (3 months to 13.9 years) after PAH diagnosis. At the time of procedure, the majority of children were in WHO-functional class IV except for those who had a percutaneous Potts shunt, a mean 6MWD at $42.3 \pm 10.0\%$ compared with normal values adjusted for age and sex and an elevated BNP > 500 ng/ml or a NT-proBNP > 1000 pg/ml in 71.4% of them. Preoperative PAH therapy consisted in a triple combination of bosentan, sildenafil and intravenous epoprostenol in 4 patients, a triple combination of bosentan, sildenafil and subcutaneous treprostinil in 7 patients, a combination of bosentan and epoprostenol in 4 patients, a combination of bosentan and sildenafil in 5 patients, a bosentan monotherapy in 2 patients and a sildenafil monotherapy in 2 patients.

Procedural considerations

Nineteen patients underwent a surgical Potts shunt at a median age of 7.7 years (1.5–17 years) and a median weight of 19.5 kg (10.2–47 kg). The mean size of the shunt was 10 ± 3 mm. Side-clamping of the aorta was 10.8 ± 3.3 min. For the first time in human, we performed an unidirectional valved Potts anastomosis (Fig. 1A) in a 6-year-old, 21-kg girl with infrasytemic IPAH at right heart catheterization (pulmonary artery pressures: 81/33/55 mmHg, systemic artery pressures: 111/44/67 mmHg) but rapid clinical worsening and repeated infectious and mechanical complications with the central line while receiving a triple combination PAH therapy with bosentan, sildenafil and intravenous epoprostenol. The

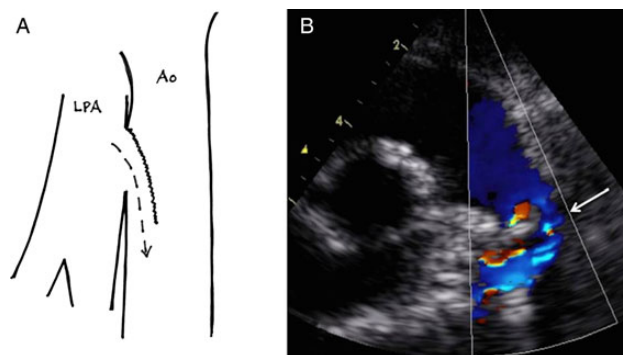


Figure 1: First-in-man use of a surgical unidirectional valved Potts shunt. A surgical valved Potts shunt (A) was used in a 6-year old, 21-kg girl with infrasytemic, severe idiopathic pulmonary arterial hypertension (PAH) receiving a triple combination PAH therapy with bosentan, sildenafil and intravenous epoprostenol. Postoperative echocardiography demonstrated intermittent, unidirectional, right-to-left shunting through the valved Potts (B, white arrow).

technique was similar to that we previously evaluated in an animal model [16]. A polytetrafluoroethylene (PTFE) patch was inserted until the superior half of the Potts using separated stitches. Postoperative echocardiography demonstrated intermittent, unidirectional right-to-left shunting through the valved Potts (Fig. 1B). A transcatheter Potts shunt was performed by tiny and restrictive PDA stenting in 5 patients at a median age of 8.1 years (2.3–9.7 years) and a median weight of 22 kg (12.5–31 kg). One patient required deployment of a second stent as the angiogram after the first stent showed a tight angulation between the stent and the roof of the main pulmonary artery. Mean stented ductus diameter was 8.3 ± 1.8 mm.

Short-term outcomes

Major postoperative complications occurred in 6 patients (25.0%, all from the surgical group) with: (i) 3 deaths (12.5%) owing to low cardiac output, 1 in the surgical theatre, the 2 others at postoperative days 11 and 13, (ii) a transient paraplegia at day 3 in another child, (iii) a medically-treated chylothorax, (iv) a significant tracheal stenosis requiring multiple balloon dilatations and (v) a profound upper limb arterial oxygen desaturation due to a double right-to-left shunting at both the atrial and the arterial levels in a 13-year old girl who underwent successful transcatheter closure of a secundum atrial septal defect by a 24-mm Amplatzer Septal Occluder at postoperative day 2. In the 23 patients who survived the procedure, a significant arterial oxygen saturation gradient between upper and lower limbs was present in the intensive care unit ($93.5 \pm 4.1\%$ vs $70.0 \pm 9.3\%$, $P < 0.001$).

Long-term outcomes

The 21 survivors were discharged from the hospital. One patient died during a severe RSV infection 2 years after PDA stenting. The remaining 20 are still alive after a median follow-up of 2.1 years (3 months to 14.3 years, FU ≥ 2 years in 13 patients, FU ≥ 8 years in 7 patients, no patient lost to FU). Characteristics and outcomes of the 19 long-term survivors without death or transplantation

(4 deaths, 1 lung transplantation) are summarized in Table 1. All patients experienced a dramatic improvement in the functional status immediately after either surgical Potts shunt or PDA stenting. This improvement was sustained through the last FU except for 2 patients (9.5%) with a WHO functional class III late after a surgical Potts. Mean 6MWD compared with values in normal children adjusted for age and sex, was significantly improved ($42.3 \pm 10.0\%$ vs $81.2 \pm 9.7\%$, $P < 0.001$). The arterial oxygen saturation gradient between upper and lower limbs remained significant at the last FU ($94.7 \pm 3.6\%$ vs $81.6 \pm 5.1\%$, $P < 0.001$). Non-invasive haemodynamic evaluation assessed non-restrictive Potts shunt with isosystemic pulmonary artery pressures, flattening of the interventricular septal curvature and preservation of a normal cardiac output on echocardiography. Syncope and right heart failure signs disappeared and all children caught up to normal growth curves. During the FU, a 14-year-old girl who had a surgical Potts procedure 6 years before with a favourable outcome and subsequent weaning from epoprostenol therapy, presented recurrent massive haemoptysis due to multiple, distal aneurysmal arterio-venous fistulas in both lungs and worsening of dyspnoea despite bosentan and sildenafil therapy. She was then listed for double lung transplantation (DLTx). Transcatheter closure of the Potts shunt was performed just before the transplant procedure to allow efficient cardiopulmonary bypass, using an endovascular stent graft (Medtronic Endurant 26×100 mm; Medtronic, Inc., Minneapolis, MI, USA). Standard DLTx was then performed through a clamshell incision using cardiopulmonary bypass with an uneventful postoperative course [17]. Another 17-year-old girl from this series is currently awaiting transplantation, listed for DLTx, because of syncope and right heart failure. She had a surgical Potts shunt 7 years before with a favourable mid-term outcome and weaning from epoprostenol therapy. At last visit, all long-term survivors were successfully weaned from intravenous epoprostenol therapy. Two patients with a <1-year surgical Potts shunt still receive a triple combination PAH therapy with subcutaneous treprostinil. Fourteen patients receive only oral drugs (a combination of bosentan and sildenafil in 11 patients, bosentan monotherapy in 2 patients and sildenafil monotherapy in 1 patient) and 4 patients receive no PAH therapy at all. The number of PAH treatments significantly decreased at last visit (2.3 ± 0.7 vs 1.6 ± 0.9 , $P < 0.05$).

Table 1: Characteristics of the 19 long-term survivors without death or transplantation, preoperative time compared with the last follow-up

Characteristics	Preoperative data	Last follow-up 2.0 years (3 months to 14.3 years)	P-value
Median WHO functional class	4 (2–4)	2 (1–3)	<0.05
Syncope/RV failure physical signs	18	1	<0.001
Mean 6 MWD (m)	260.2 ± 85.1 ($n = 9$ patients)	522.6 ± 93.2 ($n = 12$ patients)	<0.001
Mean 6 MWD compared with normal values adjusted for age and sex (%)	$42.3 \pm 10.0\%$	$81.2 \pm 9.7\%$	<0.001
Upper limb SaO ₂ (%), mean \pm SD	95.9 ± 2.2	94.7 ± 3.6	
Lower limb SaO ₂ (%), mean \pm SD	95.9 ± 2.2	81.6 ± 5.1	
SaO ₂ upper/lower limb gradient (%)	0	13.2 ± 5.2	<0.001
Interventricular septal curvature	Inverted	Flattening	
BNP > 500 pg/ml or NT-proBNP > 1000 pg/ml	71.4% ($n = 14$ patients)	0% ($n = 16$ patients)	<0.001
Intravenous epoprostenol	6	0	<0.001
Triple combination PAH therapy	8	2	<0.05
Pulmonary vasodilators (number of treatments)	2.3 ± 0.7	1.6 ± 0.9	<0.05

WHO: World Health Organization; RV: right ventricle; 6MWD: 6-min walk distance; SaO₂: arterial oxygen saturation; PAH: pulmonary arterial hypertension.

DISCUSSION

The Potts shunt has been recently proposed as a novel alternative to lung transplantation or balloon atrial septostomy in children with drug-refractory PAH [9]. However, this approach is still emerging and data on early and long-term outcomes are scarce. Ours is the largest cohort of consecutive patients who underwent a palliative Potts shunt. Our main finding is that, despite severe early complications in 25% of the patients, long-term results are very good with prolonged survival and significant improvement in functional status.

Development of PAH therapies has significantly improved functional capacities, quality of life and also the survival for affected children [18, 19]. However, functional improvement is assessed only in the short term and survival rates are poor in children, with a survival rate of 71.9% at 5 years in children receiving PAH therapies [20]. Freedom from death or lung transplantation in children under medical treatment is <60% at 5 years [3], supporting the evaluation of other treatment options including surgical and interventional approaches in children whose conditions deteriorate while receiving maximal medical therapy. Alternatives for children who worsen under combined PAH treatment or those who experience right heart failure or repeated syncope were limited to lung or heart-lung transplantation and balloon atrial septostomy until recently. While both transplantation and balloon atrial septostomy carry several drawbacks and a limited median survival [21], the rationale of creating a right-to-left shunt at the arterial level in patients with suprasystemic PAH was to achieve the physiological advantages of a patent ductus arteriosus-related Eisenmenger syndrome and share its better prognosis. Indeed, life expectancy of patients with an Eisenmenger syndrome is significantly superior to that of IPAH patients, with a median long-term survival of 60 years in case of a simple underlying cardiac lesion such as a PDA [7]. Moreover, the theoretical advantage of the Potts shunt compared with balloon atrial septostomy is to create a permanent post-cardiac right-to-left shunt that does not provoke arterial oxygen desaturation in the upper part of the body, including the brain and the coronary circulation [8, 9].

In our series, the postoperative course remains a critical period with 25% of patients experiencing major early complications. However, our results confirm that immediate clinical improvement in survivors is long-lasting and allow progressive weaning from intravenous epoprostenol. The case of our patient who underwent successful DLTx 6 years after a surgical Potts shunt demonstrates that lung transplantation still remains a therapeutic option if needed, even after a surgical Potts [17]. To date, two other authors have published case reports of surgical Potts shunts [22, 23]. Although these 2 patients did not present with IPAH and a structurally normal heart as those from our series, postoperative functional status was markedly improved, suggesting that patients with severe PAH caused by other condition may benefit from this approach.

In patients with systemic level of pulmonary artery pressures, creation of a Potts anastomosis bears the risk of turning the inter-arterial right-to-left shunt into a left-to-right shunt, thus being responsible for a volume overload of the pulmonary circulation and increasing pulmonary artery pressures and a steal phenomenon from systemic to pulmonary circulations. To try to enlarge the scope of Potts candidates into patients with iso- or infrasytemic PAH, we evaluated surgical palliation of IPAH by a unidirectional valved Potts anastomosis in an animal model [16]. A prosthetic

patch of PTFE was used in 14 pigs to create the unidirectional valve and implanted in the Potts anastomosis. This study clearly demonstrated that the desaturation caused by the right-to-left shunting is controlled automatically by the unidirectional valve at the level of the anastomosis when the systemic pressure increases again to values superior to those in the pulmonary artery, without inversion of the shunt because of the valve in the anastomosis. This new concept that we successfully applied for the first time in a child from the present series can be of help in young adult patients with pulmonary hypertension and infra- or isosystemic pulmonary arterial pressure presenting with exercise intolerance.

The promising results from surgical Potts shunt inspired us and others to try percutaneous interventional methods in creating a connection between the aorta and the left pulmonary artery. This allows one to avoid the risks of a thoracotomy or sternotomy in patients with severe pulmonary hypertension. A small number of children with PAH have a small PDA. In those patients, the creation of a Potts by stenting the PDA is facilitated by the existing connection between the two great vessels [10, 13]. We recently showed that the opening of a tiny residual PDA by stenting allows for effective post-tricuspid decompression of the pulmonary circuit in patients with chronic, drug-refractory suprasystemic PAH [10]. Technically, the choice of stent diameter is a compromise between various parameters including age, weight, 'surgical' target diameter as well as narrowest PDA diameter. We chose to gradually enlarge the diameter of the connection by sequential balloon inflations with the aim of equalizing the PA and aortic systolic pressures, maintaining pulmonary blood flow and limiting the desaturation of the inferior limbs. In our experience, a 6-mm stent was used in the youngest patient and a 10-mm stent for the oldest patient. Bare metal stents were used in most cases. The existence of this tiny PDA was unknown in most patients in whom this technique was applied. The promising results of this technique compelled us to change the approach and protocol for management of patients with suprasystemic PAH. We now do a detailed cardiac catheterization in all patients with suprasystemic PAH to look for a PDA. Even a tiny PDA can be opened by stent insertion to equalize aortic and pulmonary pressure and improve RV function. If the PDA is absent, the technique is more complex and hazardous. Some authors have however recently reported the creation of shunt in 4 patients [11]. Using fluoroscopic guidance, they punctured the aorta at the site of apposition with the left pulmonary artery and deployed a 7-mm covered stent between the two vessels in all patients. The procedure was technically successful in 3 of 4 patients. One patient died of uncontrolled haemothorax during the procedure. The three successful procedures were technically demanding with 1 patient needing a second telescopic stent to prevent stent displacement, 2 patients experiencing balloon burst and one of them with detectable controlled bleeding.

There is a lot of room for improvement of this initial technique. A better understanding is, first of all, necessary to better understand the relationship of the aorta and left pulmonary artery. With the idea of a transcatheter Potts, Guo *et al.* [24] recently reported data on anatomical dispositions of both vessels in adults with PAH. Besides these anatomical features, other approaches were investigated to make this technique safer. The use of radiofrequency rather than trans-septal needle to perforate the aortic and pulmonary artery walls may improve the safety of transcatheter Potts [12]. Some authors investigated the creation of a connection using magnetic catheters in an experimental model (Fig. 2) [25]. Up to now, none of these have been tested in humans. Although

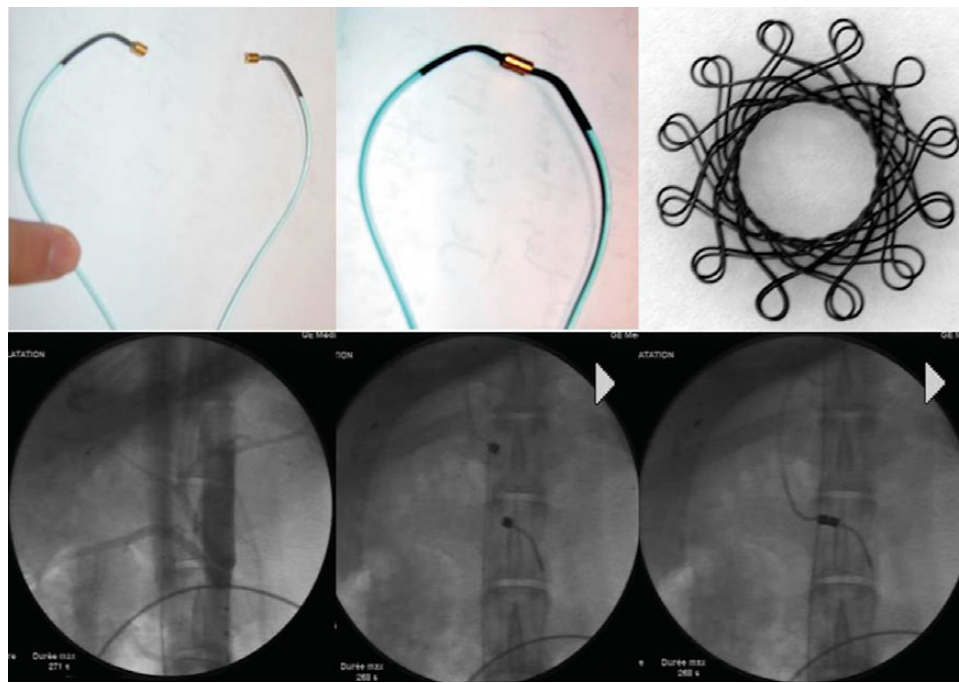


Figure 2: Experimental model of transcatheter creation of a Potts shunt. Upper panels: *ex vivo* images of magnet catheters and a device to maintain the contact and patency of created vascular connection. Lower panels: angiographic images showing inferior vena cava and descending aorta (left panel), magnet catheters being advanced in both vessels (middle panel) and creation of a contact between the two distant vessels by connection of the two catheters (right panel).

many questions remain unanswered about transcatheter Potts creation, this approach is nowadays a reality. The spatial proximity between aorta and left pulmonary artery makes the connection possible using transcatheter techniques. Improvements in safety using dedicated tools are on the way to make the procedure safe and reproducible by interventionists.

CONCLUSION

In an attempt to convert IPAH into a patent ductus arteriosus-related Eisenmenger physiology, the Potts shunt has been evaluated by multiple groups worldwide with very promising results. The majority of survivors of the early postoperative period have a prolonged survival and a dramatic improvement in their functional status in the long term. However, whether this functional improvement is long-lasting needs to be confirmed, as one of our patients has required DLTx 6 years after her Potts procedure and another one is on the waiting list. Based on these considerations, transcatheter techniques have also been applied and will continue to develop in the near future, in order to confirm the early encouraging results of this percutaneous approach and to improve its safety.

We believe that Potts shunt may be preferred to balloon atrial septostomy as it efficiently decompresses the right heart without provoking arterial oxygen desaturation in cerebral and coronary territories. According to the updated data, we propose that Potts shunt be considered as a first surgical or interventional step in the management of children with severe, drug-refractory PAH, leaving the door open for further lung transplantation, if needed.

Conflict of interest: Damien Bonnet discloses that he has relationships with drug companies including Actelion, Bayer Schering, GSK, Lilly, Novartis, Pfizer and United Therapeutics. In addition to

being investigator in trials involving these companies, relationships include consultancy service and membership to scientific advisory boards. Marc Humbert has relationships with drug companies including Actelion, Bayer, GSK and Pfizer. In addition to being investigator in trials involving these companies, relationships include consultancy service and membership to scientific advisory boards. Gérald Simonneau has relationships with drug companies including Actelion, Bayer, GSK and Pfizer. In addition to being investigator in trials involving these companies, relationships include consultancy service and membership to scientific advisory boards.

REFERENCES

- [1] Simonneau G, Gatzoulis MA, Adatia I, Celermajer D, Denton C, Ghofrani A *et al.* Updated clinical classification of pulmonary hypertension. *J Am Coll Cardiol* 2013;62:D34–41.
- [2] Ivy DD, Abman SH, Barst RJ, Berger RM, Bonnet D, Fleming TR *et al.* Pediatric pulmonary hypertension. *J Am Coll Cardiol* 2013;62:D117–126.
- [3] Moledina S, Hislop AA, Foster H, Schulze-Neick I, Haworth SG. Childhood idiopathic pulmonary arterial hypertension: a national cohort study. *Heart* 2010;96:1401–6.
- [4] Berger RM, Beghetti M, Humpl T, Raskob GE, Ivy DD, Jing ZC *et al.* Clinical features of paediatric pulmonary hypertension: a registry study. *Lancet* 2012;379:537–46.
- [5] Beghetti M, Berger RM, Schulze-Neick I, Day RW, Pulido T, Feinstein J *et al.* Diagnostic evaluation of paediatric pulmonary hypertension in current clinical practice. *Eur Respir J* 2013;42:689–700.
- [6] Barst RJ, McGoon MD, Elliott CG, Foreman AJ, Miller DP, Ivy DD. Survival in childhood pulmonary arterial hypertension: Insights from the registry to evaluate early and long-term pulmonary arterial hypertension disease management. *Circulation* 2012;125:113–22.
- [7] Diller GP, Dimopoulos K, Broberg CS, Kaya MG, Naghotra US, Uebing A *et al.* Presentation, survival prospects, and predictors of death in eisenmenger syndrome: a combined retrospective and case-control study. *Eur Heart J* 2006;27:1737–42.
- [8] Blanc J, Vouhe P, Bonnet D. Potts shunt in patients with pulmonary hypertension. *N Engl J Med* 2004;350:623.

- [9] Baruteau AE, Serraf A, Levy M, Petit J, Bonnet D, Jais X *et al.* Potts shunt in children with idiopathic pulmonary arterial hypertension: long-term results. *Ann Thorac Surg* 2012;94:817–24.
- [10] Boudjemline Y, Patel M, Malekzadeh-Milani S, Szezepanski I, Levy M, Bonnet D. Patent ductus arteriosus stenting (transcatheter Potts shunt) for palliation of suprasystemic pulmonary arterial hypertension: a case series. *Circ Cardiovasc Interv* 2013;6:e18–20.
- [11] Esch JJ, Shah PB, Cockrill BA, Farber HW, Landzberg MJ, Mehra MR *et al.* Transcatheter Potts shunt creation in patients with severe pulmonary arterial hypertension: initial clinical experience. *J Heart Lung Transplant* 2013;32:381–7.
- [12] Sayadpour Zanjani K. Radiofrequency perforation may increase the safety of transcatheter Potts shunt creation. *J Heart Lung Transplant* 2013;32:938.
- [13] Latus H, Apitz C, Moysich A, Kerst G, Jux C, Bauer J *et al.* Creation of a functional Potts shunt by stenting the persistent arterial duct in newborns and infants with suprasystemic pulmonary hypertension of various etiologies. *J Heart Lung Transplant* 2014;33:542–6.
- [14] Bhamra-Ariza P, Keogh AM, Muller DW. Percutaneous interventional therapies for the treatment of patients with severe pulmonary hypertension. *J Am Coll Cardiol* 2014;63:611–8.
- [15] Geiger R, Strasak A, Tremel B, Gasser K, Kleinsasser A, Fischer V *et al.* Six-minute walk test in children and adolescents. *J Pediatr* 2007;150:395–9.
- [16] Bui MT, Grollmus O, Ly M, Mandache A, Fadel E, Decante B *et al.* Surgical palliation of primary pulmonary arterial hypertension by a unidirectional valved Potts anastomosis in an animal model. *J Thorac Cardiovasc Surg* 2011;142:1223–8.
- [17] Paradela M, Mercier O, Baruteau A, Fadel E. Endovascular closure of Potts shunt before double lung transplantation for idiopathic pulmonary arterial hypertension. *J Thorac Cardiovasc Surg* 2013;146:e5–7.
- [18] Barst RJ, Beghetti M, Pulido T, Layton G, Konourina I, Zhang M *et al.* Starts-2: long-term survival with oral sildenafil monotherapy in treatment-naïve pediatric pulmonary arterial hypertension. *Circulation* 2014;129:1914–23.
- [19] Douwes JM, Roofthoof MT, Van Loon RL, Ploegstra MJ, Bartelds B, Hillege HL *et al.* Sildenafil add-on therapy in paediatric pulmonary arterial hypertension, experiences of a national referral centre. *Heart* 2014;100:224–30.
- [20] van Loon RL, Roofthoof MT, Delhaas T, van Osch-Gevers M, ten Harkel AD, Strengers JL *et al.* Outcome of pediatric patients with pulmonary arterial hypertension in the era of new medical therapies. *Am J Cardiol* 2010;106:117–24.
- [21] Schaefflbaum G, Lammers AE, Faro A, Moreno-Galdo A, Parakininkas D, Schecter MG *et al.* Bilateral lung transplantation for pediatric idiopathic pulmonary arterial hypertension: a multi-center experience. *Pediatr Pulmonol* 2011;46:1121–7.
- [22] Latus H, Apitz C, Schmidt D, Jux C, Mueller M, Bauer J *et al.* Potts shunt and atrial septostomy in pulmonary hypertension caused by left ventricular disease. *Ann Thorac Surg* 2013;96:317–9.
- [23] Petersen C, Helvind M, Jensen T, Andersen HO. Potts shunt in a child with end-stage pulmonary hypertension after late repair of ventricular septal defect. *World J Pediatr Congenit Heart Surg* 2013;4:286–9.
- [24] Guo K, Langleben D, Afilalo J, Shimony A, Leask R, Marelli A *et al.* Anatomical considerations for the development of a new transcatheter aortopulmonary shunt device in patients with severe pulmonary arterial hypertension. *Pulm Circul* 2013;3:639–46.
- [25] Levi DS, Danon S, Gordon B, Virdone N, Vinuela F Jr, Shah S *et al.* Creation of transcatheter aortopulmonary and cavopulmonary shunts using magnetic catheters: feasibility study in swine. *Pediatr Cardiol* 2009;30:397–403.

European Journal of Cardio-Thoracic Surgery 47 (2015) 110–112
doi:10.1093/ejcts/ezu482 Advance Access publication 21 December 2014

EDITORIAL COMMENT

Cite this article as: Amir G. In search of ideal surgical palliation for drug refractory pulmonary hypertension. *Eur J Cardiothorac Surg* 2015;47:e110–e2.

In search of ideal surgical palliation for drug refractory pulmonary hypertension

Gabriel Amir*

Department of Pediatric Cardiac Surgery, Schneider Children's Medical Center of Israel, Petach Tikva, Israel

* Corresponding author. Department of Pediatric Cardiac Surgery, Schneider Children's Medical Center of Israel, 14 Kaplan St., Petach Tikva, 4920235, Israel. Tel: +972-39-253715; fax: +972-39-253146; e-mail: gabriela@clalit.org.il; gabiamir@gmail.com (G. Amir).

Keywords: Congenital • Physiology • Pulmonary Hypertension • Potts shunt

Pulmonary arterial hypertension (PAH) is a rare disease with significant morbidity and mortality and an estimated prevalence of less than 10 cases per 1 million children. The 5-year survival of patients diagnosed with the disease is 74% regardless of whether the aetiology is idiopathic, familial, or associated with congenital heart disease. Patients with Eisenmenger's syndrome have a significantly better prognosis [1].

The response to acute vasodilator testing (AVT) tailors medical treatment protocols to calcium channel blockers, Endothelin receptor antagonists (Bosentan), Phosphodiesterase 5 Inhibitors (Sildenafil) and Prostanoids (Iloprost, Epoprostenol, Treprostinil). Data from the Registry to Evaluate Long-Term PAH Disease

Management (REVEAL) demonstrated that 41% of patients were on monotherapy treatment, 30% on dual therapy and 13% of patients were on triple drug therapy [1]. Despite maximal medical therapy, some patients have worsening symptoms and refractory PAH that requires aggressive surgical interventions to palliate their disease.

The armamentarium of surgical options for the treatment of PAH is scarce. Atrial septostomy is based on physiological rationale of decompressing the suprasystemic right ventricular pressure at the atrial level by allowing a right to left shunt, and preserving left ventricular output on the expense of cyanosis. Global analysis of 223 patients demonstrated procedural 24 h mortality of 7.1%