



## RESEARCH ARTICLE

### RUGOSCOPY: FOR ESTABLISHING INDIVIDUALITY- A RIVIEW

Dr. Megha Chaudhary, Dr. Sanjeet Singh, Dr. Kanika Sharma, Dr. Paramjit Singh, Dr. Neeraj Grover and Dr. Nishant Singh

#### Manuscript Info

##### Manuscript History

Received: 26 December 2023

Final Accepted: 28 January 2024

Published: February 2024

##### Key words:-

Palatal Rugae, Rugoscopy, Forensic Odontology, Human Identification

#### Abstract

The study of palatal shape or rugae pattern is known as rugoscopy. Rugae are anatomical folds that are present on anterior third of palate of upper jaw behind the incisive papillae which are used in forensic odontology for individual identification. They are unique and remain unchangeable throughout the life of a person from birth. Rugae pattern is an unique to a human as his or her fingerprints.

Copy Right, IJAR, 2024,. All rights reserved.

#### Introduction:-

Teeth are the most hardest and robust tissues of the human body.<sup>1</sup> Dentition of a person is useful for individual identification and comparison, if records exist for the purpose.<sup>2</sup> It focuses primarily on identifying a person's identity by analyzing the distinctive anatomical structure of the oral cavity.<sup>3</sup>

**Forensic odontology** can be defined as a branch of dentistry which deals with the appropriate handling and examination of dental evidence and with the proper evaluation and presentation of dental findings.<sup>4</sup> Dr. Oscar Amoedo was considered as the father of the forensic odontologist. The thesis done by him entitled 'L' Art Dentaireen Medicine Leagale' to the faculty of medicine earned him doctorate. This book is the first comprehensive text on forensic odontologist.<sup>5</sup> Keiser-Nelson defined forensic dentistry as "that branch of forensic dentistry that in the interest of justice deals with the proper handling and examination of dental evidence and the proper evaluation and presentation of dental findings".<sup>6</sup>

The first reported case of dental identification was that of an 80-year-old English warrior John Talbot, Earl of Shrewsbury, who fell in the battle of Castillon in 1453.<sup>7</sup> According to Keiser-Nielsen, forensic dentistry is defined as the "proper handling and examination of the dental evidence, in the interests of justice, so that the dental finding may be properly presented and evaluated".<sup>8</sup>

Human identification is based on scientific principles mainly involving fingerprints, dental records and DNA analysis.<sup>9</sup> Palatal rugae are irregular, asymmetric ridges of mucous membrane extending lateral from the incisive papilla and the anterior part of the median palatal raphe, which is just behind the maxillary central incisor teeth.<sup>10</sup> In the literature there is consensus opinion that palatal rugae remains fairly stable in number and do not undergo any change due to growth, ageing, tooth extraction and diseases.<sup>11</sup>

#### Rugoscopy:

Palatoscopy, or palatal rugoscopy, is the study of palatal rugae in order to establish a person's identity.<sup>12,13</sup> Lund (1924) observed a connective tissue core is embedded deeply between the sub mucosal fatty tissue and the stratum reticulum of the palate.<sup>14</sup> Palatal rugae are irregular, asymmetric ridges of mucous membrane extending lateral from the incisive papilla and the anterior part of the median palatal raphe.<sup>15,16</sup> Palatal rugae appears

in 3<sup>rd</sup> month of intrauterine life & its development is controlled by epithelial mesenchymal interactions.<sup>17,18</sup> The pattern is formed by 12-14<sup>th</sup> week of intrauterine life from the hard connective tissue.<sup>19</sup>

Caldas et al.<sup>1</sup> have reported that palatal rugae were first described by Winslow in 1753; however, Kuppler, in 1897, was the first person to study palatal anatomy to identify racial anatomic features. They have also cited in their article that palatal rugoscopy was first proposed in 1932 by a Spanish investigator named TroboHermisa. In 1937, Carrea developed a detailed study and established a way to classify palatal rugae.<sup>20</sup> Lysell<sup>21</sup> developed the first classification system for palatal rugae pairs. Lysell as well as Sassouni<sup>22</sup> (1957), believed that, the palatal rugae are unchanged throughout life, but found, this does not apply in every aspect. Fiene<sup>23</sup> (1958) discovered that the palatal rugae could be helpful in anthropological paternity investigations.

### Analysis of Rugae Pattern:

The utilization of digital photography, personal computers and specific software's to edit and use digital images allow a significant improvement. Other techniques like stereoscopy for obtaining a three-dimensional image of palatal rugae anatomy, stereo photogrammetry which allows for an accurate determination of the length and position of every palatal rugae can also be used.<sup>24</sup>


### Classification<sup>25</sup>:

1. By Gorla (1911) rugae pattern was divided into two types-

- Specifying the number of rugae
- Specifying the extent of rugal zone relative to the teeth
- Further distinguished rugae into 2 types-Simple or Primitive & More developed

2. By Trobo (1932) Palatal rugae were divided into two groups:

- **Simple rugae:** As Type A, B, C, D, E, F (Figure)



Type A                      Type B                      Type C



Type D                      Type E                      Type F

-**Compound rugae:** Rugae are reformed by the union of two or more simple rugae and were classified as "Type X" or Polymorphic type.

### Classification Rugae type

Classification	Rugae Type
Type A	Point
Type B	Line
Type C	Curve
Type D	Angle
Type E	Sinuous
Type F	Circle


3. According to Lysell (1955): Palatal rugae were classified depending on its length

- Primary: 5mm or more
- Secondary: 3-5mm
- Fragmentary: 2-3mm ( Rugae smaller than 2mm are disregarded )

4. By Kapali et al (1997): Based on shape of Palatal rugae

- Curved, Wavy, Straight, Circular

### 5. Modification of Kapali's: a) Curved; b) Wavy; c) Straight; d) Circular; e) Furcated



### 6. Carrea classification: based on form of the palatal rugae

Type I: Posterior-Anterior directed rugae

Type II: Rugae perpendicular to raphe

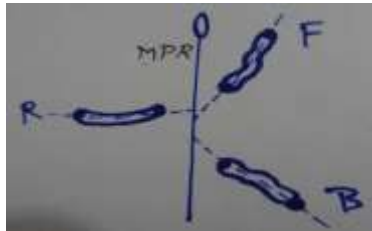
Type III: Anterior-Posterior directed rugae

Type IV: Rugae directed in several direction

### 7. Rugae unification pattern classification : a) Diverging; b) Converging



### 8. Classification based on orientation of rugae in relation to mid palatal raphe:



F- forward, R- right angle, B- backward, MPR-Mid palatal Raphe

### Advantages of palatoscopy:

1. Palatal rugae are used in human identification due to their singularity and unchangeable nature.
2. Low utilization costs.
3. Antemortem data such as records found in dental practice (dental casts, old prosthetic maxillary devices and intraoral photographs) to compare with post mortem data.
4. Rugoscopy is rather simple technique not requiring any complex instrumentation.

### Problems With Palatoscopy:

1. Palatoscopy might not be so useful in crime scene investigations in the linking of suspects to crime scenes.
2. Possibility of rugae pattern forgery. In a case report, Gitto et al described a method where palatal rugae were added to a complete denture in order to improve speech patterns in some patients. This process can lead to false identity.

### Discussion:-

Palatoscopy or palatal rugoscopy, is the study of palatal rugae in order to establish a person's identity.<sup>26</sup> It is stable and resists decomposition for up to seven days after death.<sup>26</sup> The use of palatal rugae in forensic identification is preferred because of their low utilization cost, simplicity and reliability and mostly used technique.

There are several ways to analyze palatal rugae such as intraoral inspection, oral photography and oral impressions. Calcorrugoscopy, stereoscopy method gives three dimensional image of palatal rugae anatomy. In comparison of palatal rugae pattern among family members (Father, Mother, Child A and Child B) showed different individual

patterns. Although in one of the family few forms were similar but the rugae pattern was not identical which suggests that the role of heredity is uncertain in determining the orientation of rugae pattern<sup>27</sup>

On analyzing the post orthodontic casts, rugae patterns remained consistently stable and unaltered at the end of treatment which suggests that rugae pattern remain unchanged during an individual's lifetime and also following action of force. This is in consistent with the study conducted by Sabet and Abdel. The main structural element contains glycosaminoglycans which by its hydrophilic nature causes the tissues to swell and contributes to the maintenance of the shape of rugae through out life. Fibroblasts and collagen fibers beneath the thickened epithelium contribute to the stability of palatal rugae. In light of these results, we strongly suggest that palatal rugae pattern can be used in forensic science and also for antemortem and postmortem identification. Also a standard and uniform procedure needs to be put forth for the collection, recording and computerized analysis of the palatal rugae.<sup>27</sup>

### Conclusion:-

Identification of living or dead people is often a difficult, challenging and time-consuming process. Palatal rugae have been shown to be highly individualistic and consistent in shape throughout the life.<sup>14</sup> Human identification of unknown individual has always been of paramount importance to society. It is well established fact that the rugae pattern is as unique to a human as or her fingerprints. It is stable and resist decomposition for up to seven days after death. The use of palatal rugae in forensic identification is preferred because of their low utilization cost, simplicity and reliability. Thus, it is sufficiently characteristic to discriminate between individuals because no two palates are alike in their configuration. Based on this premise, palatal rugae can emerge as one of the tools for personal identification in forensic science. In view of these significant findings that palatal rugae possess unique characteristics as they are absolutely individual, stable, permanent and unique. Therefore could be used as a personal print for identification and deserves further investigation with larger samples.<sup>27</sup>

### References:-

1. Jeddy N, Ravi S, Radhika T. Current trends in forensic odontology. J Forensic Dent Sci 2017;9:115-9.
2. Auerkari E. Recent trends in dental forensics. Indones J Leg Forensic Sci 2008;1:5-12.
3. Mohammad N, Ahmad R, Kurniawan A, Mohd Yusof MYP. Applications of contemporary artificial intelligence technology in forensic odontology as primary forensic identifier: A scoping review. Front Artif Intell. 2022 Dec 6;5:1049584.
4. Kumar LB, Shivakumar S. Forensic odontology: Int J Forensic Odontol 2016;1:2-3.
5. Balachander N, Babu NA, Jimson S, Priyadharsini C, Masthan KM. Evolution of forensic odontology: An overview. J Pharm Bioallied Sci. 2015 Apr;7(Suppl 1):S176-80.
6. Keiser-Neilsen S. Bristol: John Wright and Sons; 1980. Person Identification by Teeth.
7. Swanson HA. Forensic dentistry. J Am Coll Dent 1967;34:174-80.
8. Keiser-Nielsen SA. Editorial, News Letter. Scand Soc For Odont 1967;1:4.
9. Sabarigirinathan, C & Vinayagavel, K & Meenakshi, A & Rajendran, Appadurai. (2015). Palatal Rugae in Forensic Odontology-A Review. 83-87.
10. Paliwal A., Wanjari S. and Parwani R., Palatal rugoscopy, Establishing identity, J Forensic Dent Sci., 2(1), 27-31 (2010)
11. Buchner A., The identification of human remains, Int Dent J, 35, 307- 11 (1985)
12. Carbajo C, Identificación de cadáveres y aspectos forenses de los desastres, publicaciones de la Unidad de Investigación en Emergencia y Desastres, 2015.
13. Gilbert J.A. Calabuig, Medicina Legal y Toxicología (5th ed.) 1997: 678
14. Mahajan, R, Dar, M, Risam, S "Palatoscopy/Rugoscopy: A Potential Tool in Human Identification". Journal of Evolution of Medical and Dental Sciences 2014; Vol. 3, Issue 40, 10076-10088.
15. J.D. Simmons, R.N. Moore and L.C. Erickson, A longitudinal study of anteroposterior growth changes in the palatine rugae, J. Dent. Res. 66(1987) (9), pp. 1512-1515.
16. Abdel-Aziz H.M. & Sabet N.E., Palatal rugae area: a landmark for pre-and post-orthodontically treated adult Egyptian patients, East Mediterr. Health J. 2001. (1/2), p. 60-66.
17. Lund O. Histologische Beiträge zur Anatomie des Munddachs und Parodontiums. Vrtlzshr F Zahn 1924; 40: 1-20.
18. Amasaki H, Ogawa M, Nagasao J, Mutoh K, Ichihara N, Asari M and Shiota K. Distributional changes of BrdU, PCNA, E2F1 and PAL31 molecules in developing murine palatal rugae. Ann. Anat. 2003; 185(6): 517-23.

19. Daokar S. Rugoscopy An Emerging Tool in Forensic Odontology. *Int J Forensic Odo.* 2022;7;1:30-37
20. Campos ML, *Rugoscopy* palatina, 2007.
21. Lysell, Plica palatinae transverse and papilla incisive in man. A morphological and genetic study, *Acta Odont. Scand.* 13(1955) (Suppl. 18), p. 5-137.
22. Sassouni V. Palato print, physioprint and roentgenographic cephalometry as new methods in human identification. *J Forensic Sciences* 1957; 2: 428-42.
23. Fiene M. Vergleichend-morphologische Studien über das Gaumenfaltenrelief von Zwillingen. *Fortschr Kieferorthop* 1958; 19: 229-36.
24. Kaushik, A (2021). Review on palatal rugae. ***Journal of Forensic Research*, 12:10,2021**
25. Krishnappa S, Srinath S, Bhardwaj P, CH Mallaya. Palatal Rugoscopy: Implementation in Forensic Odontology- A Review. *J Adv Med Dent Scie* 2013;1(2):53-59.
26. Abou El-Fotouh M. M. A and El-Sharkawy G. Z. H. "A study of palatal rugae pattern (rugoscopy) in a". *Official Journal of the Egyptian Dental Association.* 1998; **44(3)**: 3177.
27. Ap, Indira & Gupta, Manish & David, Maria & Lecturer, Senior. (2010). *Rugoscopy for Establishing Individuality.* 3.